

TABLE 1. Patients Having Internal Jugular Cannulation

	Single Pass of Needle	Multiple Passes of Needle	Total No. of Patients	Single Pass Success Rate
With Doppler	17	5	22	77.3% (54.6–92.2)*
Without Doppler	6	15	21	28.6% (11.3–52.2)

$\chi^2 = 10.24$ ;  $P = 0.0014$ .  $\chi^2$  (corrected) = 8.38;  $P < 0.005$ .

\* 95% confidence intervals.

exploration. The size of our study limits definitive conclusions about complication rates; however, we believe the Doppler can be a useful aid for internal jugular cannulation.

## REFERENCES

1. English ICW, Frew RM, Pigott JF, Zaki M: Percutaneous catheterization of the internal jugular vein. *Anaesthesia* 24:521–531, 1969
2. Rao TLK, Wong AY, Salem MR: A new approach to percutaneous catheterization of the internal jugular vein. *ANESTHESIOLOGY* 46:362–364, 1977
3. Oda M, Fukushima Y, Hirota T, Tanaka A, Aono M, Sato T:

The paracarotid approach for internal jugular catheterization. *Anaesthesia* 36:896–900, 1981

4. McEnany MT, Austen WG: Life-threatening hemorrhage from inadvertent cervical arteriotomy. *Ann Thorac Surg* 24:233–236, 1977
5. Wisheart JD, Hassan MA, Jackson JW: A complication of percutaneous cannulation of the internal jugular vein. *Thorax* 27:496–499, 1972
6. Frascquet FJ, Belda FJ: Permanent paralysis of C-5 after cannulation of the internal jugular vein. *ANESTHESIOLOGY* 54:528, 1981
7. Davis P, Watson D: Horner's syndrome and vocal cord paralysis as a complication of percutaneous internal jugular vein catheterization in adults. *Anaesthesia* 37:587–588, 1982
8. Ullman JI, Stoelting RK: Internal jugular vein location with the ultrasound doppler flow detector. *Anesth Analg* 57:118, 1978
9. Seldinger SI: Catheter replacement of the needle in percutaneous arteriography. *Acta Radiol* 39:368–376, 1953
10. Daniel WW: *Biostatistics: A foundation for analysis in the health sciences*, New York, John Wiley and Sons, 1978, pp 358–359
11. Diem K, Lentner C: *Scientific tables*. Seventh edition. Switzerland, Ciba-Geigy Ltd., 1973, pp 85–103
12. Defalque RJ: Percutaneous catheterization of the internal jugular vein. *Anesth Analg* 53:116–121, 1974
13. Goldfarb G, Lebrec D: Percutaneous cannulation of the internal jugular vein in patients with coagulopathies: An experience based on 1,000 attempts. *ANESTHESIOLOGY* 56:321–323, 1982
14. Bazaral M, Harlan S: Ultrasonographic anatomy of the internal jugular vein relevant to percutaneous cannulation. *Crit Care Med* 9:307–310, 1981

Anesthesiology  
60:482–484, 1984

## Hemodynamic and Two-dimensional Transesophageal Echocardiographic Analysis of an Anaphylactic Reaction in a Human

PAUL N. BEAUPRE, M.D.,\* MICHAEL F. ROIZEN, M.D.,† MICHAEL K. CAHALAN, M.D.,‡  
RICKI A. ALPERT, M.D.,\* LYDIA CASSORLA, M.D.,§ NELSON B. SCHILLER, M.D.¶

While anesthetized for aorto-bifemoral reconstruction, a 60-year-old man had an anaphylactic reaction to the antibiotic sodium cefazolin (Ancef®; Smith Kline, Philadelphia, Pennsylvania). During the reaction, hemody-

namic and two-dimensional transesophageal echocardiographic (2-D TEE) measurements indicated that profound hypotension occurred because of decreases in left ventricular preload and afterload and not because of myocardial dysfunction.

## REPORT OF A CASE

A 60-year-old, 82.5-kg man was admitted to our hospital because of the acute onset of numbness and weakness in his legs. Absence of pulses in the legs led to the diagnosis of aortic occlusion. An aortogram revealed occlusion of the left renal artery and both femoral arteries by a thrombus, and blood flow to the legs and right kidney was minimal. An echocardiogram revealed a large pedunculated thrombus in the left ventricle and pronounced abnormalities in anteroseptal and lateral wall motion. A cardiac surgeon advised against immediate removal of the left ventricular mass, but because of threatened loss of the lower extremities and impending renal failure, an aorto-bifemoral bypass graft, right renal revascularization, and left nephrectomy were planned.

The patient's medical history included many years of poorly controlled hypertension and severe coronary artery disease. Four years

\* Research Fellow in Anesthesia.

† Associate Professor of Anesthesia, Medicine, and Pharmacology.

‡ Assistant Professor of Anesthesia.

§ Resident in Anesthesia.

¶ Associate Professor of Medicine and Radiology.

Received from the Departments of Anesthesia, Medicine, Pharmacology, and Cardiology, University of California, San Francisco, California. Accepted for publication September 21, 1983. Supported in part by National Institute on Aging Program Project 1 PO1 AG03104-01,02.

Address reprint requests to Dr. Roizen: Department of Anesthesia, University of California, Room S436, Third and Parnassus Avenue, San Francisco, California 94143.

Key words: Allergy. Heart: echocardiography. Measurement techniques: two-dimensional transesophageal echocardiography.

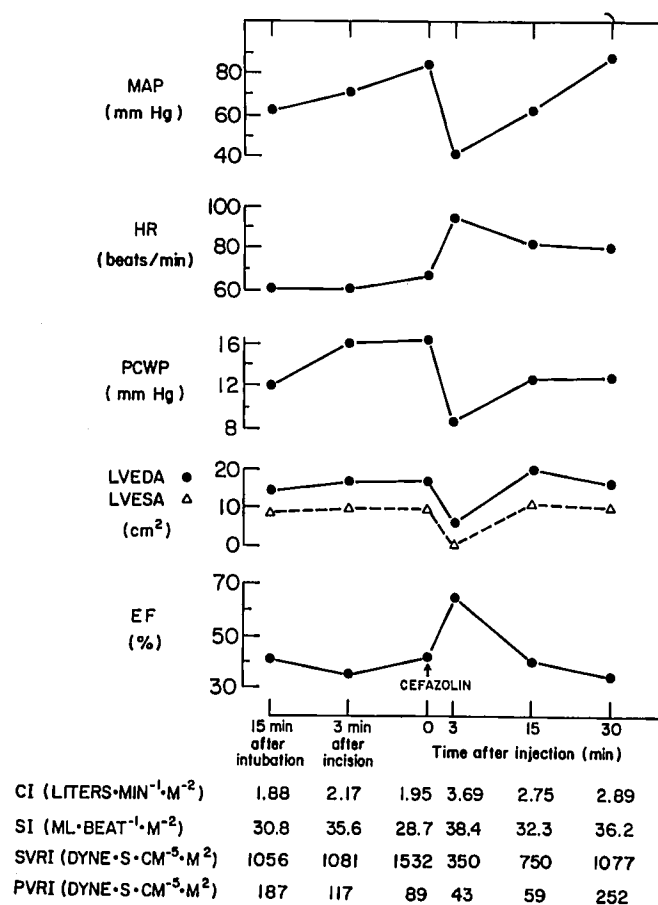


FIG. 1. Hemodynamic and echocardiographic changes before, during, and after an anaphylactic reaction to cefazolin. MAP = mean arterial blood pressure; HR = heart rate; PCWP = pulmonary capillary wedge pressure; LVEDA and LVESA = left ventricular end-diastolic and end-systolic cross-sectional areas; EF = ejection fraction ( $(LVEDA - LVESA)/LVEDA$ ); CI = cardiac index; SI = stroke index; SVRI = systemic vascular resistance index; and PVRI = pulmonary vascular resistance index.

before this admission, he required a four-vessel coronary artery bypass. Within a year, however, an anteroapical myocardial infarction occurred. Two years before admission, he had a second infarction (inferior wall of the left ventricle), this time complicated by congestive heart failure and residual exertional angina. Although 40 years before admission, facial and laryngeal edema had occurred after he had ingested aspirin, 10 years after that, penicillin was administered without incident. His current medications consisted of digoxin, furosemide, 1/2-inch 2% nitroglycerin ointment every 6 h, and sublingual nitroglycerin as needed.

The night before surgery, the patient consented to participate in a study comparing two primary anesthetic agents, sufentanil, a new synthetic narcotic, and isoflurane. Before induction of anesthesia, heart rate was 82 beats/min, and mean arterial pressure (MAP) was 100 mmHg. The patient received sufentanil (8 µg/kg) for induction of anesthesia, which was maintained with 70% nitrous oxygen and 30% oxygen. After endotracheal intubation, a 9-mm gastroscope having a 3.5-MHz echocardiographic transducer on its tip was introduced into the esophagus and positioned behind the heart to obtain a short-axis view of the left ventricle at the level of the tips of the papillary muscles.

For 20 min after skin incision, the patient's blood pressure did not change from preinduction values. However, within 3 min of receiving 300 mg of sodium cefazolin, heart rate increased from 67 to 96 beats/min, an intense red discoloration covered his entire body, and MAP decreased from 95 to 42 mmHg, despite rapid infusion of 60 ml of Ringer's lactate per minute for 15 min. Nitrous oxide was discontinued, and 100% oxygen was administered. Over the next 15 min, MAP gradually increased to 63 mmHg. Total fluid administered was 900 ml. Subsequently, the intraoperative course was uneventful.

Pressures in the radial artery, right atrium, and pulmonary artery were recorded continuously from strain-gauge transducers calibrated with mercury. Cardiac outputs were determined using a thermodilution technique (iced saline at 0–3°C) and were calculated using a cardiac output analyzer (Edwards 9520A). All measurements were done in triplicate. Cardiac index, stroke index, systemic vascular resistance index (SVRI), and pulmonary vascular resistance index (PVRI) were calculated. The V<sub>5</sub> ECG lead was displayed continuously on a hemodynamic monitor (Vitatek model 1211).

All echocardiographic images were recorded on 1/2-inch VHS tape from an ultrasonograph (Diasonics 3400R). Recordings, which were made at the times indicated in figure 1, were analyzed with a light-pen computer (Diasonics model V3000). For three consecutive beats, the surface of the endocardium was traced at end-diastole and end-systole. The computer calculated left ventricular end-diastolic and end-systolic areas (LVEDA and LVESA, respectively). Ejection fraction (EF) was calculated as a percentage as follows:

$$EF = (LVEDA - LVESA)/LVEDA \times 100$$

## RESULTS

Fifteen minutes after surgical incision (*i.e.*, immediately before administration of cefazolin), MAP was 85 mmHg, heart rate, 68 beats/min; pulmonary capillary wedge pressure (PCWP), 17 mmHg; cardiac index, 1.95  $l \cdot min^{-1} \cdot m^{-2}$ ; stroke index, 28.7  $ml \cdot beat^{-1} \cdot m^{-2}$ ; SVRI, 1,533  $dyn \cdot s \cdot cm^{-5} \cdot m^{-2}$ ; PVRI, 89  $dyn \cdot s \cdot cm^{-5} \cdot m^{-2}$ ; LVEDA, 18  $cm^2$ ; LVESA, 10.8  $cm^2$ ; and ejection fraction, 40.2%. Three minutes after administration of cefazolin, heart rate increased to 96 beats/min and was accompanied by dramatic decreases in MAP (51%), PCWP (47%), SVRI (77%), PVRI (52%), LVEDA (60%), and LVESA (77%). At the same time, cardiac and stroke indexes increased 89% and 34%, respectively.

At 15 min after injection of cefazolin, MAP had returned to 63 mmHg; and SVRI, PVRI, and PCWP were returning toward preantibiotic levels. Left ventricular end-diastolic area, LVESA, cardiac index, and heart rate remained 13% higher than they had been before cefazolin (fig. 1). No new abnormalities in left ventricular wall motion were noted during or after the anaphylactic reaction or recovery period. The V<sub>5</sub> ECG lead revealed no evidence of ischemia during the anaphylactic reaction or recovery period.

## DISCUSSION

This case report demonstrates several aspects of an "immediate hypersensitivity" reaction (type 1), which is produced by the IgE-mediated release of pharmacolog-

ically active substances. Anaphylactic reactions can occur when an antigen interacts with immunoglobulin E (IgE) to cause degranulation of tissue mast cells and basophils, resulting in the liberation of histamine, prostaglandins, kinins, and slow-reacting substance of anaphylaxis (SRS-A) into the circulation. Histamine and kinins have profound effects on the circulation,<sup>2</sup> and histamine and SRS-A directly affect the myocardium.<sup>3</sup> Because a component of SRS-A, leukotriene D<sub>4</sub>, is a potent coronary vasoconstrictor, the hypotension of anaphylaxis may be due, in part, to myocardial ischemia.<sup>4</sup> In animals, leukotriene D<sub>4</sub> has profound systemic effects similar to norepinephrine, resulting in increased SVR and MAP.<sup>5</sup> These increases could cause further deterioration in myocardial function. However, we found no evidence of myocardial ischemia. The pronounced hypotension that occurred during this reaction appeared to have been caused by alterations in the loading conditions of the left ventricle and not by a deterioration in myocardial performance. The most pronounced hemodynamic effects concerned venous and arterial vasomotor tone. Values for PCWP, PVRI, SVRI, LVEDA, and MAP decreased at least 50% within 3 min of cefazolin administration. These changes probably are due to the early histamine release documented in humans,<sup>6</sup> because histamine is a potent vasodilator<sup>7</sup> and has direct antidromic, inotropic, and chronotropic action when administered directly into heart muscle.<sup>8</sup>

In this patient, who had preexisting left ventricular dysfunction and severe coronary artery disease, hypotension could have been expected to lead to decreased left ventricular performance. By the same reasoning, if leukotriene D<sub>4</sub> were a major influence in this setting, one would expect evidence of myocardial ischemia, left ventricular failure, or systemic pressor effects.<sup>5</sup> However, no evidence of left ventricular dysfunction occurred during this anaphylactic reaction. Both PCWP and LVEDA decreased, while stroke index, cardiac index, and ejection fraction increased. Furthermore, no changes indicating ischemia were seen on the V<sub>5</sub> ECG monitor, and no new abnormalities in wall motion were observed on the two-dimensional transeosophageal echocardiogram.

During an anaphylactic reaction, the temptation to administer vasopressors is strong. However, our patient responded to fluid therapy and 100% oxygen, as did a previous patient having a well-documented anaphylactic reaction.<sup>6</sup> Data for this latter patient showed that within 20 min of fluid resuscitation, MAP and heart rate had

returned to prereaction levels. We hypothesize that, in the controlled setting of the operating room, treatment of anaphylaxis should focus on ensuring adequate oxygenation and replacing fluids. In many patients it is also appropriate to use epinephrine early in the therapy for anaphylaxis to prevent further degranulation of mast cells.<sup>9</sup> Using a "pure" vasoconstrictor (*i.e.*, norepinephrine) or myocardial stimulant (*i.e.*, isoproterenol or dopamine) in these patients theoretically might increase myocardial work, induce myocardial ischemia, and precipitate dysrhythmias. We were able to use volume alone in resuscitating our patient, who responded well to such treatment. Thus, the mild episode of anaphylaxis, its prompt recognition and discontinuation of the offending agent, and our fortuitous monitors allowed us to use only volume as a treatment. In other anaphylactic events, volume alone might not suffice and prompt treatment with epinephrine would be necessary.<sup>1,2,9</sup>

In conclusion, our data support the contention that the hemodynamic sequelae of this type of anaphylactic reaction result from profound peripheral vasodilation. When preload and afterload to the left ventricle are reduced greatly during an anaphylactic reaction, myocardial pump function appears to be enhanced.

## REFERENCES

1. Lachmann PJ, Peters DK, eds: Clinical Aspects of Immunology. Fourth edition. Oxford, Blackwell Scientific Publications, 1975, pp 579-585
2. Parker CW: Drug therapy: Drug allergy. *N Engl J Med* 292:511-514, 732-736, 957-960, 1975
3. Bristow MR, Ginsburg R, Harrison DC: Histamine and the human heart: The other receptor system. *Am J Cardiol* 49:249-251, 1982
4. Michelassi F, Landa L, Hill RD, Lowenstein E, Watkins WD, Petkau AJ, Zapol WM: Leukotriene D<sub>4</sub>: A potent coronary artery vasoconstrictor associated with impaired ventricular contraction. *Science* 217:841-843, 1982
5. Pfeffer MA, Pfeffer JM, Lewis RA, Braunwald E, Corey E, Austen KF: Systemic hemodynamic effects of leukotrienes C<sub>4</sub> and D<sub>4</sub> in the rat. *Am J Physiol* 244:628-633, 1983.
6. Moss J, Fahmy NR, Sunder N, Beaven MA: Hormonal and hemodynamic profile of an anaphylactic reaction in man. *Circulation* 63:210-213, 1981
7. Beaven MA: Histamine. *N Engl J Med* 94:30-36, 320-325, 1972
8. Levi R, Allan G, Zavecz JH: Cardiac histamine receptors. *Fed Proc* 35:1942-1947, 1976
9. Stoelting RK: Allergic reactions during anesthesia. *Anesth Analg* 62:341-356, 1983