

total amount of potassium release would not need to be very large. The elevated postoperative bilirubin and hemoglobin levels indicate that appreciable hemolysis occurred and probably contributed to the clinical problems described in this case. A fourth possibility is air embolism, which can present as a sudden cardiac arrest. The patient was in the right lateral position with extreme flexion and the kidney rest was at the upper limit of its travel. Thus, there was at least a 10-cm gradient from the surgical site to the right atrium. Sudden opening of a large vessel conceivably could have allowed sufficient air to be entrained to cause cardiac arrest. However, the gradient in this case seemed small, and no murmurs were heard with the esophageal stethoscope. The appearance of blood in previously clear irrigation fluid suggests that there was the sudden opening of a vessel, presumably secondary to manipulation of the probe.

Alken<sup>1</sup> reported on a series of 17 patients in whom he had performed percutaneous stone removal using the ultrasonic lithotrite. Complications included three residual stones, retroperitoneal extravasation of fluid in one case, bleeding successfully managed conservatively in another case, and ureteral stenosis requiring operation in one case. Segura *et al.*<sup>2</sup> described 15 patients managed with this technique and reported minimal postoperative mor-

bidity, with no serious sequelae. Anesthetic techniques in these reported series involved local, epidural, and general anesthesia. The operative technique has become a standard one and is widely believed to be associated with no serious morbidity.

Regardless of the exact cause of our patient's cardiac arrest, percutaneous ultrasonic nephrostolithotomy is clearly not without major risks including possible water intoxication, venous air embolism, and, as in our case, cardiac arrest. In this case, the sudden appearance of blood in previously clear irrigation fluid was the earliest sign of impending problems but was followed within seconds by a complete cardiac arrest. Since we believe the electrolyte disturbances from free water intake and hemolysis to be the major factors, we have modified our protocol and now use normal saline irrigation fluid for these procedures.

## REFERENCES

1. Alken P: Percutaneous ultrasonic destruction of renal calculi. *Urol Clin North Am* 9:145-151, 1982
2. Segura JW, Patterson DE, LeRoy AJ, McGough PF, Barrett DM: Percutaneous removal of kidney stones. *Mayo Clin Proc* 57:615-619, 1982

Anesthesiology  
60:246-248, 1984

## Entrapment of a Mitral Valve Prosthesis with a Left Atrial Catheter

ERIC J. PORTER, M.D.,\* EDWARD A. NORFLEET, M.D.,† FRANKLIN D. BOONE, C.C.P.,‡  
JAMES BATTAGLINI, M.D.,§ PETER J. K. STAREK, M.D.¶

The use of invasive monitoring devices have greatly enhanced our abilities to care for patients undergoing cardiac surgery. In particular, the use of a left atrial catheter provides an accurate method of quantitating filling pressures and appropriately adjusting left ventricular preload. We report an unusual situation in which a left

atrial catheter resulted in temporary, life-threatening malfunction of a prosthetic valve disc.

## REPORT OF A CASE

A 39-year-old woman had a 4-year history of progressive dyspnea. There was no history of rheumatic heart disease or primary pulmonary disease. On physical examination, she had a murmur and an audible click consistent with a stenotic mitral valve.

During cardiac catheterization, her cardiac index was 2.29 l·m<sup>2</sup>. The pulmonary capillary wedge pressure was 19 mmHg and increased to 34 mmHg following exercise. The mitral valve area was 0.9 cm<sup>2</sup>. Left ventricular function was normal with an ejection fraction of 0.6. The ECG was normal, and the chest roentgenogram showed left atrial prominence with some increase in pulmonary vascularity. Because of a diagnosis of mitral stenosis, a mitral valve replacement was scheduled.

Prior to induction of anesthesia, direct arterial pressure monitoring was established, and a flow-directed pulmonary artery catheter was inserted via the right internal jugular vein. Anesthesia was induced by iv narcotics. Vital signs remained very stable following induction of anesthesia and during cardiopulmonary bypass. The duration of cardiopulmonary bypass was approximately 2 h. The stenotic mitral

\* Anesthesiology Resident, Department of Anesthesiology.

† Associate Professor of Anesthesiology, Department of Anesthesiology.

‡ Certified Cardiovascular Perfusionist, Department of Surgery.

§ Cardiothoracic Resident, Department of Surgery.

¶ Professor of Cardiothoracic Surgery, Department of Surgery.

Received from the Departments of Anesthesiology and Surgery, University of North Carolina School of Medicine, Chapel Hill, North Carolina. Accepted for publication August 11, 1983.

Address reprint requests to Dr. Norfleet: Department of Anesthesiology, North Carolina Memorial Hospital, Chapel Hill, North Carolina 27514.

Key words: Surgery: cardiovascular. Heart: vascular pressures. Monitoring: left atrial pressure.

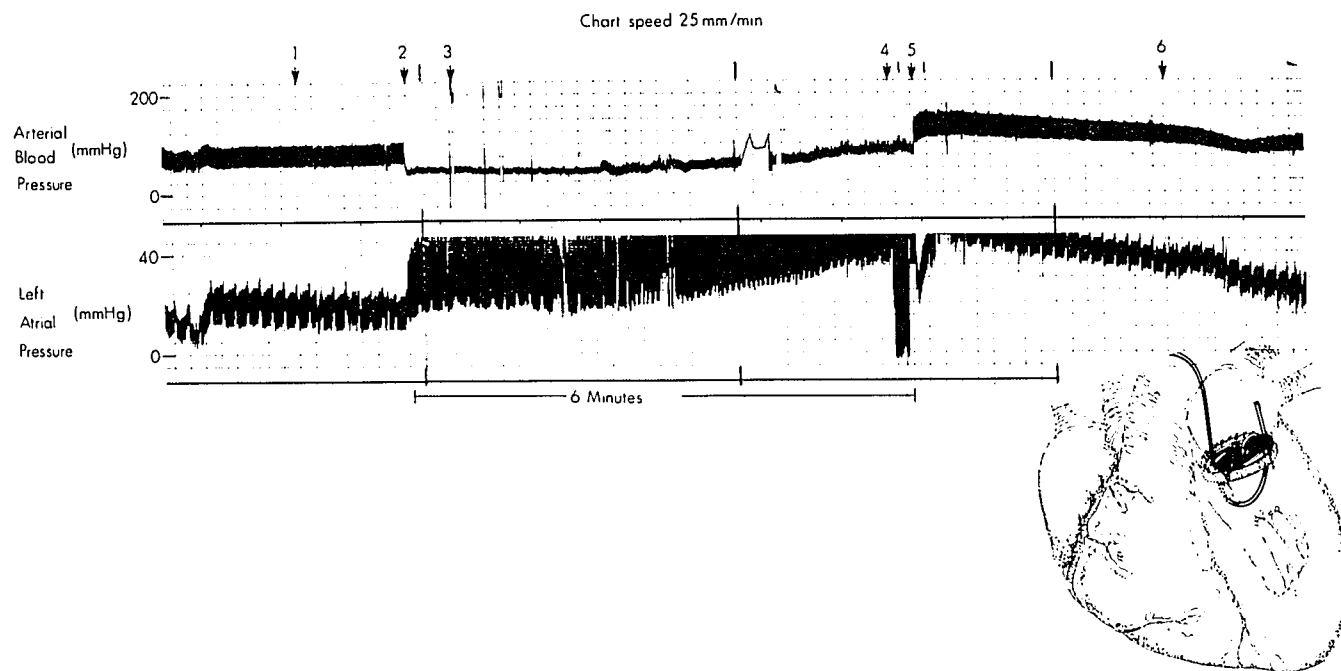


FIG. 1. Sequence of cardiovascular events and artistic impression of proposed mechanism for valvular disc malfunction. 1) stable tracings of arterial and left atrial pressures; 2) point of valvular malfunction; note sudden changes in left atrial and arterial pressures; 3) arterial pressure artifacts from flushing of line; 4) retraction of left atrial catheter into left ventricle; 5) further retraction of left atrial catheter; note immediate return of arterial pressure; and 6) recovery period with normalization of left atrial pressure.

valve was replaced with a Hall prosthetic valve and a left atrial catheter inserted through a right pulmonary vein. Cardiopulmonary bypass was terminated without difficulty. Approximately 45 min later, the systemic arterial blood pressure dropped acutely from 100/58 to 50/35 mmHg and the left atrial pressure increased abruptly from a mean of 22 to 40 mmHg. Calcium chloride and epinephrine was administered rapidly iv with little change in arterial pressure. The left ventricle appeared empty but continued to contract vigorously. The diagnosis of acute valvular dysfunction was made, but the cause remained obscure. The heart was massaged with no improvement. Fortunately, the left atrial catheter was repositioned to assure that pressure measurements were not artifactual. As the catheter was retracted, an unexpected resistance was noted and suddenly a dramatic change in waveform appeared. A left ventricular pressure tracing was noted. Upon further retraction of the catheter, the arterial pressure returned with a progressive return of a normal left atrial pressure. The entire sequence of events lasted approximately 6 min (fig. 1). The remainder of the intraoperative course was uneventful, and the patient was transported to the cardiac intensive care unit in stable condition.

## DISCUSSION

Malfunction of prosthetic valves can occur from a variety of causes. The anatomic and geometric arrangements of prosthetic valves within the cardiac endoskeleton and adjacent myocardium occasionally may result in the inability of the valve to open or close properly. Thrombi, vegetations, and other pathologic processes also have produced stenosis or insufficiency of prosthetic valves.<sup>1</sup>

Insufficiency of valves may result from perivalvular defects or as a result of "unraveling" or dislodgment of suture lines. Starek<sup>2</sup> has demonstrated immobilization of a valve disc by a suture end wedged between the disc and valve ring.

In our patient, the sudden onset of hemodynamic changes in the setting of a newly inserted prosthetic valve strongly suggested a mechanical problem. We immediately suspected malfunction of the valve, however, the specific cause was not apparent until actual manipulation of the left atrial catheter was performed. After analysis of the chart recording, we suspect that actual prolapse of the catheter caused the complication rather than simple advancement of the tip across the valve. This is evidenced by the sequence of pressure events that occurred during withdrawal of the catheter (fig. 1). The waveform changed from atrial to ventricular and then returned to atrial with simultaneous improvement in arterial blood pressure.

From this experience, we feel that awareness of this potential complication is critical for both prevention and management. Surprisingly, jamming of valve disc with left atrial catheters may not be uncommon and previously has been described by others.<sup>3</sup> Whenever use of a left atrial catheter is advocated in patients with disc type mitral valves, the potential for interfering with the valve mechanism must be recognized. Judgement of the

length of catheter inserted into the left atrium can be facilitated by use of a catheter with graduated markings. Secure fixation of this catheter to the atrial wall or pericardium can further decrease the chance of catheter migration or further advancement into the atrium and possible interference with the valve mechanism.

In summary, a very serious life-threatening complication as a result of entanglement of a left atrial catheter with a prosthetic valve is presented. Fortunately, the period of hypotension and low cardiac output was brief,

and the patient was discharged in excellent condition after an uncomplicated postoperative course.

#### REFERENCES

1. Sabiston DC Jr, Spencer FC: Surgery of the Chest. Philadelphia, WB Saunders, 1976, p 1202
2. Starek PJK: Immobilization of disc heart valves by unraveled sutures. *Ann Thorac Surg* 31:66-69, 1981
3. Browdie DA, Agnew RF, Hamilton CS Jr: Poppet jamming during mitral valve replacement. Letter to the Editor. *Ann Thorac Surg* 29:591, 1978

Anesthesiology  
60:248-252, 1984

### Detection of Brachial Plexus Dysfunction by Somatosensory Evoked Potential Monitoring—A Report of Two Cases

MICHAEL E. MAHLA, M.D., CPT, MC,\* DONLIN M. LONG, M.D.,† JOY MCKENNETT, C.R.N.A.,  
CAROL GREEN, RCPT, ROBERT W. MCPHERSON, M.D.,‡

Brachial plexus injury from surgical positioning has occurred during numerous operative procedures.<sup>1-4</sup> A variation of the lateral decubitus position, commonly called the park bench or ¾-prone position, sometimes is used for posterior fossa surgery because of a lower incidence of hemodynamic instability and air emboli as compared with the sitting position.<sup>5</sup> The potential for neurologic injury due to positioning should be similar to the lateral position.

Two patients are presented in whom somatosensory evoked potentials (SEP) were monitored for posterior fossa surgery performed in the park bench position. These patients are presented to demonstrate the utility of SEP monitoring in possibly preventing neurologic injury associated with the park bench position and to call attention to the necessity of internal control methods required to distinguish peripheral from central neurologic dysfunction.

#### REPORT OF TWO CASES

In both the cases described below, SEP monitoring (median nerve) was established prior to induction of anesthesia after insertion of catheters for hemodynamic monitoring. Gold-plated silver-cup electrodes were placed 2 cm posterior to C3 and C4 (utilizing the international 10-20 system of electrode placement) and designated C3', C4'. An electrode was placed over the second cervical vertebrae (SC2). A disposable electrode was placed at FP<sub>2</sub> for reference. All electrode impedances were maintained less than 2 kohms. Sterile needle stimulating electrodes were placed subcutaneously in the area of the median nerve at each wrist after determination of optimal location with a transcutaneous stimulator. A Nicolet Med-80 physiologic monitor was used to develop the SEPs. The channels monitored were FP<sub>2</sub>-C3', FP<sub>2</sub>-C4', second cervical vertebrae (SC2-FP<sub>2</sub>). A stimulus rate of 5.9/s was used. One hundred twenty-eight responses were averaged, and the time observed was 80 ms after the stimulus. Filter settings were 30-1500 Hz, and a full-scale sensitivity of 50  $\mu$ V was used. The sampling time was 0.312 ms per point. Prior to induction of anesthesia, a stimulus intensity slightly above motor threshold was used. After induction of anesthesia, the stimulus intensity was increased to 19.9 milliamperes.

*Patient 1.* A 54-year-old man underwent surgery for removal of residual right acoustic neuroma. He had undergone partial resection of the tumor approximately 6 weeks earlier in the sitting position. The initial surgery was uneventful, and the patient was without neurologic deficit except for mild right CN VII, CN VIII, and CN V deficits. Because of deafness and inability to obtain brain stem auditory response (BAER) on the operative side during previous surgery, brain stem function was monitored during surgery utilizing SEP (median nerve). A normal SEP was evident in response to stimulation of the right median nerve (C3'-FP<sub>2</sub>). The response to stimulation of the left median nerve (C4'-FP<sub>2</sub>) was smaller than the contralateral side (fig. 1A).

Anesthesia was induced with fentanyl 25  $\mu$ g/kg and thiopental 100 mg, iv. Pancuronium 0.1 mg/kg, iv was given for muscle relaxation. The trachea was intubated without difficulty, and controlled ventilation was instituted. The PaCO<sub>2</sub> was maintained at approximately 30 mmHg. SEP responses to median nerve stimulation after induction of anesthesia were fairly symmetrical in amplitude and had normal latencies (fig.

\* Fellow in Neuroanesthesia, Johns Hopkins Medical Institution. Present Position: Staff Anesthesiologist, Walter Reed Army Medical Center, Washington, D. C.

† Professor of Neurosurgery and Chairman of the Department of Neurosurgery.

‡ Chief, Division of Neuroanesthesia, Assistant Professor, Department of Anesthesiology and Critical Care Medicine.

Received from the Department of Anesthesiology and Critical Care Medicine, Johns Hopkins Medical Institutions, Baltimore, Maryland. Accepted for publication August 12, 1983.

Address reprint requests to Dr. McPherson: Meyer 8-138, Johns Hopkins Hospital, Baltimore, MD 21205.

Key words: Position: nerve damage, brachial plexus damage. Monitoring: somatosensory evoked potentials.