

Anesthesiology  
60:236-238, 1984

## Bilateral Compartment Syndrome Following Prolonged Surgery in the Lithotomy Position

J. C. LYDON, M.D.\* AND FRED J. SPIELMAN, M.D.†

The success of many surgical procedures depends on satisfactory exposure of the operative site, which often is achieved by placing patients in physiologically abnormal positions.<sup>1,2</sup> With perceptive powers of the patient no longer intact, postural insults may occur that normally would not be tolerated in the awake state. We present a patient who developed bilateral anterior compartment syndrome following prolonged surgery in the lithotomy position.

### REPORT OF A CASE

A 44-year-old 60-kg woman was scheduled for resection of a recurrent mesenchymal cell pelvic tumor. Her medical history was remarkable for two previous resections without complications. Review of systems was noncontributory. There was no history of venoocclusive disease of the lower extremities. All laboratory data were within normal limits.

One hour prior to surgery, 15 mg diazepam was given orally. Anesthesia was induced with thiopental iv, and endotracheal intubation was facilitated by administration of pancuronium iv. Anesthesia was maintained with isoflurane (0.5–1.0%) and 60% nitrous oxide. Shortly after induction of anesthesia, the patient was placed in the lithotomy position via adequately padded Bierhoff leg holders (fig. 1).<sup>3</sup> The knees and thighs were flexed approximately 30 degrees from the neutral position. The legs were held in position by gravity and boot straps fastened lightly around each ankle. The surgical approach was strictly abdominal. The surgeons were not noted to rest their weight on the thighs during the procedure. She remained in the lithotomy position for the duration of the 9-h procedure. The surgery and anesthetic were uncomplicated by hypotension or surgical trauma to the vascular supply of the lower extremities. The patient was taken to the recovery room in good condition. Two hours following completion of surgery, the patient began to complain of severe bilateral leg pain. On physical examination, both lower legs were markedly edematous and painful to palpation. Distal extremity pulses were detectable only by examination with a Doppler monitor. The diagnosis of bilateral anterior compartment syndrome was made, and emergency fasciotomies were scheduled. Induction of anesthesia was performed again with thiopental iv and intubation of the trachea was facilitated on the iv administration of succinylcholine. Anesthesia was maintained with isoflurane. Incision of the fascia overlying the anterior compartment led to immediate extrusion of massively swollen, edematous, but non-

gangrenous muscles. The patient tolerated surgery well and was taken to the intensive care unit for postoperative care.

On the second postoperative day, laboratory studies revealed a serum creatinine phosphokinase (CPK) value of 16,650 units with a 96% MM fraction. Serum blood urea nitrogen (BUN) and creatinine were 14 mg/dl and 2.2 mg/dl, respectively. Urinary sediment contained tubular cell casts. Renal function deteriorated progressively and on the 20th postoperative day, the BUN and creatinine values were 116 mg/dl and 7.8 mg/dl, respectively. Hemodialysis was instituted because of clinical and radiographic evidence of excessive intravascular volume and was continued for 10 days.

On the 43rd postoperative day, skin grafts were applied to the fasciotomy sites. Renal function has since returned to normal. She is presently left with weakness of her distal lower extremity musculature bilaterally.

### DISCUSSION

Compartment syndrome following surgery in both lithotomy and other positions has been reported previously. In one case, the syndrome developed after 6½ h in the lithotomy position for a urologic procedure.<sup>4</sup> The syndrome also occurred following a 3-h hemilaminectomy in the knee–chest position.<sup>5</sup> The patient subsequently died from complications of acute renal failure. The development of the syndrome is associated with prolonged limb compression, either mechanical, as it occurs with lithotomy devices, or compression from the patient's weight, as occurs during surgery performed in the knee–chest position. Parkes<sup>6</sup> described the development of the syndrome following prolonged compression of the hands between the buttocks and operating table. This resulted in ischemic contractures of the intrinsic muscles of the hand. In the non-operating room setting, compartment syndrome has been described in instances of drug overdose where persons have remained in one position for several hours, with force supplied by the weight of their body on an extremity.<sup>7</sup>

The pathogenesis of the compartment syndrome involves direct local muscle pressure as the initiating event.<sup>8–10</sup> Subsequent necrosis of muscle and loss of capillary wall integrity in the presence of an intact vascular supply will lead to transudation, exudation, and the development of massive edema within the compartment. Edema within a closed compartment will increase the pressure within that compartment, eventually compromising the vascular supply. Such compromise will lead to further ischemia and edema formation, and a vicious

\* Resident.

† Assistant Professor.

Received from the Department of Anesthesiology, University of North Carolina School of Medicine, Chapel Hill, North Carolina 27514. Accepted for publication August 1, 1983.

Please address correspondence to Dr. Spielman.

Key words: Complications: compartment syndrome. Position: lithotomy, nerve damage.

cycle will be established. Fasciotomy is the only reliable method to terminate the ischemia–edema cycle.<sup>10</sup>

Complications of the compartment syndrome include permanent or transient neuromuscular deficits and rhabdomyolysis with or without renal failure. Our patient's renal failure most assuredly can be accounted for by the effects of myoglobinuria. Myoglobin dissociates into ferriheme and globin in an acid medium. The ferriheme component is felt to exert a direct toxic effect on the renal tubular epithelium. This effect is accentuated by hypovolemia and acidic urine, two conditions common to rhabdomyolysis.<sup>11,12</sup> Diagnostic features of rhabdomyolysis induced renal failure include a history of muscle pain and tenderness, dark urine that is orthotoluidine positive, markedly increased CPK values, and rapidly rising serum creatinine levels.<sup>12</sup> Our patient demonstrated several of these features.

In addition to the compartment syndrome, specific nerve damage may complicate malpositioning of patients in the Bierhoff leg holder. When a patient is placed in the holder without adequate padding, excessive pressure on the medial aspect of the calf or on the medial tibial condyle may result in saphenous nerve damage. This would be manifested postoperatively by paresthesias along the medial–anteromedial aspects of the lower leg.<sup>13</sup> The tibial nerve may be injured during prolonged compression of the popliteal space and would be manifested by foot weakness and paresthesias of the back of the calf.<sup>14</sup> Finally, the obturator nerve, as it courses through the obturator foramen, may be compressed by excessive flexion of the thigh at the hip. This is especially likely to occur in obese patients and may result in weakness or paralysis of the adductors of the thigh.<sup>3</sup>

We realize that the maximum safe time limit for patients placed in the lithotomy position is unknown. The literature reports the development of the compartment syndrome following 6½ h in the lithotomy position, as previously stated.<sup>4</sup> It seems prudent, then, to limit the time spent in the lithotomy position to less than 6½ h. The compartment syndrome can develop in the absence of any obvious clinical findings. This fact should not preclude performance of frequent examinations of the lower extremities for distal pulses, edema, and color changes. If there is a question of inadequate circulation, the legs should be returned to the horizontal position, remembering that lowering of the legs of an anesthetized patient may be accompanied by hypotension. The degree of hypotension will be directly proportional to the amount of impairment of vasoautoregulation and rapidity of the position change.<sup>15</sup>

The surgical team must assume the responsibility of protecting patients from injury caused by positions of

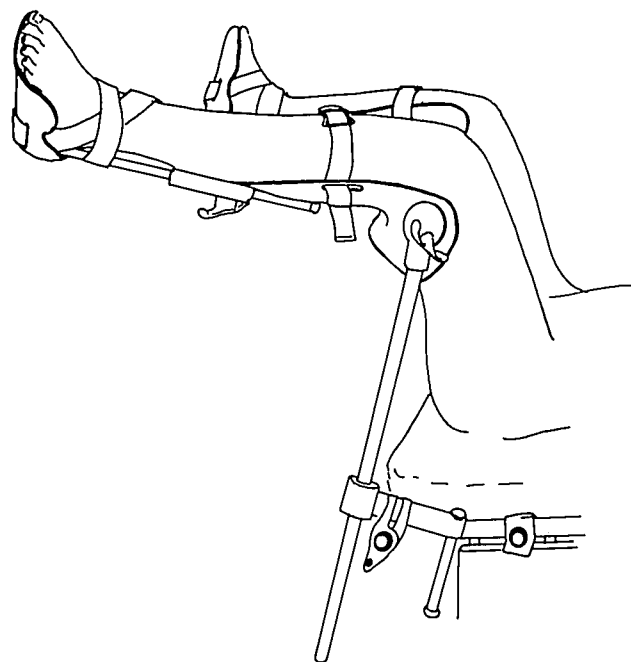


FIG. 1. Bierhoff leg holders with patient placed in the proper position: Thighs are minimally flexed towards the abdomen, stirrup rotated cephalad. Symmetric height, rotation, and abduction of leg. Protective wrappings are removed for clarity. (Modified from Goldstein PJ: The lithotomy position, *Positioning in Anesthesia and Surgery*. Edited by Martin JT. Philadelphia, WB Saunders, 1978, p 147, with permission of the publisher.)

extreme stress, pressure, or forces acting on neurovascular structures.<sup>16</sup> Preventing these complications through awareness and foresight is obviously preferable to therapy after the injury occurs.

The authors thank Marie Gregoris for her excellent secretarial assistance and Dr. David H. Sprague for his editorial help with the preparation of the manuscript.

## REFERENCES

1. Britt BA, Joy N, Mackay MB: Positioning Trauma, Complications in Anesthesiology. Edited by Orkin FK, Cooperman LH. Philadelphia, JB Lippincott, 1983, pp 647–670
2. Lincoln JR, Sawyer HP Jr: Complications related to body positions during surgical procedures. *ANESTHESIOLOGY* 22:800–809, 1961
3. Goldstein PJ: The lithotomy position, *Positioning in Anesthesia and Surgery*. Edited by Martin JT. Philadelphia, WB Saunders, 1978, pp 142–161
4. Leff RG, Shapiro SR: Lower extremity complication of the lithotomy position: Prevention and management. *J Urol* 122:138–139, 1979
5. Gordon BS, Newman W: Lower nephron syndrome following prolonged knee–chest position. *J Bone Joint Surg* 35-A:764–767, 1953

6. Parkes AR: Traumatic ischaemia of peripheral nerves with some observations on Volkmann's ischemic contracture. *Br J Surg* 32:402-409, 1944
7. Schreiber SN, Leibowitz MR, Bernstein LH: Limb compression and renal impairment (crush syndrome) following narcotic and sedative overdose. *J Bone Joint Surg* 54-A:1683-1692, 1972
8. Matsen FA III. Compartmental syndrome. An unified concept. *Clin Orthop Rel Res* 113:8-14, 1975
9. Rorabeck CH, MacNab I. The pathophysiology of the anterior tibial compartment syndrome. *Clin Orthop Rel Res* 113:52-57, 1975
10. Mubarak S, Owen CA: Compartmental syndrome and its relation to the crush syndrome: a spectrum of diseases. A review of 11 cases of prolonged limb compression. *Clin Orthop Rel Res* 113:81-89, 1975
11. Oken DE: Modern concepts of the role of nephrotoxic agents in the pathogenesis of acute renal failure. *Prog Biochem Pharmacol* 7:219-247, 1972
12. Schulze VE Jr: Rhabdomyolysis as a cause of acute renal failure. *Postgrad Med* 72:145-158, 1982
13. Garland H, Moorhouse D: Compressive lesions of the external popliteal (common peroneal) nerve. *Br Med J* 2:1372-1376, 1952
14. Costley DO: Peripheral nerve injury. *Int Anesthesiology Clin* 10:189-206, 1972
15. Little DM Jr: Posture and anaesthesia. *Can Anaesth Soc J* 7:2-15, 1960
16. Tondare AS, Naokarni AV, Sathe CH, Dave VB: Femoral neuropathy: A complication of lithotomy position under spinal anaesthesia. Report of three cases. *Can Anaesth Soc J* 30:84-86, 1983

Anesthesiology  
60:238-240, 1984

## CVP Catheter Placement from the Antecubital Veins Using a J-Wire Catheter Guide

SUSAN L. SMITH, M.D.,\* MAURICE S. ALBIN, M.D.,† RICHARD R. RITTER, M.D.,‡ LEONID BUNEGIN, B.S.§

Catheterization of a central vein is used for measurement of central venous pressure (CVP), for rapid administration of fluids or blood products, and when accurately placed, removal of entrained air embolism is possible. Insertion of a CVP catheter from the basilic or cephalic veins of the arm offers few complications, but success often is hampered by an inability to advance the catheter into the larger intrathoracic veins. Using a catheter system equipped with a lumen-following J-wire guide, we inserted central venous catheters from antecubital sites and evaluated ease of insertion and final catheter position.

### METHODS

Seventy-seven adult patients undergoing elective neurosurgical or general surgical procedures were studied. All were felt to clinically require and consented to CVP monitoring. All catheters were inserted by members of the resident staff or faculty of our Department.

After application of a tourniquet, the antecubital fossa

was prepared and draped in a sterile fashion. An antecubital vein was cannulated with either a 14- or 16-gauge 7.5-cm over-the-needle Teflon® catheter or 18-gauge thin-wall 7.0-cm needle. Catheter or needle placement was confirmed by aspiration of blood. The tourniquet was removed and a flexible, angiographic wire catheter guide with a J-tip (3.0 mm radius on the J-curve, 150 cm length, 0.078 cm OD) was inserted through the catheter or the 18-gauge needle. The wire was advanced until the tip was felt to be beyond the shoulder and into the intrathoracic veins. The length needed was estimated by external measurement from the antecubital fossa to the mid-clavicle. Any obstructions encountered were passed by manipulation of the wire and/or reposition of the patient's arm. The needle/catheter then was removed over the wire and a siliconized polyethylene catheter (0.195 cm OD and 60 cm long) advanced over the wire to its hub. The wire was removed, aspiration of blood through the catheter confirmed, and an iv infusion connected to document flow. The catheter then was connected to a pressure transducer and oscilloscopic display and the pressure wave form evaluated to determine whether or not the catheter was in the right ventricle. Position of the catheter was documented radiographically. The catheter hub then was secured and a sterile occlusive dressing placed over the site of cannulation. Failure of placement was defined as either inability to cannulate an antecubital vein or inability to pass the J-wire or catheter into the central veins. §

\* Fellow in Neuroanesthesia.

† Professor of Anesthesiology and Neurosurgery.

‡ Professor of Anesthesiology.

§ Instructor in Anesthesiology.

Received from the Department of Anesthesiology, The University of Texas Health Science Center at San Antonio, and The Audie Murphy Veterans Administration Hospital, San Antonio, Texas. Accepted for publication August 2, 1983.

Address reprint requests to Dr. Albin: Department of Anesthesiology, University of Texas Health Science Center, San Antonio, Texas 78284.

Key words: Veins: antecubital, cannulation; Equipment: J-wire.

§ This unit was supplied by Cook Incorporated, Bloomington, Indiana, as the Albin-Bunegin CVP Kit.