

4. Stanski DR, Burch PG, Harapat S, Richards RK: The pharmacokinetics and anesthetic potency of a thiopental isomer. *J Pharm Sci*. In press
5. Michiels M, Hendriks R, Heykants J: A sensitive radioimmunoassay for fentanyl—Plasma levels in dogs and man. *Eur J Clin Pharmacol* 12:153–158, 1977
6. White PF, Johnston RR, Pudwill CR: Interaction of ketamine and halothane in rats. *ANESTHESIOLOGY* 42:179–186, 1975
7. White PF, Way WL, Trevor AJ: Ketamine—Its pharmacology and therapeutic uses. *ANESTHESIOLOGY* 56:119–136, 1982
8. McQuay JH, Moore RA, Paterson GMC, Adams AP: Plasma fentanyl concentrations and clinical observations during and after operation. *Br J Anaesth* 51:543–550, 1979
9. Hengstmann JH, Stoeckel H, Schüttler J: Infusion model for fentanyl based on pharmacokinetic analysis. *Br J Anaesth* 52:1021–1025, 1980
10. Moldenhauer CC, Hug CC Jr: Continuous infusion of fentanyl for cardiac surgery. *Anesth Analg* 61:206, 1982
11. Benumof JL, Canada ED, Scanlon TS, Herren AL: Intravenous anesthesia and postoperative analgesia. *Anesth Analg* 60:240–241, 1981
12. Wieber J, Gugler R, Hengstmann JH, Dengler HJ: Pharmacokinetics of ketamine in man. *Anaesthesist* 24:260–263, 1975
13. Idvall J, Ahlgren I, Aronsen KF, Stenberg P: Ketamine infusion—Pharmacokinetics and clinical effects. *Br J Anaesth* 51:1167–1173, 1979
14. McClain DA, Hug CC: Intravenous fentanyl kinetics. *Clin Pharmacol Ther* 28:106–114, 1980
15. Koska AJ, Romagnoli A, Kramer WG: Effect of cardiopulmonary bypass on fentanyl distribution and elimination. *Clin Pharmacol Ther* 29:100–105, 1981
16. Clements JA, Nimmo WS: Pharmacokinetics and analgesic effect of ketamine in man. *Br J Anaesth* 53:27–30, 1981
17. Becker KE: Plasma levels of thiopental necessary for anesthesia. *ANESTHESIOLOGY* 49:192–196, 1978

Anesthesiology
59:569–572, 1983

New and Easy Techniques for Fiberoptic Endoscopy-aided Tracheal Intubation

STEPHEN N. ROGERS, M.D.,* AND JONATHAN L. BENUMOF, M.D.†

Whenever tracheal intubation by direct laryngoscopy is considered very difficult or dangerous, fiberoptic endoscopy-aided tracheal intubation often is considered.^{1–5} However, current fiberoptic intubation techniques require that the endoscopist have considerable experience and frequent practice in order to maneuver the fiberoptic instrument efficiently and safely past irregularly shaped, often moving, and sometimes secretion-filled upper airway segments.^{2,6–8} Since the fiberoptic bronchoscope has been introduced only recently, many practicing anesthesiologists have received no organized instruction in its use. Consequently, they do not include fiberoptic endoscopy-aided tracheal intubation in their therapeutic armamentarium.

We report our successful experience with two newly developed airway devices that make fiberoptic endoscopy-aided tracheal intubation simple and easy, even in the

hands of inexperienced operators. The oral Airway Intubator⁹ is a plastic oropharyngeal airway with a cylindrical passage down the midlongitudinal axis, which permits the concentric insertion of a fiberoptic bronchoscope and endotracheal tube; the distal end of the device locates in close proximity to the laryngeal aperture. The anesthesia mask with diaphragm¹⁰ permits introduction of a fiberoptic bronchoscope into the airway without the loss of a seal for positive-pressure ventilation. These two airway adjuncts allow fiberoptic tracheal intubation to be performed easily and safely by the oral route in both awake and positive-pressure ventilated anesthetized patients.

METHODS

The tracheas of 25 adult patients who required general endotracheal anesthesia and either had a history of difficult tracheal intubation or were considered at preoperative evaluation to be potentially difficult to intubate were intubated fiberoptically using the techniques described below. Approval to perform this study was obtained from our local committee on human research. Tracheal intubation was performed under local anesthesia in 16 patients and under general anesthesia in the remaining nine. Patients were unpremedicated or received diazepam 5–10 mg po or morphine 5–10 mg im prior to arrival in the operating room.

Patients undergoing fiberoptic tracheal intubation under local anesthesia first gargled with 30 ml of viscous

* Research Fellow.

† Professor of Anesthesia.

Received from the Anesthesia Research Laboratory, University of California, San Diego, La Jolla, California. Accepted for publication May 16, 1983. Supported by the University of California, San Diego, Department of Anesthesia.

Address reprint requests to Dr. Benumof: Anesthesia Research Laboratory T-001, University of California, San Diego, La Jolla, California 92093.

Key words: Equipment: fiberoptic bronchoscope. Intubation, endotracheal: technique.

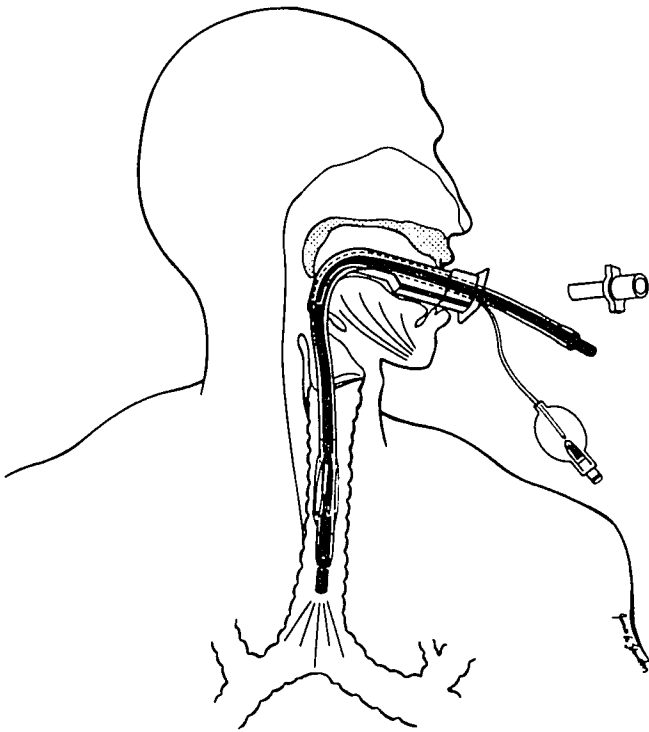


FIG. 1. Schematic diagram showing the use of the oral airway intubator as an aid to fiberoptic tracheal intubation. The fiberoptic scope has been passed through the oral Airway Intubator into the trachea and the endotracheal tube as been passed over the fiberoptic scope. The fiberoptic scope then is removed, and the airway intubator is either left in place as a bite block or removed over the endotracheal tube (prior to attachment of the endotracheal tube adaptor).

lidocaine. Nebulized lidocaine 4% or tetracaine 0.45% with epinephrine 1:250,000 was applied to the mouth, tongue, and posterior pharynx, with the patient gargling any residue. Bilateral superior laryngeal nerve blocks were performed with a total of 4 ml of lidocaine 2%, followed by transtracheal injection of 2 ml of lidocaine 4%. Most patients were sedated with fentanyl 50–100 μ g iv and diazepam 5–10 mg iv. All patients remained responsive to commands.

After adequate anesthesia of the airway was achieved, the Airway Intubator (#9 or #10) was inserted into the mouth. The anesthesiologist stood at the patient's side facing cephalad and held the fiberoptic bronchoscope so that the maneuverable tip lever and suction port were at 6 and 12 o'clock, respectively. A 4.9 mm OD fiberoptic bronchoscope (Olympus BF, type 4B2) was lubricated with clear lidocaine jelly 2% and inserted through an endotracheal tube (7–8.5 mm) so that the endotracheal tube jacketed the proximal end of the bronchoscope. The fiberoptic bronchoscope then was introduced into the Airway Intubator, advanced through the Airway Intubator, through the vocal cords, and on into the trachea. Once the tip of the fiberoptic bronchoscope was positioned well into the trachea, but above the carina, it was used

as a guide over which the endotracheal tube was advanced (fig. 1). The fiberoptic bronchoscope was used to verify correct positioning of the endotracheal tube before it was removed. The oral Airway Intubator either was removed over the endotracheal tube (and then the connector attached) or was left in place to be used as a bite block (connector attached right away). General anesthesia then was induced with thiopental iv.

In those patients undergoing general anesthesia before tracheal intubation, the anesthesia mask with diaphragm was used in place of a standard anesthesia mask. General anesthesia was induced either by inhalation of a volatile anesthetic in oxygen (four patients) or by iv drugs (five patients). After induction of anesthesia, the oral Airway Intubator was inserted. The responsibility of airway maintenance, mask fit, and ventilation (either assisted or controlled) was assumed by another anesthetist. As in those patients whose tracheas were intubated with no general anesthesia, the bronchoscope was fitted with an endotracheal tube and the anesthesiologist approached

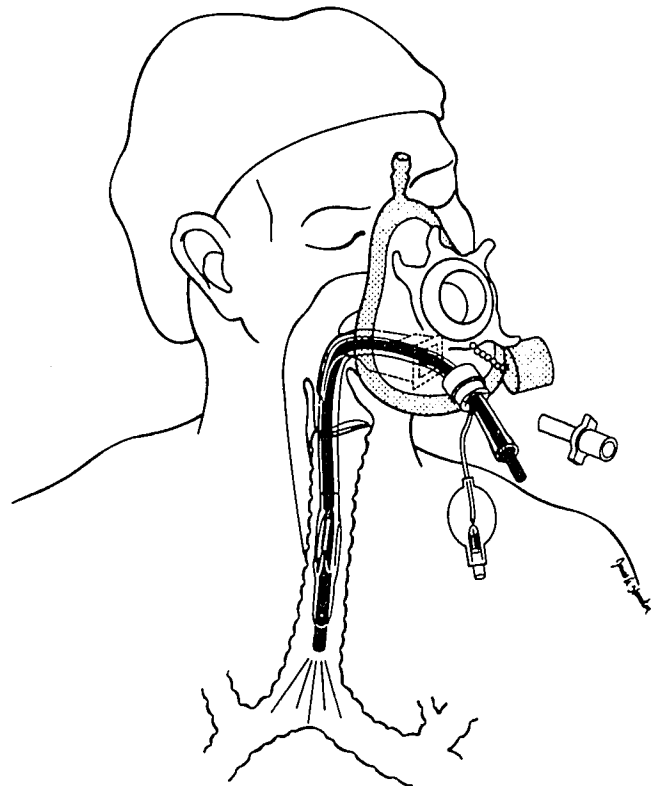


FIG. 2. Schematic diagram showing the use of the anesthesia mask with diaphragm and oral Airway Intubator as aids to fiberoptic tracheal intubation in an anesthetized (and paralyzed) patient. The procedure is the same as in figure 1, except that the fiberoptic scope and endotracheal tube have been introduced through the diaphragm in the anesthesia mask. After the endotracheal tube is in place, the fiberoptic scope is removed from within the endotracheal tube and the anesthesia mask with diaphragm is removed over the endotracheal tube (before the endotracheal tube adaptor is connected). Removal of the oral Airway Intubator is optional as in figure 1.

from the patient's side facing cephalad. The fiberoptic bronchoscope was passed through the mask diaphragm into the Airway Intubator. The rest of the procedure was similar to that for awake endotracheal intubation, except that the endotracheal tube passed through the mask diaphragm as it was advanced over the fiberoptic bronchoscope (fig. 2). The endotracheal tube connector was attached after the mask was removed.

RESULTS

Table 1 lists the airway problems we encountered for which intubation of the trachea was known or considered to be very difficult and/or dangerous. Three patients had a history of failed tracheal intubations performed by experienced anesthetists using techniques other than fiberoptic endoscopy. Two patients had a history of difficult fiberoptic tracheal intubations performed by experienced operators using conventional (awake, nasal route) fiberoptic techniques. Two patients had anesthesia records indicating difficult intubation by direct laryngoscopy.

In all of the 25 patients, fiberoptic orotracheal intubation was successfully, atraumatically, and rapidly (less than 2 min) completed by the original anesthesiologist. In all patients intubation of the trachea was performed by an operator with fewer than three fiberoptic intubations or endoscopy experiences, and in eight of the patients intubation was performed by an operator with no prior fiberoptic intubation or endoscopy experience. All patients were hemodynamically stable and no arrhythmias were noted during the fiberoptic intubations.

Figure 3 is a serial photographic record of a typical experience in passing the fiberoptic scope through the oral Airway Intubator to the vocal cords. Passage of the fiberoptic bronchoscope down to the end of the oral Airway Intubator can be done passively and requires no prior experience (figs. 3A and B). When the fiberoptic bronchoscope reached the distal end of the oral Airway Intubator, the epiglottis was always in clear view (fig. 3C)

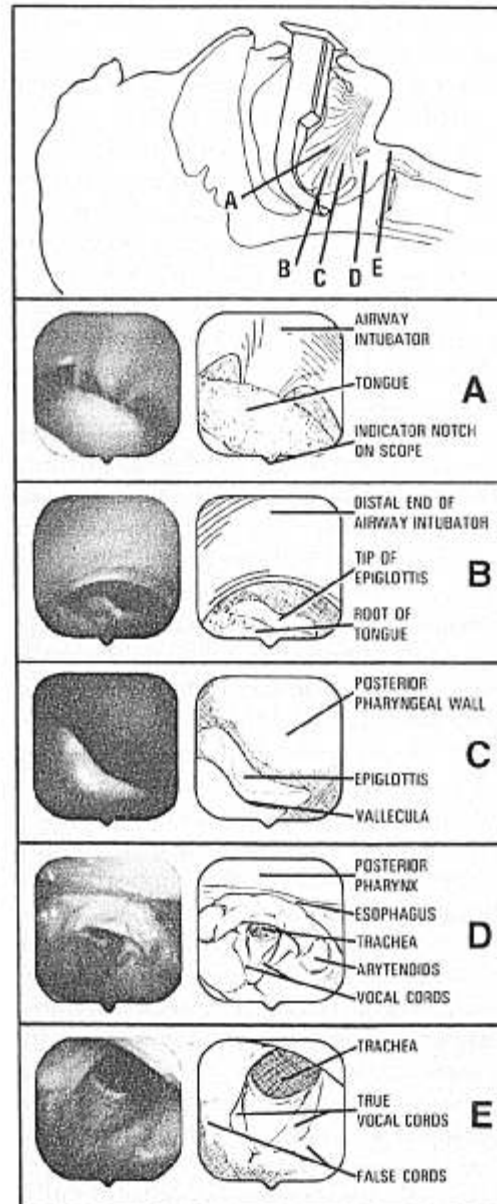


FIG. 3. Serial photographs of a typical experience in passing the fiberoptic bronchoscope through the oral Airway Intubator to the vocal cords. The photographs were taken via the fiberoptic bronchoscope with the operator at the patient's right side facing cephalad; thus the orientation of each view is inverted (and rotated slightly) compared with that seen with direct laryngoscopy. The top panel is a schematic diagram showing the location of the tip of the fiberoptic bronchoscope to which each photograph corresponds. Each photograph is accompanied by a schematic diagram of the anatomy to help understand the contents of the photograph. See results section for further explanation of the photographic record.

TABLE 1. Airway Problems Encountered in (N) Patients

Rheumatoid arthritis	6*
Burn contractures	6*
Cervical spine fracture	4
Fused cervical spine	2
History of difficult intubation	2†
Laryngeal tumor	2
Pharyngeal abscess	1
Congenital deformity	1
Large incisors	1
Total	25‡

* Three of these patients had a previous history of failed endotracheal intubation by nonfiberoptic methods. Two of these patients had a previous history of difficult fiberoptic intubations via the nasal route.

† Previous anesthesia record note.

‡ All endotracheal intubations were performed by operators with none to three fiberoptic intubation and endoscopy experiences.

and sometimes the vocal cords could also be seen at this point. In patients where just the epiglottis was seen, the tip of the bronchoscope simply was flexed posteriorly, under the epiglottis, which brought the vocal cords into the center of the fiberoptic field of view (figs. 3D and E); the fiberoptic bronchoscope then could be advanced

through the cords into the trachea. The local anesthetic blocks and an adequate depth of general anesthesia provided a quiet and nonreactive intubation field in the awake and anesthetized patients, respectively.

We encountered a few relatively minor and easily solved problems during these 25 fiberoptic tracheal intubations. First, we found it very helpful to keep both the Airway Intubator and the fiberoptic bronchoscope oriented in the midline sagittal plane of the patient (flexible tip lever and suction port at 6 o'clock and 12 o'clock, respectively). This not only helped the operator remain oriented but also facilitated maneuvering the tip of the bronchoscope under the epiglottis and into the trachea. Second, we found while trying to advance the endotracheal tube over the fiberoptic bronchoscope through the *opaque* anesthesia mask, that the tip of the endotracheal tube occasionally did not slide easily into the entrance of the Airway Intubator. To remedy this situation, we constructed an anesthesia mask with diaphragm made of clear plastic, which allowed external visualization of the entry of the tip of the endotracheal tube into the oral Airway Intubator. Third, in two cases, the endotracheal tube failed to advance easily over the fiberoptic bronchoscope, stopping at approximately the cord level. This problem appeared to be due to either the tip of the endotracheal tube catching on the vocal cords or epiglottic structures or a kink in the fiberoptic bronchoscope as the advancing endotracheal tube drew the bronchoscope posteriorly into the esophagus. We found that we could remedy these problems easily by either rotating the endotracheal tube 180° so that its natural curve was opposite that of the bronchoscope, then advancing the endotracheal tube over the bronchoscope, or slowly pulling back on the fiberoptic bronchoscope as the endotracheal tube was advanced over it. The latter problem may be more common with the smaller diameter and more flexible fiberoptic bronchoscopes.

DISCUSSION

Previous methods of fiberoptic tracheal intubation have been ill-suited to the needs of anesthesiologists. Most operators have utilized the nasal route in awake patients.^{1,2,4,5,11,12} This route not only requires considerable skill in manipulating the fiberoptic bronchoscope past soft tissue, mucous, and blood obstructions, but may also limit the size of the endotracheal tube that can be inserted. In the past, use of the oral route in the awake patient has required excellent patient cooperation (biting teeth will destroy a fiberoptic bronchoscope), while use of the oral route in the anesthetized patient has precluded positive-pressure ventilation and often required an assistant to pull the tongue forward.¹³⁻¹⁶

The Airway Intubator greatly simplifies oral fiberoptic

intubation and protects the fiberoptic bronchoscope from the teeth. Thus, the Airway Intubator enables an inexperienced endoscopist to perform fiberoptic orotracheal intubation quickly and efficiently in the awake patient without assistance. The anesthesia mask with diaphragm permits uninterrupted positive pressure mask ventilation during fiberoptic intubation. The anesthesia mask with diaphragm also allows the administration of potent volatile anesthetics and a high inspired oxygen concentration during fiberoptic orotracheal intubation. This method not only provides optimum, unhurried conditions for fiberoptic intubation, but allows time for teaching fiberoptic techniques without danger or discomfort to the patient. The problems encountered with our techniques are solved easily by maintaining proper bronchoscope and oral Airway Intubator orientation, a good airway, using a clear anesthesia mask and by remembering two simple endotracheal tube and fiberoptic scope maneuvers. We feel that these new methods make the technique of fiberoptic intubation immediately available to all anesthesiologists, even those without prior training in its use.

REFERENCES

- Messeter RH, Pettersson KI: Endotracheal intubation with the fiber-optic bronchoscope. *Anaesthesia* 35:294-298, 1980
- Edens ET, Sia RL: Flexible fiberoptic endoscopy in difficult intubations. *Ann Otol* 90:307-309, 1981
- Taylor PA, Towey RM: The bronchofibroscope as an aid to endotracheal intubation. *Br J Anaesth* 44:611-612, 1972
- Mulder DS, Wallace DH, Woolhouse FM: The use of the fiberoptic bronchoscope to facilitate endotracheal intubation following head and neck trauma. *J Trauma* 15:638-640, 1975
- Sackner MA, Wanner A, Landa J: Applications of bronchofibroscopy. *Chest (suppl, part 2)* 62:70S-78S, 1972
- Salem MR, Mathrubhutham M, Bennet EJ: Difficult intubation. *N Engl J Med* 295:879-881, 1981
- Sia RL, Edens ET: How to avoid problems when using the fiberoptic bronchoscope for difficult intubation. *Anaesthesia* 36:74-75, 1981
- Zavala D: Fiberoptic bronchoscopy. Indications and recommendations for certification. *Resp Ther* 12(5):23-28, 1982
- Williams RT, Maltabay JY: Airway intubator. *Anesth Analg* 61:309, 1982
- Patil V, Stehling LC, Zauder ML, Koch JP: Mechanical aids for fiberoptic endoscopy. *ANESTHESIOLOGY* 57:69-70, 1982
- Murphy T: A fiberoptic endoscope used for nasal intubation. *Anaesthesia* 22:489-491, 1967
- Conyers AB, Wallace DH, Mulder DS: Use of the fiberoptic bronchoscope for nasotracheal intubation: Case report. *Canad Anaesth Soc J* 19:654, 1972
- Lloyd EL: Fiberoptic laryngoscopy for difficult intubation. *Anaesthesia* 35:719, 1980
- Wang JF, Reves JG, Corssen G: Use of the fiberoptic laryngoscope for difficult tracheal intubation. *Alabama J Med Sci* 13:247-251, 1976
- Raj PP, Forestner J, Watson TD, Morris RE, Jenkins MT: Techniques for fiberoptic laryngoscopy in anesthesia. *Anesth Analg* 53:708-714, 1974
- Childress WF: New method for fiberoptic endotracheal intubation of anesthetized patients. *ANESTHESIOLOGY* 55:595-596, 1981