

Catastrophic Pulmonary Vasoconstriction Associated with Protamine Reversal of Heparin

EDWARD LOWENSTEIN, M.D.,* WILLIAM E. JOHNSTON, M.D.,† DEMETRIOS G. LAPPAS, M.D.,‡
MICHAEL N. D'AMBRA, M.D.,§ ROBERT C. SCHNEIDER, M.D.,¶ WILLARD M. DAGGETT, M.D.,**
CARY W. AKINS, M.D.,†† DANIEL M. PHILBIN, M.D.‡

The hemodynamic effects of protamine sulfate remain controversial despite enormous experience with the drug. For many years, we have administered protamine by slow iv infusion in an attempt to avoid hypotension apparently associated with its rapid iv administration. With recent decreases in the doses of protamine administered because of monitoring of activated clotting times¹ and recent experience of others advocating rapid administration of protamine,² we decided to administer small iv bolus doses of protamine. Severe, precipitous hypotension occurred in five patients with this practice. We were able to establish pulmonary vasoconstriction as a primary cause of acute cardiovascular deterioration in humans when heparin is reversed by protamine.

REPORTS OF FIVE CASES

Patient 1 (fig. 1)

A woman with mitral valve disease underwent mitral valve replacement. Cardiopulmonary bypass was terminated uneventfully. Twelve minutes later, protamine, 35 mg, was administered over 200 s in increments of 10, 10, and 15 mg via the right atrial port of a pulmonary artery catheter. Over the next 30 s the central venous pressure doubled, and the left atrial pressure fell from 14 to 3 mmHg. The right ventricle became severely distended and hypokinetic, and systemic arterial blood pressure decreased to 40/30 mmHg. Two increments of CaCl_2 injected

into the left atrium and epinephrine infused into the superior vena cava resulted in restoration of systemic arterial pressure and active right ventricular contraction. The pulmonary vascular resistance, which had been 2.8 units prior to protamine administration, was doubled immediately after resolution of the episode and gradually decreased. Left atrial hypertension accompanying the restoration of blood pressure was relieved by phlebotomy. Reversal of heparin was completed without incident by a slow iv protamine infusion. The remainder of the procedure and postoperative course was uneventful.

Patient 2

A woman with mitral stenosis, a mitral valve area of 0.9 cm,² and normal pulmonary vascular resistance and coronary arteries underwent mitral valve replacement. Termination of cardiopulmonary bypass was uneventful. Administration of protamine (30 mg over 160 s) into the right atrial port of the pulmonary artery catheter was associated with sudden elevation of right atrial pressure from 5 to 10 mmHg, left atrial hypotension (15 mmHg to 5 mmHg), and systemic hypotension to 45/30 mmHg. This was accompanied by 2 mm of ST-segment depression in lead V₅. An iv epinephrine infusion reversed these changes. The remainder of the postoperative course was uneventful.

Patient 3 (fig. 2)

A man with unstable angina pectoris unrelieved by medication had an intraaortic balloon pump placed with relief of pain and underwent coronary artery bypass grafting. Termination of cardiopulmonary bypass was uneventful, though balloon counterpulsation was continued electively. One hundred seconds after two apparently well-tolerated 5-mg iv doses of protamine, a 20-mg iv dose was administered via a central vein. The pulmonary artery pressure rose precipitously, with the diastolic pressure increasing from 15 to 37 mmHg over the next minute. Simultaneously, the left atrial pressure decreased from 10 mmHg to 0 mmHg, and severe systemic hypotension occurred. The central venous pressure increased from 9 mmHg to a maximum of 19 mmHg. The pulmonary artery catheter appeared to "wedge" with a mean reading of 28 mmHg at a time when the left atrial pressure was approximately 6 mmHg. Initial treatment with an iv epinephrine infusion resulted in restoration of arterial pressure. Subsequent systemic hypertension was accompanied by left atrial hypertension and decrease of right atrial pressure. Substitution of isoproterenol for epinephrine was associated with a return of hemodynamic variables to within normal limits. The subsequent hospital course was uneventful.

Patient 4

A woman who had undergone two previous cardiac surgical procedures (mitral and aortic valve replacement, 1968, and mitral valve replacement, 1975) had tricuspid insufficiency, pulmonary artery hypertension, a cardiac index of $3.0 \text{ l} \cdot \text{min}^{-1} \cdot \text{m}^{-2}$ and pulmonary vascular resistance of 8.4 units. She underwent tricuspid annuloplasty, and cardiopulmonary bypass was terminated with the aid of iv norepinephrine (arterial blood pressure 95/50 mmHg, pulmonary artery pressure 35/12 mmHg, pulmonary artery occluded pressure 16

* Professor, Harvard Medical School, Anesthetist, Massachusetts General Hospital.

† Fellow in Cardiac Anesthesia, Massachusetts General Hospital.

‡ Associate Professor, Harvard Medical School, Associate Anesthetist, Massachusetts General Hospital.

§ Instructor, Harvard Medical School, Assistant in Anesthesia, Massachusetts General Hospital.

¶ Assistant Professor, Harvard Medical School, Assistant in Anesthesia, Massachusetts General Hospital.

** Professor of Surgery, Harvard Medical School, Visiting Surgeon, Massachusetts General Hospital.

†† Assistant Professor, Harvard Medical School, Assistant in Surgery, Massachusetts General Hospital.

Received from the Cardiac Anaesthesia Group, Department of Anesthesia, Surgical Cardiovascular Unit, and Anaesthesia Laboratories of the Harvard Medical School at Massachusetts General Hospital, and the Departments of Anaesthesia and Surgery, Harvard Medical School, Boston. Accepted for publication April 15, 1983.

Address reprint requests to Dr. Lowenstein: Department of Anesthesia, Massachusetts General Hospital, Boston, Massachusetts 02114.

Key words: Blood: coagulation, protamine. Complications: hypotension. Lung: vasoconstriction. Mediators: thromboxane; leukotrienes, anaphylatoxins, complement, histamine.

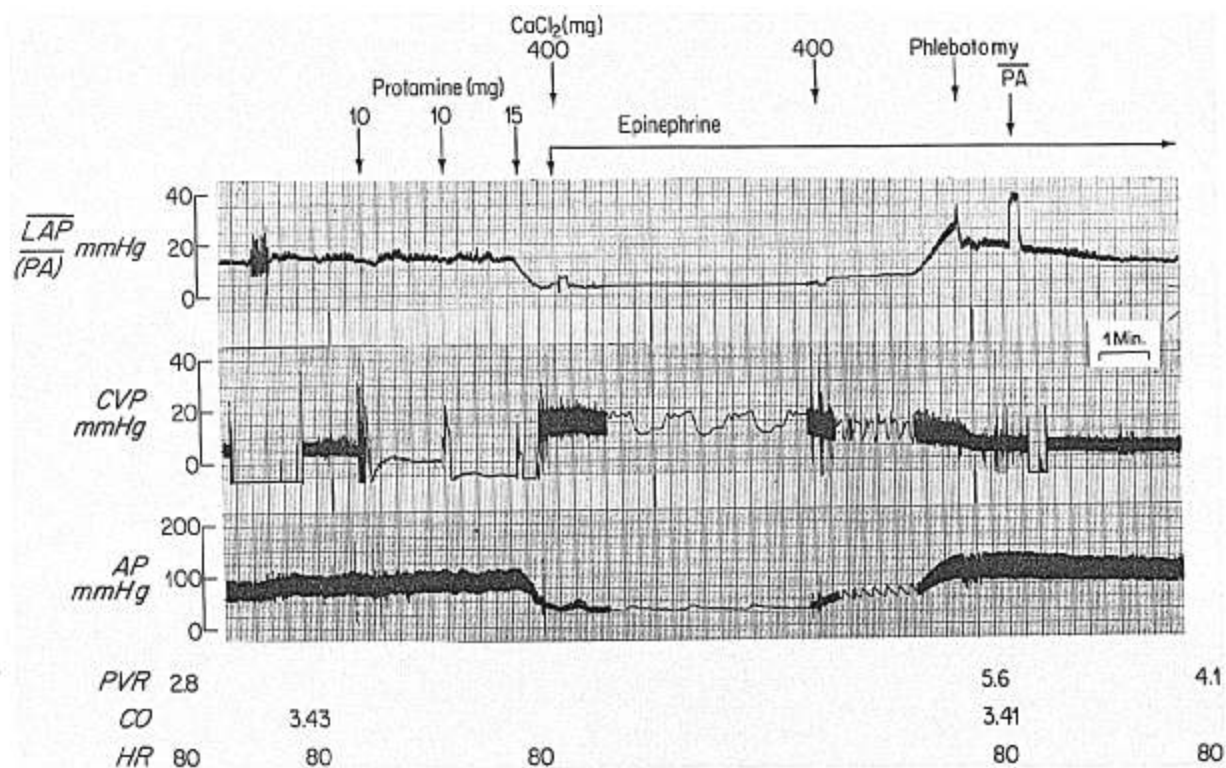


FIG. 1. Acute RV failure and precipitous hypotension associated with administration of 35 mg protamine in patient 1 shortly following mitral valve replacement. See text for details. LAP = mean left atrial pressure; PA = mean pulmonary artery pressure; CVP = right atrial pressure; AP = systemic arterial pressure; PVR = pulmonary vascular resistance (U); CO = cardiac output (l/min); HR = heart rate (beats/min).

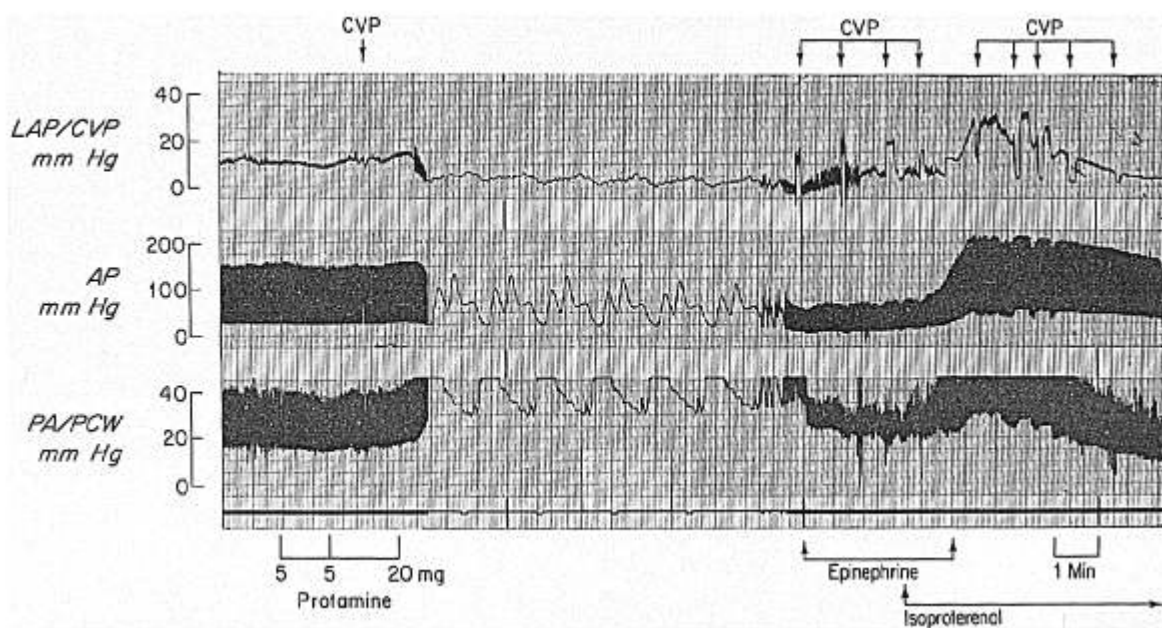


FIG. 2. Protamine-induced systemic hypotension in patient 3 following myocardial revascularization. Note the precipitous increase in pulmonary artery and right atrial pressure and decrease in left atrial pressure. See text for details.

mmHg, right atrial pressure 12 mmHg, cardiac output 6.6 l/min, and systemic vascular resistance 6.7 U). Four 5-mg iv increments of protamine administered over 2 min via a peripheral vein were associated with elevation of pulmonary artery pressure to 85/42 mmHg and right atrial pressure to 20 mmHg and with decrease of systemic arterial blood pressure to 65/35 mmHg. Treatment with CaCl_2 300 mg iv was associated with reversion of hemodynamic variables to previous values. A slow iv infusion of protamine was tolerated subsequently without incident.

Patient 5

A woman with mitral stenosis, mitral and tricuspid valve insufficiency, and pulmonary hypertension underwent mitral valve replacement and tricuspid valvuloplasty. Cardiopulmonary bypass was terminated with the aid of atrioventricular sequential pacing and iv dopamine and epinephrine. With the beginning of iv protamine administration, right atrial pressure increased to 35 mmHg and left atrial pressure decreased to 0 mmHg. Partial cardiopulmonary bypass was reestablished for 30 min. Thereafter, bypass was terminated again with the same medications. Heparin was neutralized uneventfully by a slow iv protamine infusion.

One week postoperatively, the patient developed intermittent sinus tachycardia and symptoms of congestive heart failure. Two-dimensional echocardiograms and a physical examination suggested a paraprosthetic leak. Therefore, cardiac catheterization was performed after the iv administration of heparin 50 mg. The valve proved competent. Administration of protamine 30 mg iv was associated with hypotension, bradycardia, respiratory insufficiency, and bronchospasm. The trachea was intubated, positive-pressure ventilation instituted, and atropine 0.4 mg and epinephrine 0.3 mg administered iv with restoration of adequate circulation and relief of bronchospasm. No sequelae occurred. The patient was discharged 1 week later with a diagnosis of "protamine allergy."

DISCUSSION

We described five patients who sustained precipitous life-threatening cardiovascular changes associated with the iv administration of protamine to reverse heparin anticoagulation. The primary event appeared to consist of severe pulmonary vascular constriction, leading to inability to transfer blood across the pulmonary vascular bed, decrease in left ventricular volume, and systemic hypotension. The obstruction to right ventricular outflow was associated with pulmonary artery hypertension and right ventricular failure.

In 1974, Jastrzebski *et al.* described delayed pulmonary hypertension after the iv administration of 6 mg/kg protamine but did not relate this to systemic arterial hypotension.³ Mechanisms implicated in protamine-associated hypotension include anaphylaxis,⁴ histamine release,⁵ hypocalcemia,⁶ myocardial depression,^{7,8} and systemic vasodilation.^{5,9} In our patients, neither primary myocardial depression nor vasodilation appeared responsible.

The dose and rate of protamine administration are noteworthy in our cases. The highest total dose was 0.5 mg/kg iv. This is a small dose compared with the 3–6 mg/kg doses advocated and utilized clinically.^{3,5,9}

The rate of administration has been considered important in the genesis of hypotension. The package insert recommends a maximum of 5 mg · min⁻¹ iv. Conahan *et*

*al.*² cast doubt upon the necessity for such low infusion rates. However, their data do not support the conclusion that the rapid iv administration is safe because decreases of mean arterial blood pressure of up to 40 mmHg were reported. The method of data analysis employed by Conahan *et al.*² obscures events that occur infrequently. Furthermore, the recent data of Masone *et al.* indicate that rapid (400–500 mg/90 s) injection of protamine into the right atrium but not the left atrium, is associated predictably with hypotension.⁵

While iv protamine administration usually is well tolerated, sporadic cardiovascular collapse with even low doses appears to be a predictable event. The syndrome we describe was noted with central and peripheral iv protamine administration, primary valvular and coronary artery disease, intraoperatively and in the cardiac catheterization laboratory. Because of the preponderance of patients with mitral valve disease, we speculate that underlying pulmonary vascular disease may predispose to protamine-induced pulmonary vasoconstriction. Three of our cases occurred in 1 month in which approximately 100 cardiac surgical operations employing administration of heparin and protamine were performed. While we are unable to define an incidence, we suspect pulmonary vasoconstriction is not a rare occurrence when protamine is administered rapidly.

The optimal therapy for this syndrome is unclear. Three of our patients received iv epinephrine with prompt restoration of systemic arterial blood pressure and resolution of right ventricular failure. They subsequently demonstrated left atrial hypertension, relieved in one case by phlebotomy and in a second by cessation of epinephrine and administration of isoproterenol.

Although anaphylaxis has been observed with protamine administration, the reactions we observed appear to differ from classic anaphylaxis.^{4,11} We hypothesize they are due, at least in part, to the anaphylatoxins.¹² Cardiopulmonary bypass is associated with complement activation, with subsequent pulmonary sequestration of neutrophils.¹³ Heparin and protamine *in vitro* form complexes that activate complement.¹⁴ Protamine also acts as a substrate of C-reactive protein, a potent activator of the complement system.¹⁵ Complement infusion in sheep causes severe pulmonary hypertension mediated by thromboxane and perhaps other cyclooxygenase and lipoxygenase products.¹⁶ Further studies are required to define more precisely the mechanisms and mediators involved in this syndrome.

On the basis of our observations in the operating room and the cardiac catheterization laboratory, we believe all physicians administering protamine to reverse heparin should be aware of this syndrome. In addition, it seems prudent to administer this drug at a maximum rate of 5 mg/min and have epinephrine and isoproterenol ready for prompt treatment if circulatory collapse occurs.

ADDENDUM

Since preparation of this article, we have observed the identical syndrome after intraaortic injection of 275 mg of protamine over 4 min in a patient with mitral valve disease. We, therefore, conclude that left sided injection does not confer absolute protection against protamine-associated pulmonary vasoconstriction.

The authors gratefully acknowledge the advice of Tony E. Hugli, Ph.D., Scripps Research Foundation, La Jolla, California, and Jerrold H. Levy, M.D., Department of Anesthesiology, Emory University, Atlanta, Georgia.

REFERENCES

1. Bull BS, Huse WM, Brauer FS, Korpman RA: Heparin therapy during extracorporeal circulation. *J Thorac Cardiovasc Surg* 69:685-689, 1975
2. Conahan TJ III, Andrews RW, MacVaugh H III: Cardiovascular effects of protamine sulfate in man. *Anaesth Analg* 60:33-36, 1981
3. Jastrzebski J, Sykes MK, Woods DG: Cardiorespiratory effects of protamine after cardiopulmonary bypass in man. *Thorax* 29:534, 1974
4. Moorthy SS, Pond W, Rowland RG: Severe circulatory shock following protamine (an anaphylactic reaction). *Anesth Analg* 59:77-78, 1980
5. Masone R, Oka Y, Hong YW, Santos H, Frater RW: Cardiovascular effects of right atrial injection of protamine sulfate as compared to left atrial injection. *ANESTHESIOLOGY* 57:A6, 1982
6. Jones RM, Hill AB, Nahrwold ML, Tait AR: Effect of protamine on plasma ionized calcium in the dog. *Can Anaesth Soc J* 29:65-67, 1982
7. Fadali MA, Ledbetter M, Papacostas CA, Duke LJ, Lemole GM: Mechanism responsible for the cardiovascular depressant effect of protamine sulfate. *Ann Surg* 180:232-235, 1974
8. Goldman BS, Joison J, Austen WG: Cardiovascular effects of protamine sulfate. *Ann Thorac Surg* 7:459-471, 1969
9. Hurt R, Perkins HA, Osborn JJ, Gerbode F: The neutralization of heparin by protamine in extracorporeal circulation. *J Thorac Surg* 32:612-619, 1956
10. Sethna DH, Moffitt E, Gray RJ, Bussell J, Raymond M, Conklin C, Matloff JM: Effects of protamine sulfate on myocardial oxygen supply and demand in patients following cardiopulmonary bypass. *Anesth Analg* 61:247-251, 1982
11. Becker EL, Austen KF: Anaphylaxis, *Textbook of Immunopathology*. Edited by Miescher PA, Muller-Eberhard HF. New York, Grune and Stratton, pp 117-135, 1976
12. Stimler NP, Hugli TE, Bloor CM: Pulmonary injury induced by C3a and C5a anaphylatoxins. *Am J Pathol* 100:327-341, 1980
13. Chenoweth DE, Cooper SW, Hugli TE, Stewart RW, Blackstone EH, Kirklin JW: Complement activation during cardiopulmonary bypass: Evidence for generation of C3a and C5a anaphylatoxins. *N Engl J Med* 304:497-503, 1981
14. Rent R, Ertel N, Eisenstein R, Gewurz H: Complement activation by interactions of polyanions and polycations: Heparin-protamine induced consumption of complement. *J Immunol* 114:120, 1975
15. Siegel J, Rent R, Gewurz H: Interactions of C-reactive protein with the complement system. I. Protamine-induced consumption of complement in acute phase sera. *J Exp Med* 140:631, 1974
16. McDonald JWD, Ali M, Morgan E, Townsend ER, Cooper JD: Thromboxane synthesis by sources other than platelets in association with complement-induced pulmonary leukostasis and pulmonary hypertension in sheep. *Circ Res* 52:1-6, 1983

Anesthesiology
59:473-475, 1983

Postoperative Dorsal Epidural Analgesia in the Child with Respiratory Disabilities

MICHEL MEIGNIER M.D.,* RÉMI SOURON M.D.,† JEAN-CLAUDE LE NEEL M.D.‡

Pain after abdominal surgery may cause limitation of respiratory mechanics. Inspiratory capacity may be reduced, resulting in a rapid breathing pattern and limited coughing. All these factors can produce acute respiratory failure, possibly requiring controlled ventilation. Vigorous respiratory physiotherapy can reduce the risk of obstruction¹ but often is followed poorly by a patient who is in pain from abdominal surgery.

Relief of postoperative pain probably will reduce the incidence of severity of respiratory problems. Although administration of narcotics is one possibility, it entails the risk of respiratory depression. The choice of epidural block is another solution. Indications and benefits of this technique have been reported for adults in numerous publications.² However, no such data concerning postoperative epidural analgesia in the child have been reported. Furthermore, only caudal analgesia has been performed on infants and children,^{3,4} which provides excellent analgesia but at a low level and only for a short period of time. We describe our experience with dorsal epidural analgesia in children undergoing major abdominal surgery.

REPORT OF SEVEN CASES

The investigational protocol was approved by the Human Investigation Committee of our hospital, and written consent was obtained from the parents of the children.

* Staff Anesthesiologist.

† Professor and Chairperson of Anesthesiology.

‡ Professor of Surgery.

Received from the Département d'Anesthésiologie et Clinique Chirurgicale A, C.H.R., 44035 Nantes Cedex, France. Accepted for publication April 15, 1983.

Address reprint requests to Dr. Meignier: Département d'Anesthésiologie, Hôtel-Dieu—C.H.R., 44035 Nantes Cedex, France.

Key words: Anesthesia: pediatric. Anesthetic techniques: epidural, dorsal.