

# CLINICAL REPORTS

Ronald D. Miller, M.D., Editor

Anesthesiology  
59:66-68, 1983

## An Elevated Pulmonary Wedge Pressure Resulting from an Upper Respiratory Obstruction in an Obese Patient

EDWARD TEEPLE, M.D.,\* AND JAWAHAR N. GHIA, M.D.†

An elevated pulmonary wedge pressure usually is a sign of excessive intravascular volume overload or left ventricular failure. We describe an obese patient with no clinical symptoms of severe heart failure, whose pulmonary artery and wedge pressures were elevated as he was being prepared for surgery. The resolution of the abnormal finding with endotracheal intubation and an otherwise uncomplicated anesthesia course indicated the presence of a mechanical obstruction in the upper airway that was exaggerated when the patient was supine and sedated. The implications and interpretation of unexplained abnormalities in pulmonary wedge pressure in surgical patients is discussed, and methods of proceeding are proposed.

### REPORT OF A CASE

A 55-year-old man was scheduled for clipping of a basilar artery aneurysm. He had been admitted 1 week earlier for evaluation of left-sided weakness of 2 months duration. He had three episodes of transient ischemic attacks in the past 2 months. Aspirin was given after the most recent attack, which was 2 weeks before this admission. His medical history revealed adult onset diabetes mellitus of 15 years duration and hypertension of 10 years duration, both of which were well controlled by chlorpropamide (Diabinese®) 250 mg propranolol 80 mg and hydrochlorothiazide 25 mg, respectively. He described past episodes of nonradiating chest pain precipitated by exercise, two-pillow orthopnea, shortness of breath, and swelling of both his ankles. Several admissions to the cardiac care unit for evaluation of severe chest pain revealed no evidence of myocardial infarction. There was no history of acute upper respiratory infection, fever, allergy, or chronic lung disease. His medications also included KCl 80 mg/day nitroglycerin 1 tablet p.r.n. sublingually, isosorbide dinitrate 15 mg/day, nitropaste

ointment 1 in. per day, and digoxin 0.25 mg/day. The patient was a 100-kg obese man who was 174 cm tall with a short, thick, neck and very prominent jowls (slack flesh about the mandible).<sup>1</sup> His heart sounds were normal except for a systolic ejection murmur of grade I/VI, noted at the base of the heart and radiating to both carotid arteries. The lungs were normal to percussion and auscultation. The rest of the physical examination and laboratory results were normal except for the electrocardiogram, which showed left axis deviation. A stress test done 3 months before admission was negative. A cerebral angiogram revealed a basilar artery aneurysm.

Diazepam 10 mg po and morphine sulfate 10 mg im were administered 1 h before he came to the operating room. He looked drowsy when arriving in the operating room, but he was easily aroused and responded appropriately to questions. A flow-directed 7 French catheter was inserted via the right internal jugular vein after checking the balloon. The monitoring equipment was calibrated, air was removed from the lines, no leaks were found in the system, direct measurements were used (rather than electrical averaging of numbers), and the following values were recorded: the pulmonary artery pressure (PAP) was 42/24 mmHg (fig. 1), the wedge pressure (PAOP) at the end expiration was 38 mmHg (fig. 2), and the cardiac output was 6.58 l min<sup>-1</sup>.

The patient was asymptomatic, heart rate 95 beats/min and arterial blood pressure 150/80 mmHg. The respiratory rate was 12 breaths/min; a rocking motion of the chest and abdomen at end inspiration was noted and a slight expiratory grunt was audible with each breath. Auscultation of his lungs revealed slightly decreased breath sounds all over but no rales, and his chest was normal to percussion. His heart beat was normal with no S3 or S4 gallop. His abdomen was not distended, but there was a slight increase in tension on palpation. The patient had received approximately 700 ml of crystalloid IV to replace overnight losses.

A cardiologist was consulted, who stated that in the cardiac catheterization laboratory obese patients commonly have high wedge pressure values when studied in the supine position. He thought that the high values were related to the obesity and he cleared him for surgery. Because the patient had no clinical symptoms or signs of disease to explain the high wedge pressure, we decided to proceed with anesthesia.

General anesthesia was induced IV with fentanyl 100 µg, thiopental 500 mg slowly, and succinylcholine 100 mg, and the trachea was intubated uneventfully. During controlled ventilation, his heart rate was 95 beats/min, arterial blood pressure 130/80 mmHg, and PAP 34/18 mmHg. The wedge (PAOP) at end expiration was 5 mmHg, the cardiac output was 6.1 l min<sup>-1</sup>. Surgery proceeded without difficulty, and the trachea was extubated immediately after operation. In the intensive care unit, he received supplemental oxygen via a face mask and was kept in a semisitting position. A postoperative chest roent-

\* Assistant Professor of Anesthesiology.

† Associate Professor of Anesthesiology.

Received from the Department of Anesthesiology, The University of North Carolina at Chapel Hill, School of Medicine, Chapel Hill, North Carolina. Accepted for publication January 3, 1983.

Address reprint requests to Dr. Teeple: Department of Anesthesiology, The University of North Carolina, North Carolina Memorial Hospital 204-H, Chapel Hill, North Carolina, 27514.

Key words: Equipment: Catheters, flow-directed. Complications: Obesity. Lung: Intravascular pressures.

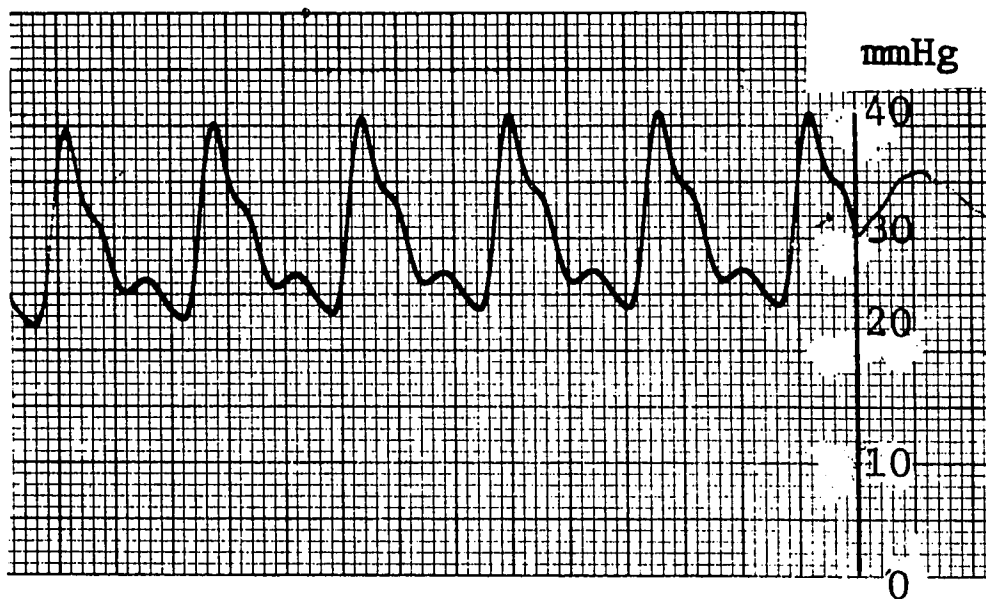


FIG. 1. Preinduction pulmonary artery tracing.

genogram showed no abnormalities in lung fields and ruled out Zone 1 placement of the Swan Ganz® catheter.<sup>2</sup> The patient was sent to the floor on the day after surgery in a satisfactory condition and has continued to do well.

#### DISCUSSION

After induction of general anesthesia, the abnormally high wedge pressure obviously resulted from a mild upper airway obstruction, because the value returned to normal after endotracheal intubation. Misleading wedge pressure values may result from 1) alterations in the intrapleural pressure, 2) Zone 1 placement of the catheter, 3) electrical averaging of the values, 4) eccentrically or overinflated balloon, or 5) inaccurate zeroing or calibration of the equipment.<sup>3,4</sup> Wedge pressure values were obtained by using end-expiratory values rather than averaging,<sup>3</sup> and they were elevated. The equipment was calibrated and zeroed correctly, and the balloon functioned normally intraoperatively and post-

operatively. The abnormally high wedge pressure in this patient could have resulted from changes in the intrapleural and intrapulmonary pressures brought about by the unrecognized mild upper respiratory obstruction. When the diaphragm is relaxed during expiration in the supine position, the abdominal viscera compress the lungs (especially in an obese patient). If there is an upper airway obstruction, it can create an intraluminal positive end expiratory pressure (PEEP). This spontaneous PEEP- ('AUTOPEEP') like effect could have converted a normal Swan Ganz catheter placement (Zone 2) into a Zone 1 placement<sup>2</sup> at end expiration in this patient, thus affecting the wedge pressure.

This explanation is substantiated further by comparison of our PAOP tracings with those of Walsh *et al.*,<sup>5</sup> who observed abnormal transpulmonary pressure tracings (measured via an esophageal pressure transducer) in the presence of upper airway obstruction, which resolved following insertion of an endotracheal tube and

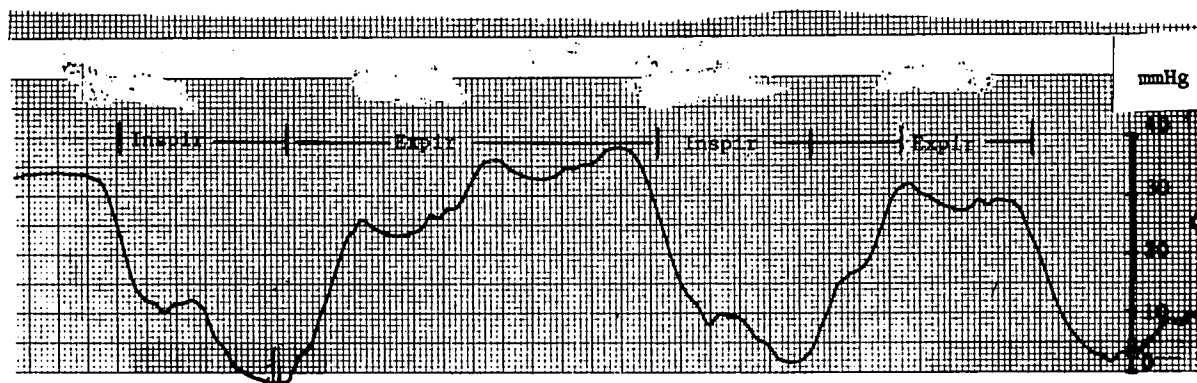


FIG. 2. Preinduction pulmonary artery occlusion pressure an abnormal elevation at end expiration.

relief of the obstruction. Our PAOP tracings before endotracheal intubation (fig. 2) are strikingly similar in configuration to the transpulmonary pressure tracings of Walsh *et al.*

Interestingly, Berryhill and Benumof<sup>6</sup> concluded from a study of dogs that spontaneous ventilation in compliant lungs afforded complete accuracy of the PAOP as a reflection of the left atrial pressure for values as high as 20 mmHg PEEP. This report of a spontaneously ventilating patient without extraneous PEEP having an end expiratory PAOP of 38 mmHg with no clinical signs of heart failure defied that conclusion.

Physiologically, the PAOP should not be higher than the mean PAP, especially with no cardiac failure. Hence, to explain the high PAOP we must assume that we are not reading a true PAOP. What could cause the high PAOP value? The dogs in the Berryhill and Benumof<sup>6</sup> study were ventilating spontaneously and had no upper airway obstruction but did have PEEP. Our patient had upper airway obstruction that caused a spontaneously generated expiratory PEEP. The pressure rise during late expiration in the PAOP tracing could result from over-wedging of the catheter, causing the PAOP tracing to calibrate via the flush valve with the pressure bag. With inspiration and loss of the spontaneously generated PEEP, the catheter occlusion resolved and the tracing returned to reading the true left atrial pressure.

A second abnormality, noted in figure 1, is pulmonary hypertension, the cause of which is uncertain. The history of cardiac disease, hypertension, and signs of mild right heart failure (two-pillow orthopnea, ankle edema, and shortness of breath) may suggest previous episodes of pulmonary hypertension. Hypoxia or hypercapnea secondary to airway obstruction or premedicative sedation might explain the increase in the PAP (however, the  $P_{aO_2}$  and the  $P_{aCO_2}$  were within normal limits before induction of anesthesia). The supine position in an obese patient may cause the pulmonary vascular resistance to increase 33%<sup>7</sup> and a relative hypervolemic hyperdynamic congestion of the pulmonary vasculature<sup>8</sup> to occur even in the absence of intrinsic cardiac disease. The positional change, we feel, best explains the increased pulmonary arterial pressures.

We did not diagnose upper respiratory obstruction before induction of the general anesthesia, although abnormal jerky respiration accompanied by grunting during expiration should have alerted us to this possibility. One should be aware of an increased risk of upper

airway obstruction in patients who present with 1) obesity (Eucapneic or Pickwickian), 2) enlarged tonsils or adenoids, 3) laryngeal or tracheal stenosis, 4) micrognathia, 5) arthritic involvement of the arytenoid cartilages, 6) heavy premedications and trauma to the upper airways, and 7) large jowls and a short neck with or without obesity.<sup>1,9,10</sup> If a high value is obtained for the pulmonary artery and wedge pressures in a patient presenting with any of these clinical conditions, a search for upper airway obstruction should be made. Simple maneuvers, such as extension of the jaw and neck, arousal of the patient, or insertion of an oral or nasal airway, may correct this respiratory obstruction, assuring a more accurate assessment of pulmonary artery and wedge pressures. Our experience underlines the necessity of proper diagnosis and management of upper airway obstruction before the measurement of the pulmonary artery and pulmonary wedge pressure measurements.

#### REFERENCES

1. Sackner MA, Landa J, Forrest T, Greenelch D: Periodic sleep apnea: Chronic sleep deprivation related to intermittent upper airway obstruction and central nervous system disturbance. *Chest* 67:164-171, 1975
2. Benumof JL, Saidman LJ, Arkin DB, Diamant M: Where pulmonary arterial catheters go: Intrathoracic distribution. *ANESTHESIOLOGY* 46:336-338, 1977
3. Kane PB, Askanazi J, Neville Jr. JF, Mon RL, Hanson EL, Webb WR: Artifacts in the measurement of the pulmonary artery wedge pressure. *Crit Care Med* 6:36-38, 1978
4. Pace NL: A critique of flow directed pulmonary arterial catheterization. *ANESTHESIOLOGY* 47:455-465, 1977
5. Walsh RE, Michaelson ED, Harkleroad LE, Zichelboim A, Sackner MA: Upper airway obstruction in obese patients with sleep disturbances and somnolence. *Ann Intern Med* 76:185-192, 1972
6. Berryhill RE, Benumof JL: PEEP-induced discrepancy between pulmonary arterial wedge pressure and left atrial pressure. (The effects of controlled vs. spontaneous ventilation and compliant vs. non-compliant lungs in the dog). *ANESTHESIOLOGY* 51:303-308, 1979
7. Paul DR, Hoyt JL, Boutros, AR: Cardiovascular and respiratory changes in response to change of posture in the very obese. *ANESTHESIOLOGY* 45:73-78, 1976
8. Kaltman AJ, Goldring RM: Role of circulatory congestion in the respiratory failure of obesity. *Am J Med* 60:645-653, 1976
9. Lyons HA: Another curse of Ondine. *Chest* 59:590-591, 1977
10. Sackner MA, Landa J, Forrest, Greenelch D: Periodic sleep apnea; chronic sleep deprivation related to intermittent upper airway obstruction and CNS disturbance. *Chest* 67:164-171, 1975