

Anesthesiology  
58:95-98, 1983

## Acute Bupivacaine Toxicity As a Result of Venous Leakage Under the Tourniquet Cuff during a Bier Block

PER H. ROSENBERG, M.D.,\* EIIJA A. KALSO, M.D.,† MARJATTA K. TUOMINEN, M.D.,‡  
HANS B. LINDÉN, M.D.§

Severe cardiovascular complications have been associated with regional anesthesia using the newer local anesthetics at clinical<sup>1</sup> or large doses.<sup>2</sup> Unintentional intravascular injection or rapid absorption has been considered responsible for these reactions. Lately, bupivacaine has become increasingly popular for the Bier block because it produces residual analgesia after the tourniquet is released.<sup>3,4</sup> A dose as high as 60 ml of 0.5% bupivacaine has been recommended,<sup>3</sup> although the use of 40–60 ml of 0.25% bupivacaine in adults has been considered sufficient and safe.<sup>5</sup> We have routinely used a 0.25% solution and a dose of approximately 1.8–2.0 mg/kg with satisfactory blocking results.<sup>6</sup>

Recently, we encountered a case of bupivacaine intoxication soon after the injection of the anesthetic. Because the tourniquet cuff appeared intact, we performed a tourniquet phlebography of the arm in this patient and six other subjects to see if local anesthetic was entering the general circulation.

### REPORT OF A CASE

A 71-year-old man (120 kg, 180 cm) was scheduled for excision of a Dupuytren's contracture. He was taking digoxin and pindolol because of atrial fibrillation. Arterial blood pressure was 160/80 mmHg the day before surgery. Diazepam, 20 mg, po, and meperidine, 80 mg, im, were given about 60 min prior to anesthesia. The arm was exsanguinated with an Esmarch bandage and the proximal of the two separate pneumatic cuffs (Kidde and Co., Warsaw, Indiana) was inflated to 300 mmHg. The circumference of the arm at the biceps region was about 42–44 cm, and the cuff was 7.5 cm wide and 65 cm long. After removal of the Esmarch bandage, iv regional anesthesia (IVRA) was performed by injecting 80 ml of 0.25% bupivacaine into a vein of the wrist in about 30 s. Arterial blood pressure recorded in the contralateral arm was 170–180/110 mmHg. After about two minutes after the injection of bupivacaine, the patient suddenly developed bradycardia and cyanosis, and lost consciousness (afterwards he recalled this as a feeling of having received general anesthesia).

\* Associate Professor of Anesthesiology.

† Resident in Anesthesiology.

‡ Assistant Professor of Anesthesiology.

§ Assistant Professor of Radiology.

Received from the Departments of Anesthesiology and Radiology, Surgical Hospital, Helsinki University Central Hospital, SF-00130 Helsinki 13, Finland. Accepted for publication July 13, 1982. Supported by The Sigrid Juselius Foundation, Finland.

Address reprint requests to Dr. Rosenberg.

Key words: Anesthetics, local: bupivacaine. Anesthetic techniques: intravenous; bier block. Complications: convulsions; anesthetic; cardiac.

Within a few seconds of these first symptoms, convulsions occurred. No arterial blood pressure readings could be obtained. Ventilation via a mask was controlled with a  $FI_{O_2}$  of 1.0, and thiopental (150 mg) and succinylcholine (150 mg) were given. The trachea was intubated and cardiovascular resuscitation instituted. During approximately 15 min of resuscitation, the iv medication that was given was: 0.5 mg adrenaline (given twice), 1.5 g calcium chloride, and 1 mg atropine. The total dose of sodium bicarbonate was 270 mEq, based on arterial blood-gas analysis 10 min ( $pH$  7.09,  $P_{CO_2}$  56 mmHg,  $P_{O_2}$  160 mmHg, BE  $-14.4$  mEq/l) and 25 min ( $pH$  7.19,  $P_{CO_2}$  45.8 mmHg,  $P_{O_2}$  106.8 mmHg, BE  $-11.1$  mEq/l) after the loss of consciousness. After the initial resuscitation the circulation was maintained with dopamine and nitroprusside infusions. The patient regained consciousness 30 min later, and the cardiovascular status returned to its preoperative level (atrial fibrillation). After 40 min, analysis of arterial blood gas was normal.

Ten, 25, and 40 min after the first observation of the toxic symptoms the arterial bupivacaine blood concentrations were 1.8  $\mu$ g/ml, 0.9  $\mu$ g/ml, and 0.58  $\mu$ g/ml, respectively (bupivacaine levels were determined by gas chromatography). The tourniquet, the cuff of which had remained inflated at 300 mmHg, was deflated after 55 min under thiopental (100 mg) anesthesia. One minute after the release, the bupivacaine concentration in the ipsilateral subclavian venous blood was 1.05  $\mu$ g/ml, and five min later the concentration was 0.65  $\mu$ g/ml. No convulsions or cardiac arrhythmias occurred at that time. The recovery was good and no signs of hypoxic organ damage were evident.

Two days later, phlebography of the same upper extremity was performed to visualize the assayed bupivacaine leakage. Informed consent of the patient was obtained. The arm was exsanguinated with an Esmarch bandage in the same way as for IVRA with a cuff pressure of 300 mmHg (arterial pressure 180/110 mmHg). Eighty milliliters of contrast medium (Urografin® 30%) were injected into a distal antebrachial vein in 30 s, and roentgenographs were taken every 15 s for 2 min, and then again after 5 min. Leakage of the contrast medium under the inflated cuff (the same as that used on the patient two days earlier) was seen in the first roentgenograms (fig. 1), and thereafter. The arterial blood pressure during the phlebography remained at 170–190/100–110 mmHg.

### STUDY SUBJECTS AND METHODS

In a previous study (performed about eight months earlier), we found measurable bupivacaine concentrations in the venous blood of some patients when the tourniquet cuff was still inflated, even though the exsanguination appeared adequate.<sup>6</sup> The three patients with the highest bupivacaine concentrations during the tourniquet inflation period (table 1) were asked to participate in a phlebographic examination to investigate possible venous leakage. In addition, three volunteers of normal build and arterial blood pressure (table 1) also were investigated. The build of the arm of the sub-

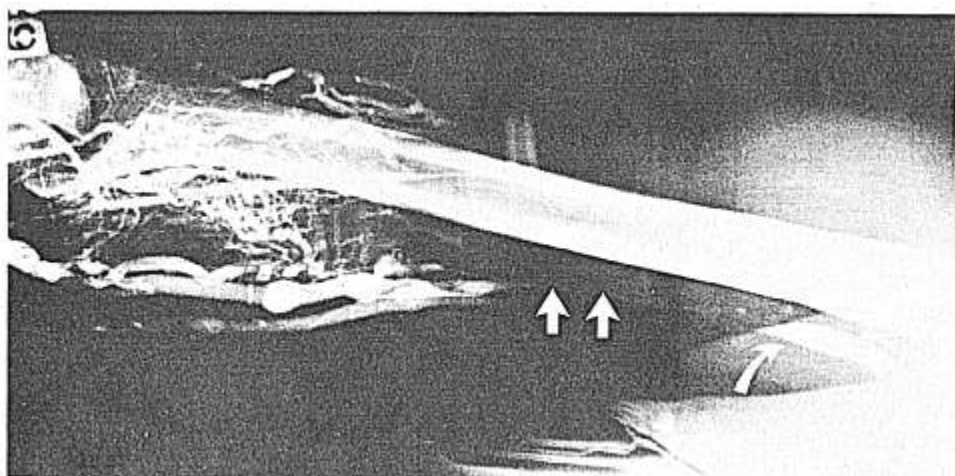


FIG. 1. Phlebography of the arm after injection of contrast medium into a peripheral vein of the exsanguinated extremity. The tourniquet cuff pressure was 300 mmHg; this was the same as when this patient was given an IVRA with complications. Note the filled axillary vein on the proximal side of the cuff area (to the right, curved arrow) and a continuous narrow contrast medium streak on the medial side of the humerus (two straight arrows).

jects was considered proportional to their body build (table 1).

A vein of the dorsum of the hand or wrist was cannulated and exsanguination was achieved with an Es-march bandage. The cuff pressure was the same as in the earlier IVRA for the three patients, and 250 or 300 mmHg in the volunteers (table 1). Instead of local anesthetic, an equivalent volume (50 or 60 ml) of contrast medium (Urografin®) was injected rapidly (in 15–20 s), and roentgenographs were taken as described above in the case report. The arterial pressure was recorded at 1-min intervals. In volunteers 1 and 2, the phlebographic study was repeated about a week later with a similar technique, except a slower injection at a speed of 1 ml/s was given.

This study was approved by the ethical committee of the Surgical Hospital, Helsinki University Central Hos-pital.

## RESULTS

In two of the patients, contrast medium was seen on the proximal side of the cuff as soon as 15 s after the injection. The filling of a short distance of some of the larger veins on the proximal side did not change during the 5-min examination, and no indications of open veins under the cuff could be seen. In the third patient (number 3) no contrast medium passed the tourniquet cuff (fig. 2). However, in two of the three volunteers (anesthesiologists), contrast medium leakage was observed at a cuff pressure of 250 mmHg. In the female volunteer some very narrow streaks of contrast medium were visible on the roentgenograms, from 15 s to 5 min, and the larger veins were filled on the proximal side of the cuff (fig. 3). The tourniquet cuff pressure appeared to be sufficient to block the arterial inflow, however, as the pale skin color remained unchanged during the study.

TABLE 1. Characteristics and Arterial Blood Pressures of the Patients and Volunteers during Previous IVRA and Present Phlebography of the Arm. Volume and Leakage of Contrast Medium Also Are Indicated

	Sex	Age	Weight (kg)	Height (cm)	Arterial Blood Pressure (mmHg)				Cuff pressure (mmHg)	Contrast Medium		Bupivacaine concentration (µg/ml)
					IVRA Preanesthesia	Phlebography				Volume (ml)	Leakage (+ or -)	
						Pre-examination	Maximum pressure	Post-examination				
Patients												
1	M	52	86	178	160/115	190/110	220/150	180/115	300	60 (60)*	+†	0.89‡
2	M	44	84	166	110/90	140/110	160/120	150/110	250	60 (60)	+	0.86
3	M	29	71	173	120/80	140/90	160/110	140/100	250	60 (50)	—	0.41
Volunteers												
1	F	27	60	163		140/90	150/100		250	50	+	
2	M	28	55	180		150/80	160/100		250	50	+	
3	M	37	77	185		125/75	140/90		300	60	—	

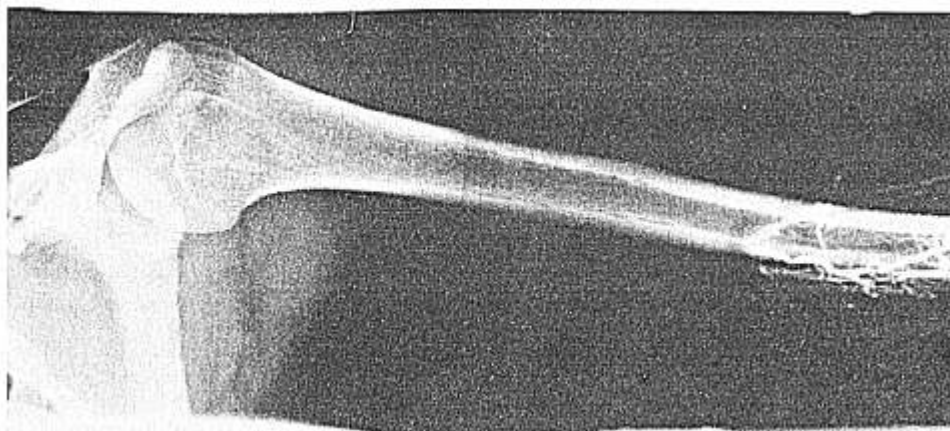\* Volume of 0.25% bupivacaine used for the preceding IVRA is in brackets.

† + = leakage of contrast medium under the cuff; - = no leakage

of contrast medium.

‡ Concentration of bupivacaine in venous blood during the preceding IVRA.

FIG. 2. Phlebography of the upper extremity of a patient (number 3) who in an earlier IVRA had bupivacaine in the circulation when the tourniquet was inflated. During the 5-min observation there was no contrast medium passing under the cuff.



Although the arterial blood pressure tended to rise during the ischemia in almost all the study subjects, the cuff pressure remained at least 80 mmHg above the systolic arterial blood pressure in each case.

In the second phlebography of the same arm in the male volunteer (number 2) with contrast medium leakage, the slower injection (1 ml/s) of 50 ml resulted in no leakage under the cuff. However, in the female volunteer, there was contrast medium leakage also when the injection was slow. This was visible from as early as 45 s, *i.e.*, before finishing the injection.

#### DISCUSSION

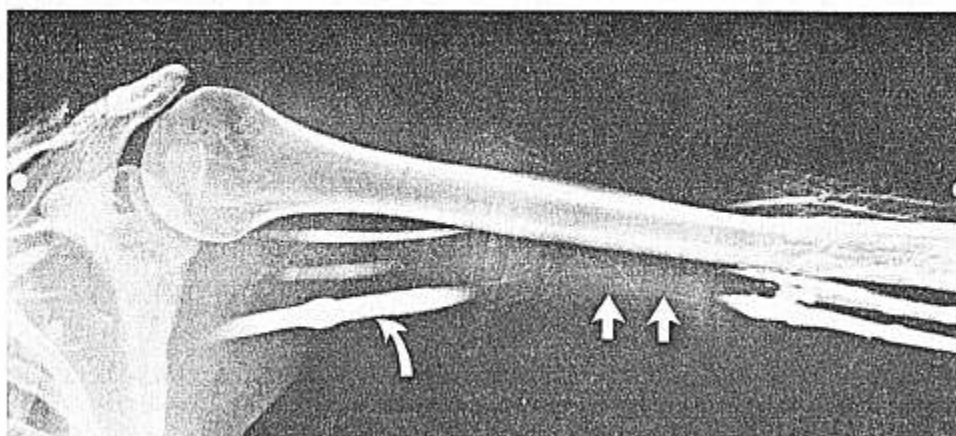
A tourniquet cuff pressure of 100–150 mmHg above the preanesthetic systolic arterial blood pressure has been recommended for IVRA.<sup>7</sup> However, with our case, a significant leakage of bupivacaine and contrast medium took place despite the appropriate pressure in the proximal cuff. Two single pneumatic cuffs (length 65 cm, width 7.5 cm) were applied, but the patient's arm size may have been too large to allow total compression to all the veins. The major arteries, however,

seemed occluded until deflation of the cuff. The arm size alone was not the only decisive factor, as contrast medium was seen under the cuff (250 mmHg) in the female volunteer, who was regarded as a normal non-athletic female with a normal arterial blood pressure.

In our case, the amount of bupivacaine was 200 mg, *i.e.*, clearly below the recommended maximum IVRA dose of 300 mg.<sup>8</sup> However, the volume of 80 ml of the injected fluids may have been too large, even considering the great size of the patient. Bupivacaine, 0.25% solutions, 1.5 mg/kg<sup>5</sup> and 1.8–2.0 mg/kg,<sup>6</sup> or 0.5% solutions, 50–60 ml<sup>3,8</sup> have been employed, although it has been estimated that 20 to 50 ml would suffice to fill the venous channels of the arm.<sup>9</sup>

All the venous cannulas were inserted into distal veins, at the dorsum of the hand or wrist of the study subjects. Leakage under the cuff was not related to injection from either site. The use of more proximal veins, *e.g.*, cubital veins, may result in venous pressures in the range of 250 to 300 mmHg,<sup>8,10</sup> and these veins therefore are not recommended for IVRA. We did not record the injection pressure in the study subjects. How-

FIG. 3. Phlebography of the upper extremity of a female anesthetist. The tourniquet cuff pressure was 250 mmHg, and 50 ml of contrast medium was injected. The proximal axillar veins were filled with contrast medium already in the first roentgenogram (15 s) (curved arrow). The two straight arrows indicate the continuous narrow contrast medium streak under the cuff.



ever, in one volunteer (number 2), application of two speeds of injection showed that a rapid injection, (50 ml in approximately 20 s) of contrast medium opened the veins compressed by the cuff. Interestingly, in the female volunteer (number 1) there was leakage of the contrast medium also at an injection speed of 1 ml/s.

The pressure at injection, also influenced by the efficacy of venous valves, is probably the main reason for contrast medium leakage in this study, and perhaps also for the observed bupivacaine blood concentrations during tourniquet cuff inflation in our former study.<sup>6</sup> Similar regularly checked equipment was utilized in the former IVRA study where ten of 40 patients had venous bupivacaine concentrations exceeding 0.05 µg/ml during the ischemic period.<sup>6</sup>

In two of the three patients with the highest concentrations, contrast medium also passed under the cuff immediately after finishing the injection. Other investigators have not reported significant concentrations of local anesthetics prior to cuff release. Tucker and Boas<sup>11</sup> found only negligible lidocaine plasma concentrations when 3 mg/kg 0.5 or 1% lidocaine had been utilized for the IVRA. Their injected volumes were lower than those given by us, but whether the difference in the observed local anesthetic concentrations is related only to the volumes of the local anesthetic solutions remains speculative.

Although the arterial bupivacaine blood concentration measured first (1.8 µg/ml) was below the level considered toxic (4–5 µg/ml),<sup>12,13</sup> at the time of the symptoms (10 min earlier) the blood level was obviously higher and probably toxic. Despite a marked acidosis, which may enhance the toxicity of bupivacaine,<sup>14</sup> the cardiopulmonary resuscitation was successful. The bupivacaine concentration in the ipsilateral subclavian vein increased again after cuff deflation, 55 min after the intravenous injection. However, the concentration remained nontoxic due to the earlier escape of a significant fraction of the dose, and possible enhanced tissue binding of bupivacaine in the ischemic limb.<sup>15</sup>

We conclude that not even a tourniquet cuff pressure 110 mmHg above the preanesthetic arterial systolic blood pressure prevented venous leakage under the cuff. This leakage of local anesthetic into the general circulation probably results from the initial high pres-

sure distal to the cuff. The risk may be greater in very large patients, in whom the venous compression by the cuff may be insufficient by using standard equipment and pressure. To prevent toxic reactions from bupivacaine in the IVRA or Bier block, the technique should include appropriate equipment, a slow injection from a distal vein, a restricted volume, and close observation of the patient.

## REFERENCES

1. Albright GA: Cardiac arrest following regional anesthesia with etidocaine or bupivacaine. *ANESTHESIOLOGY* 51:285–287, 1979
2. Davis NL, de Jong RH: Successful resuscitation following massive bupivacaine overdose. *Anesth Analg (Cleve)* 61:62–64, 1982
3. Magora F, Stern L, Zylber-Katz E, Olshwang D, Donchin Y, Magora A: Prolonged effect of bupivacaine hydrochloride after cuff release in i.v. regional anesthesia. *Br J Anaesth* 52:1131–1135, 1980
4. Gooding JM, Tavakoli MM, Fitzpatrick WO, Bagley JN: Bupivacaine: Preferred agent for intravenous regional anesthesia? *South Med J* 74:1282–1283, 1981
5. Ware RJ: Intravenous regional analgesia using bupivacaine. *Anaesthesia* 34:231–235, 1979
6. Kalso E, Tuominen M, Rosenberg PH, Alila A: Bupivacaine blood levels after intravenous regional anesthesia of the arm. *Regional Anaesthesia* 5:81–84, 1982
7. Thorn-Alquist A-M: Intravenous regional anesthesia, Illustrated Handbook in Local Anesthesia, second edition. Edited by Eriksson E. Philadelphia, WB Saunders, 1980, pp 47–48
8. Stark RA: A review of intravenous regional anesthesia. *Anesthesiology Review* IX:15–24, 1982
9. Adams JP, Dealy EJ, Kenmore PI: Intravenous regional anesthesia in hand surgery. *J Bone Joint Surg* 46A:811–816, 1964
10. Raj PP, Garcia CE, Burleson JW, Jenkins MT: The site of action of intravenous regional anesthesia. *Anesth Analg (Cleve)* 51:776–786, 1972
11. Tucker GT, Boas RA: Pharmacokinetic aspects of intravenous regional anesthesia. *ANESTHESIOLOGY* 34:538–549, 1971
12. Moore DC, Mather LE, Bridenbaugh LD, et al: Bupivacaine (Marcaine®): An evaluation of its tissue and systemic toxicity in humans. *Acta Anaesth Scand* 21:109–121, 1977
13. Foldes FF, Molloy R, McNall PG, Koukal LR: Comparison of toxicity of intravenously given local anesthetic agents in man. *JAMA* 172:1493–1498, 1960
14. Moore DC, Thompson GE, Crawford RD: Long-acting local anesthetic drugs and convulsions with hypoxia and acidosis. *ANESTHESIOLOGY* 56:230–232, 1982
15. Déry R, Pelletier J, Jacques A, Clavet M, Houde JJ: Metabolic changes induced in the limb during tourniquet ischaemia. *Can Anaesth Soc J* 12:367–377, 1965