

Heparin-Lock for Repeated Anesthesia in Pediatric Radiation Therapy

ALEXANDER RODARTE, M.D.*

Sedation or anesthesia is often required for pediatric patients undergoing daily radiation therapy. The patient must remain motionless while the radiation field is being prepared and the radiation is being delivered. The use of restraints is inadequate to allow the precision required to deliver the radiation to the appropriate field. Other methods used have included the use of inhaled anesthetics with or without endotracheal intubation, oral sedative or hypnotic drugs, rectal barbiturate, and intramuscular methohexital or ketamine.¹⁻³ The use of an indwelling intravenous catheter with a heparin-lock for repeated intravenous injections avoids many of the problems associated with some of the above techniques.

TECHNIQUE

On Monday morning, or the first day of treatment, patients without increased intracranial pressure are given 5-10 mg/kg ketamine with 0.02 mg/kg atropine, intramuscularly for induction of anesthesia. If increased intracranial pressure is present or suspected, 20 mg/kg rectal methohexital is given. While the patient is anesthetized and the technicians are preparing the radiation field, a 22- or 24-gauge Quick-Cath† is inserted with aseptic technique and taped securely. A t-piece connector‡ with an injection cap§ is attached to the cannula (fig. 1). Since the dorsum of the hand is usually used, the hand is taped to an armboard and wrapped with kurlex. If additional medication is needed during the initial treatment, it can be administered intravenously. At the end of the procedure, the t-piece connector is flushed from the tail with 1 ml of heparinized saline preserved with benzyl alcohol. The benzyl alcohol may discourage the colonization of the heparin-lock with bacteria.⁴ The usual concentration of heparin is 50 units/ml. The parent is instructed to flush the heparin-lock

aseptically with the same solution three to four times a day using a schedule that is convenient for the parent.

Induction of anesthesia on the following days can be accomplished atraumatically, since the cannula is already in place. The cannula is tested with the injection of a small volume of sodium chloride to determine patency and to prevent injection of the anesthetic agent subcutaneously if the cannula should be infiltrated. To keep the number of needle insertions to a minimum, and presumably decrease the chance of bacterial contamination, the needle of the syringe containing the anesthetic is inserted into the tail of the t-piece connector and the syringe taped to the arm. The amount of rug drawn into the syringe is limited to a dose that may cause respiratory depression if inadvertently administered as a bolus, but which presumably would not be large enough to cause cardiovascular collapse. The particular anesthetic agent utilized is left to the preference of the anesthesiologist. Agents we have used include thiopental, methohexital, and ketamine.

As with any anesthetic administration, resuscitation drugs and equipment for airway management including oxygen and suction are always available. Monitoring equipment available includes an ECG and blood pressure cuff. Immediately after induction, a blood pressure cuff and ECG leads are applied, but most importantly, adequate ventilation is monitored by observing chest movement and listening and feeling over the mouth and nose to confirm the exhalation of air. During the actual radiation of the patient, movement of the chest is monitored via closed circuit television.

With proper titration of the anesthetic, the patient usually awakens with the stimulation of being moved from the table. If the patient is not fully awake, or if there has been any problems during the procedure, the patient is sent to the recovery room. The heparin-lock is discontinued on the last treatment day of the week, so as to decrease the chance of infection and to allow full use of the extremity.

RESULTS

Five patients, 10-16 kg in weight, and 1-3 years of age, have been treated with the above technique for a total of 108 anesthetic administrations. Although there have been no infections, one child had a small superficial area of necrosis following the injection of thiopental into

* Assistant Professor of Pediatrics and Anesthesia.

† Injection Cap, Benton Dickinson.

‡ Quik-Cath, Vicra, Division of Travenol Laboratories, Inc.

§ Extension Set with "T", Abbott.

Received from the Stanford University School of Medicine, Stanford, California 94305. Accepted for publication September 22, 1981.

Address reprint requests to Dr. Rodarte: Department of Anesthesiology and Pediatrics, Stanford University Medical Center, Stanford California 94305.

Key words: Anesthesia: outpatient; radiation therapy. Anesthetics, intravenous. Equipment: catheters, venous, heparin-lock.

a partially infiltrated catheter. This lesion healed completely without further complication. Parents and radiation therapists have overwhelmingly preferred the intravenous technique to the intramuscular administration of anesthetics.

DISCUSSION

General endotracheal anesthesia has been proposed as a viable technique for these patients. However, the risk of repeated endotracheal intubation, the use of volatile agents in areas of the hospital not equipped with scavenging systems, the risk of increased intracranial pressure, and the whole production aspect of general anesthesia for a short 5- to 10-min, painless procedure makes this technique less than appealing. The use of oral or rectal agents is quite unreliable and can often cause long delays in the radiation therapy schedule. The use of intramuscular methohexital is more reliable, but the injections are quite painful. Intramuscular ketamine is somewhat painful but very reliable and usually provides a good airway. Since ketamine causes an increase in cerebral blood flow and volume, its use would be contraindicated in patients with suspected increased intracranial pressure.⁵ Another drawback to the use of ketamine intramuscularly is that some patients may require recovery room care for up to two to three hours and may remain ataxic for even longer periods.

The heparin-lock technique has the advantage of a very rapid induction which is of enormous value to the efficiency of a busy radiation therapy unit. The anesthetic administered can be tailored to the length of the procedure, thus eliminating long recovery time for very short procedures, or, equally annoying, the problem of a patient waking before the procedure is completed. These advantages are inherent in the intravenous technique itself and not especially dependent on the particular anesthetic drug chosen. The more rapid uptake with intravenous administration allows a much smaller cumulative dose, and hence, shorter recovery time, than if the anesthetic had been administered enterally or intramuscularly. Since only one needle insertion occurs per week, there is decreased psychic trauma to both the patients and their parents. Though most outpatients do not require intravenous fluids, the option to rehydrate patients with nausea and vomiting is easily available. The last advantage is that patients who are concomitantly receiving chemotherapy can receive their chemotherapeutic drugs through the heparin-lock.

The disadvantages to the heparin-lock technique are

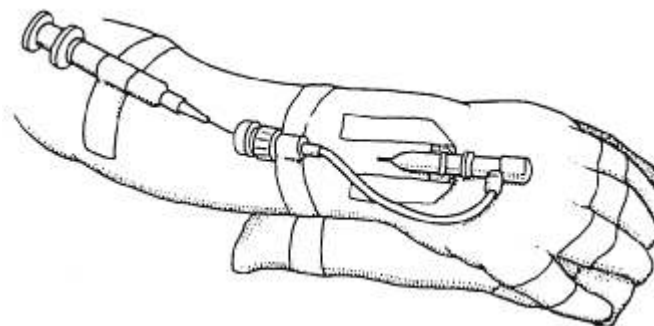


FIG. 1. Cannula taped in position with "T"-connector and injection cap. Syringe taped alongside arm to allow multiple injections without repeated insertion of the needle.

the requirement for venous cannulation, which may be difficult; the small risk of serious infection⁴⁻⁶; and the risk of inadvertent subcutaneous injection. Most anesthesiologists can overcome the first problem, especially with the use of a 24-gauge catheter. The second problem can be lessened by conscientious aseptic technique by parent and anesthesiologist. We believe the intravenous insertion site should be prepped with betadine and strict asepsis maintained throughout the placement of the catheter. Parents should be instructed to discontinue the heparin-lock at the first sign of fever, inordinate pain on flushing the heparin-lock, erythema at the insertion site, or any evidence of phlebitis or lymphangitis. The catheter probably should be discontinued upon completion of the radiation therapy for the week since it would not be used for a 72-hour period but would continue to increase the risk of infection. The last disadvantage of the technique should be avoided if the catheter can be flushed easily with normal saline before medication is given.

Though inserting a heparin-lock weekly is not without its disadvantages, the convenience to the patient, parent, radiation therapist, and anesthesiologist warrants the further evaluation of this technique.

REFERENCES

1. Fabian LW: The experts opine. *Surv Anesth* 24:121-126, 1980
2. Miller JR, Stoelting VK: A preliminary communication on the sleep-producing effect of intramuscular methohexitone sodium in the pediatric patient. *Br J Anaesth* 35:48-50, 1963
3. Bennett JA, Bullmere JA: The use of ketamine hydrochloride anesthesia for radiotherapy in young children. *Br J Anaesth* 45:197-201, 1973
4. Ferguson RL, Rosett W, Hodges GR, et al: Complications with heparin-lock needles. *Ann Intern Med* 85:583-586, 1976
5. Wyte SR, Shapiro MM, Turner P, et al: Ketamine-induced intracranial hypertension. *ANESTHESIOLOGY* 136:174-176, 1972
6. Agger WA, Maki DG: Septicemia from heparin lock needles. *Ann Intern Med* 86:(S)657, 1977