

## Position-Induced Horner's Syndrome

TODD B. JAFFE, M.D.,\* AND CHARLES H. MCLESKEY, M.D.,†

Horner's syndrome has been reported as a complication following a variety of regional anesthetic procedures including interscalene block,<sup>1</sup> lumbar epidural block,<sup>2</sup> and caudal block.<sup>3</sup> It also has been associated with intraoral anesthetic injections<sup>4</sup> and following percutaneous catheterization of the internal jugular vein.<sup>5</sup> We describe transient postoperative unilateral Horner's syndrome in a patient maintained intraoperatively in the left kidney position.

## REPORT OF A CASE

A 71-year-old woman was scheduled for elective left nephrolithotomy. Past history was unremarkable except for nephrolithiasis. Physical examination, including a brief neurologic examination, was normal. Results of urinalysis and laboratory tests were within normal limits. Electrocardiogram revealed normal sinus rhythm with non-specific S-T, T-wave changes.

Ninety minutes following administration of lorazepam, 2 mg, po, the patient was brought to the operating room. In addition to routine monitoring, arterial blood pressure was monitored via a catheter inserted percutaneously into the right radial artery. A central venous pressure catheter was inserted percutaneously via the left external jugular vein using a j-wire technique. This was accomplished without difficulty utilizing a 16-gauge needle which at no time passed deep to the external jugular vein. The catheter was taped in place without the use of an occlusive dressing.

Anesthesia was induced with fentanyl, 200 µg, iv, and thiopental, 250 mg, iv. Pancuronium, 7 mg, iv, facilitated endotracheal intubation and anesthesia was maintained with halothane and nitrous oxide. Ventilation was controlled using a volume ventilator.

For surgical exposure of the left kidney, the patient was first placed in the right lateral decubital position with an axillary roll positioned under the dependent right axilla. The kidney rest, located one inch cephalad to the iliac crest, was elevated and the table was flexed. The arms and all pressure points were carefully padded. The dependent (right) arm was supported by an arm board, and the non-dependent (left) arm was supported by a separate universal arm board. The head was supported by folded sheets and a foam head rest in order to avoid pressure to the eyes and dependent ear and to achieve alignment of thoracic and cervical vertebrae.

\* Resident.

† Assistant Professor

Received from the Department of Anesthesia, Bowman Gray School of Medicine, Wake Forest University, Winston-Salem, North Carolina. Accepted for publication July 1, 1981. Work was done at North Carolina Baptist Hospital without grant support.

Address reprint requests to Dr. Jaffe: Department of Anesthesia, Bowman Gray School of Medicine, 300 S. Hawthorne Road, Winston-Salem, North Carolina 27103.

Key words: Complication: neuropathy. Position: nerve damage. Sympathetic nervous system: Horner's syndrome.

Following an uneventful 6-h intraoperative course, the patient was again turned to the supine position, and the trachea was extubated. On the first postoperative day, the patient had ptosis, miosis, and conjunctival injection of the left, previously non-dependent eye. The patient also complained of nasal stuffiness of the left side. There was no evidence of brachial plexus dysfunction. The symptoms resolved spontaneously over a 3-day period.

## DISCUSSION

Sympathetic innervation of the head arises from the superior cervical ganglion. This ganglion is the largest of the cervical ganglia and is located in connective tissue between the carotid sheath and the prevertebral fascia. Horner's syndrome results from interruption of sympathetic nervous innervation to the head. Classically, the components of this syndrome include miosis, enophthalmos, and ptosis. In addition, other features have been described, such as anhidrosis, nasal stuffiness, and conjunctival and facial flushing of the affected side(s). Miosis occurs secondary to interruption of efferent sympathetic fibers to the pupillary dilator muscle. Also, as a result of unopposed parasympathetic input, the blood vessels of the ipsilateral conjunctiva, nasal mucosa, and face become dilated. Sweating cannot occur and the superior palpebral muscle, innervated partly by sympathetic nerve fibers, in addition to a contribution by the facial nerve, has less resting tone, resulting in ptosis.

Horner's syndrome occurring as a complication of regional anesthesia of the head and neck usually results from unwanted spread of the local anesthetic solution or from direct needle trauma to the cervical sympathetic chain. The proposed mechanism for Horner's syndrome resulting from internal jugular vein catheterization is direct trauma to the sympathetic nerves or ganglia. Recently, the syndrome has been described as a complication of cerebral angiography,<sup>6</sup> believed to have resulted from an ischemic insult to the sympathetic nerves of the head and neck.

In the described case, it is believed transient postoperative Horner's syndrome most likely resulted from the prolonged, exaggerated intraoperative lateral flexion position. Patient positioning has been implicated as a cause for postoperative cervical sympathetic nerve dysfunction only once previously.<sup>7</sup> Exaggerated positioning may have caused stretch and secondary ischemia of the cervical sympathetic chain in our patient and the one described

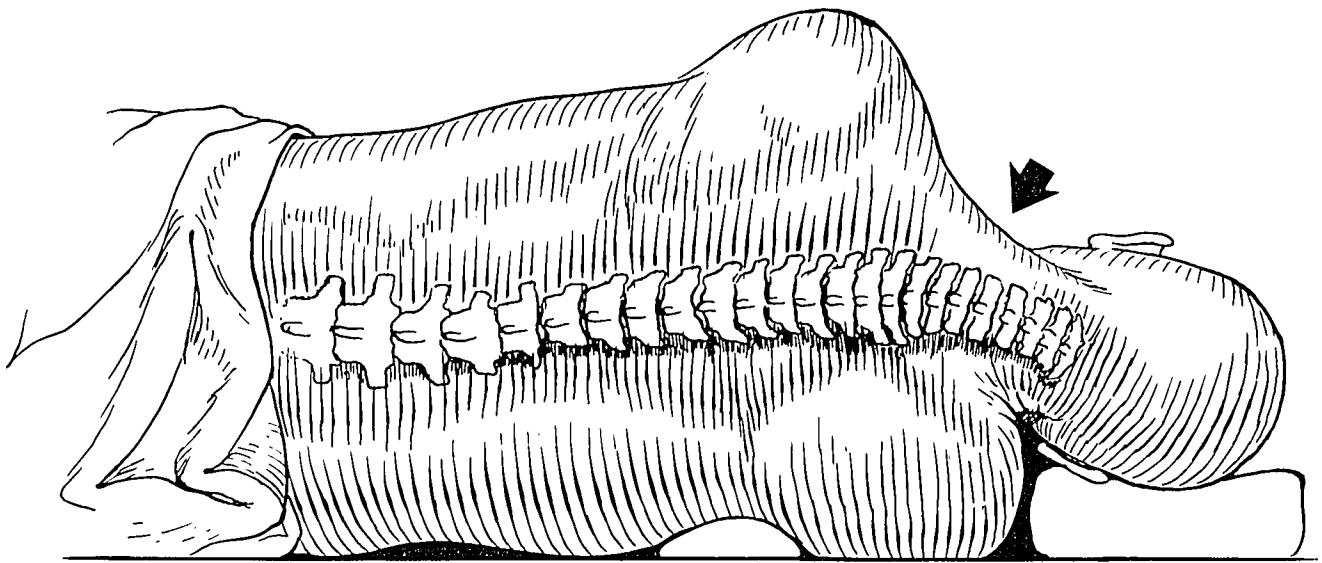


FIG. 1. Schematic diagram of the cervical and thoracic vertebrae in a patient placed in lateral position. As illustrated, inadequate support of the head produces misalignment of cervical and thoracic vertebrae (arrow).

by Gerber and Maar, resulting in transient, postoperative dysfunction of the sympathetic nerves of the head. Although an attempt was made in our patient intraoperatively to align the thoracic and cervical vertebrae by supporting the head, perfect alignment may not have been achieved. In light of the patient's age and probable cervical vertebral spurring, slight stretch of the non-dependent sympathetic chain may have occurred as a result of inadequate head support, in spite of no obvious misalignment of the cervical and thoracic vertebrae (fig. 1). Maintenance of this unphysiologic position for the 6-h surgical procedure may have resulted in hypoperfusion of the neuronal structures and transient, postoperative signs of Horner's syndrome.

The concept of cervical sympathetic nerve stretch as the cause for postoperative neuronal dysfunction in our patient is further strengthened by the work of Nicholson and McAlpine<sup>8</sup> who described three degrees of neurologic conduction impairment secondary to pressure or stretch of a nerve. These degrees of neurologic conduction defect are: 1) initial paralysis with immediate recovery; 2) paralysis with recovery in 1 to 19 days; and 3) paralysis with degeneration of the nerve. Anatomically, mild stretch results in damage to epineural vessels with resultant patches of ischemic changes in the nerve fibers. Severe stretch ruptures the perineurium with herniation

of the nerve bundles resulting in pseudoneuroma formation and more prolonged and severe sequelae. The 3-day time course for complete neurologic recovery in our patient is consistent with the second degree of injury described above, probably resulting from mild neuronal stretch. Thus, this case emphasizes the need for strict attention to cervical and thoracic spine alignment in patients who are placed in the lateral position.

#### REFERENCES

1. Seltzer JL: Hoarseness and Horner's syndrome after interscalene brachial plexus block. *Anesth Analg (Cleve)* 56:585-586, 1977
2. Skaredoff MN, Datta S: Horner's syndrome during epidural anaesthesia for elective caesarian section. *Can Anaesth Soc J* 28:82-85, 1981
3. Kepes ER, Martinez LR, Pantuck E, et al: Horner's syndrome following caudal anesthesia. *NY State J Med* 72:946-947, 1972
4. Campbell RL, Mercuri LG, Sickels JV: Cervical sympathetic block following intraoral local anesthesia. *Oral Surg, Oral Med, Oral Pathol* 47:223-226, 1979
5. Parikh RK: Horner's syndrome case report. *Anaesthesia* 27:327-329, 1972
6. Raskind R, Weiss SR, Wermuth R, et al: Complications of cerebral angiography. *J Angiol* 21:447-450, 1970
7. Gerber H, Maar K: Horner syndrome. *Anaesthetist* 26:357-358, 1977
8. Nicholson MJ, McAlpine FS: Neural injuries associated with surgical positions and operations, *Positioning in Anesthesia and Surgery*. Edited by Martin JT. Philadelphia, WB Saunders, 1978, pp 213-216