

TABLE 1. Effects of Gastroplasty-induced Weight Loss on Arterial Oxygenation in Selected Patients

Patient	Age	Ideal Weight (kg)	(Per cent Predicted)											
			Weight (kg)		Pa <sub>O<sub>2</sub></sub> (torr)		Pa <sub>CO<sub>2</sub></sub> (torr)		FVC		FRC		MVV	
			Before	After	Before	After	Before	After	Before	After	Before	After	Before	After
1	30	61	127	110	43	72	68	49	48	62	—	—	58	38
2	56	69	140	85	59	70	47	38	56	89	67	88	73	93
3	44	60	140	85	44	79	46	42	73	99	47	77	62	91
4*	30	90	264	200	38	65	57	35	40	74	—	—	31	62
5†	30	85	172	104	58	65	42	35	76	89	34	72	63	62
MEAN			169	117‡	48	70‡	52	40‡	59	83‡			57	69
SD			±48	±56	±6	±10	±11	±6	±16	±15			±16	±23

\* Combined obesity hypoventilation syndrome and sleep apnea syndrome.

† Sleep apnea syndrome.  
‡ P < 0.05.

well and, on the average, were able to be weaned from mechanical ventilation and extubated on the third post-operative day. A significant improvement in Pa<sub>O<sub>2</sub></sub>, Pa<sub>CO<sub>2</sub></sub>, and FVC was seen in each of these patients (table 1). An increased functional residual capacity (FRC) was noted in each of the three patients in whom it was measured before and after weight loss. The MVV rose in three of the five patients.

In those patients who have significantly impaired ventilatory function associated with obesity, a marked improvement in forced vital capacity, functional residual capacity, and arterial blood gases can be expected following massive weight loss after gastroplasty. Furthermore, resolution of obstructive sleep apneas following weight loss will permit closure of a tracheostomy initially required to relieve obesity-induced upper airway obstruction.

HARVEY J. SUGERMAN, M.D. F.A.C.S.  
*Assistant Professor of Surgery*  
*Department of Surgery*

R. PAUL FAIRMAN, M.D.  
*Assistant Professor of Medicine*  
*Pulmonary Division*  
*Medical College of Virginia*  
*Richmond, Virginia 23298*

REFERENCES

1. Vaughan RW, Cork RC, Hollander D: The effect of massive weight loss on arterial oxygenation and pulmonary function tests. *ANESTHESIOLOGY* 54:325-328, 1981
2. Sugerman HJ, Fairman RP, Lindeman AK, et al: Gastroplasty for respiratory insufficiency of obesity. *Ann Surg* 193:677-685, 1981

Accepted for publication May 15, 1981.

Use of a Flexible, Radiopaque Directable Catheter for Difficult Tracheal Intubations

*To the Editor:*—A variety of methods for managing the technically difficult endotracheal intubation have been described.<sup>1,2,\*</sup> We wish to report another method of facilitating endotracheal intubation, which has proven to be successful when other maneuvers have failed. The technique makes use of a flexible, radiopaque, directable catheter inserted into the trachea under fluoroscopic control, in the spontaneously breathing patient.

In the radiology suite, a lubricated endotracheal tube of proper size is inserted through the nose and advanced

into the posterior oropharynx in the usual manner. A flexible 65-cm steerable catheter with attached Mediatech SH-4 control handle (7 French)† is then passed through the endotracheal tube. Under fluoroscopic visualization of the airway in the lateral projection, the catheter is advanced past the epiglottis and into the larynx with steering of the catheter as necessary (fig. 1). An anterior-posterior fluoroscopic projection is occasionally necessary if difficulty is encountered while advancing the catheter, due to lateral deviation of the tip into the pyriform recess. Upon directing the patient to suppress

\* Donlon J: Anesthetic management of patients with compromised airways. *Anesthesiology Review* 7:22-31, 1980.

† Mediatech, Incorporated, Watertown, Massachusetts.

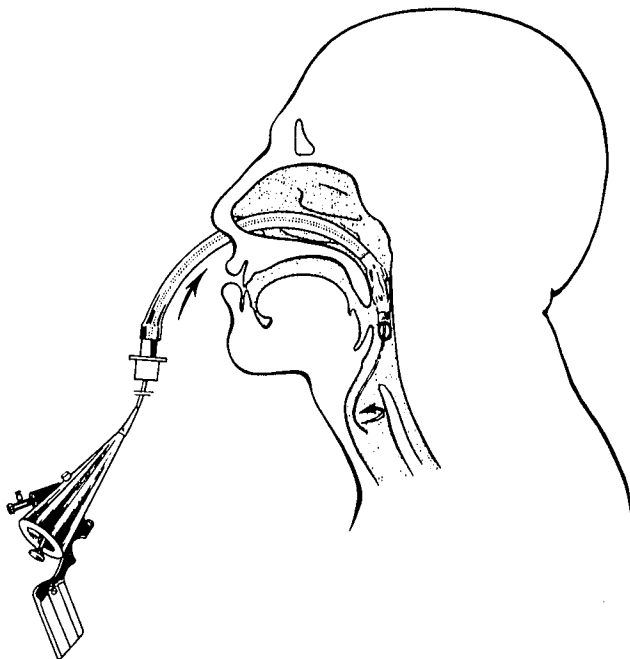


FIG. 1. Steerable catheter is advanced into the fluoroscopically visible trachea via the endotracheal tube lumen.

his cough and breathe slowly and deeply, the catheter is advanced into the fluoroscopically visible trachea. The endotracheal tube is gently advanced over the catheter, which is then removed. The patient is then immediately transported to the operating room and anesthesia induced in the usual manner.

This technique has proven successful in all cases wherein it has been employed, despite the presence of significant oropharyngeal hemorrhage, cervical spine im-

mobility or airway edema. The procedure has been found to be simple, quick, and well-tolerated in mildly sedated patients, even those in whom endotracheal intubation using a variety of other maneuvers proved impossible. There has been no associated morbidity.

We now electively use this method when preoperative examination reveals technically difficult intubation to be likely, as in cases of upper airway mass, cervical spine, or mandibular immobility. The small size of the catheter enables its application with larger pediatric as well as double lumen endotracheal tubes. The generally widespread availability of this catheter, and its skilled use by radiologists in a variety of fluoroscopic procedures, make this technique worthy of consideration to facilitate otherwise difficult endotracheal intubation.

A. J. DAVIDSON, M.D.  
*Resident in Training (Anesthesiology)*

A. C. REYNOLDS, M.D.  
*Assistant Professor (Anesthesiology)*

E. T. STEWART, M.D.  
*Professor (Radiology)*

*Departments of Anesthesiology and Radiology  
Medical College of Wisconsin  
Milwaukee, Wisconsin 53226*

#### REFERENCES

1. Gordon R: Anesthetic management of patients with airway problems. *Int Anesthesiol Clin* 10:37-59, 1972
2. Raj P, Forestner J, Watson T, et al: Techniques for fiberoptic laryngoscopy in anesthesia. *Anesth Analg (Cleve)* 53:708-714, 1974

*(Accepted for publication May 29, 1981.)*

### Emergency Transtracheal Ventilation

*To the Editor:*—A patient in our hospital with a massive tumor of the pharynx had acute upper airway obstruction during an attempted emergency tracheostomy. The anesthesiologists involved were able to ventilate the patient adequately until completion of tracheostomy by means of intermittent transtracheal injection of oxygen. Although the concept of emergency transtracheal ventilation by means of needles or catheters is well estab-

lished,<sup>1-3</sup> connection of a tracheal device to a controllable source of oxygen can be difficult or time consuming.

We have devised a tubing set which fits directly to an anesthesia machine. One end of a six-foot length of thick-walled, transparent plastic tubing is secured to Becton-Dickinson® catheter tip (#3092) and male Luer-lok (#3114) adapters. The other end is pressed over a metal endotracheal tube adapter which slips directly into the