

16. Tomkinson J, Turnbull A, Robson G, et al: Report on Confidential Enquiries into Maternal Deaths in England and Wales 1973-1975 London, H. M. Stationary Office, 1978, p 83
17. Moir DD: Obstetric anaesthesia. Baltimore, Williams & Wilkins, 1976, p 180
18. Albright GA: Anesthesia in obstetrics. Menlo Park, Addison-Wesley Publishing Co., 1978, p 276
19. Abouleish E: Pain Control in Obstetrics. Philadelphia, J. B. Lippincott Co., 1977, p 290
20. Bromage PR: Epidural Analgesia. Philadelphia, W. B. Saunders, 1978, p 209
21. Lee JA, Atkinson RS: Sir Robert Macintosh's Lumbar Puncture & Spinal Analgesia. 4th Edition, Edinburgh, Churchill Livingstone, 1978, p 154

Anesthesiology
55:595-596, 1981

New Method for Fiberoptic Endotracheal Intubation of Anesthetized Patients

WILLIAM F. CHILDRES M.D.*

Flexible fiberoptic laryngoscopy is a valuable method for endotracheal intubation of patients whose tracheas are difficult or impossible to intubate with conventional laryngoscopes.¹⁻³ This technique has generally been described in the awake state with topical anesthesia and sedation. For many patients, however, this is a stressful and unpleasant experience.

Endotracheal intubation of anesthetized patients with fiberoptic laryngoscopes introduces special problems. The pharynx collapses, leaving little or no air space to see through. The conventional laryngoscope provides its own exposure by lifting the anterior pharynx, which the fiberoptic instrument does not do. Visualization is difficult or impossible unless some other means is found to expand the pharynx. Lloyd has recommended pulling forward on the tongue with lung forceps.⁴ This can not always be done (*e.g.*, ankylosis of temporomandibular joint), does not always expand the hypopharynx sufficiently to lift the epiglottis, is traumatic to the tongue, and always requires an assistant.

The standard surgical tongue retractor was modified (fig. 1) to provide the exposure needed for fiberoptic laryngoscopy in anesthetized patients without an assistant. A slightly smaller size was made for females. Only simple tools were required to produce this retractor.

The retractor was designed to be used by an unassisted operator as illustrated in figures 1 and 2. The last three digits of the hand are used to hold the retractor after it has been placed in the mouth, and provide gentle lifting pressure to expose the larynx. The thumb and forefinger of the same hand can easily thread the fiberoptic laryngoscope into the trachea through the mouth or nose. The retractor may also be held by an assistant if the operator prefers. Complete exposure of the larynx is obtained.

The author has used this technique (unassisted) for 200 intubations of many different kinds of patients. They include ankylosing spondylitis, ankylosis of tempero-

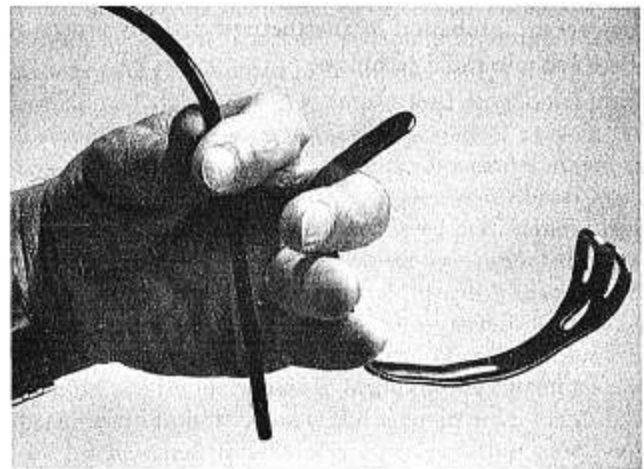


FIG. 1. Hand positioned to pass fiberoptic laryngoscope while holding retractor.

* Attending Staff, Anesthesiology Department.
Received from Methodist Hospital, Houston, Texas. Accepted for publication May 19, 1981.

Address reprint requests to Dr. Childres: Anesthesiology, 6565 Fannin, Houston, Texas 77030.

Key words: Equipment: fiberoptic laryngoscope.

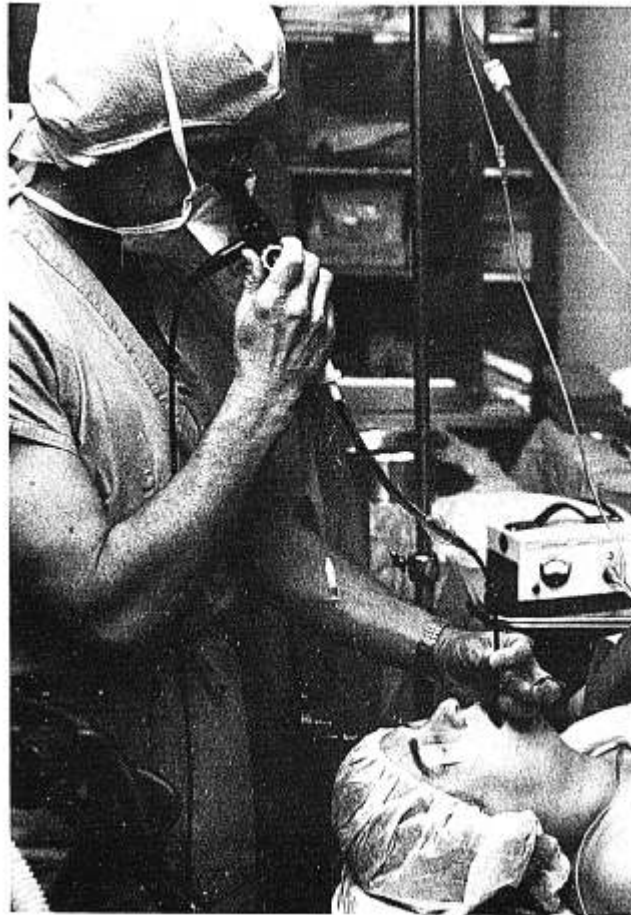

FIG. 2. Fiberoptic intubation with retractor.

mandibular joint, degenerative arthritis, patients in "halo" traction, fragile dental problems, normal patients whose tracheas are anatomically difficult to intubate with conventional laryngoscopes, and routine endotracheal intubations. With this retractor, unassisted fiberoptic endotracheal intubation in anesthetized patients proved to be a reliable rapid technique.

REFERENCES

1. Messeter KH, Petterson KI: Endotracheal intubation with the fiberoptic bronchoscope. *Anaesthesia* 35:294-298, 1980
2. Dennison PH: Four experiences in intubation of one patient with Still's disease. *Br J Anaesth* 50:636, 1978
3. Anderton JM: Difficulty in intubation. *Br J Anaesth* 50:1267, 1978
4. Lloyd EL: Fiberoptic laryngoscopy for difficult intubation. *Anaesthesia* 35:719, 1980