

cephalus to craniotomy in the sitting position while that patient had a functioning VP shunt. When the posterior fossa was opened, air entered the subdural space, allowing the ventricles to drain and to collapse completely.

Even with the skull intact, the shunted hydrocephalic patient lives with a constant potential risk of subdural hematoma.<sup>1,2</sup> Although the negative pressure due to the siphoning effect of the shunt is equally distributed through the skull, any slight head trauma may rupture a small dural-cortical blood vessel and lead to subdural hematoma, whereas in most patients such small bleeding sources are adequately tamponaded by the higher intracranial pressure. Valves opening at "high" (60–110 mm H<sub>2</sub>O) or "medium" (40–60 mm H<sub>2</sub>O) pressures are incorporated into shunts to minimize such complications. Antisiphoning devices have been developed,<sup>3</sup> but it is not clear that these devices reduce the incidence of subdural hematoma.<sup>2</sup>

Dependent loss of CSF during craniotomy may also occur in patients without shunts or ventricular catheters. Lunsford *et al.*<sup>4</sup> reported two cases of subdural tension pneumocephalus in patients who

underwent posterior fossa craniotomy in the sitting position. They postulated a mechanism for air entry analogous to entry of air into an inverted bottle, referring to the "inverted pop-bottle syndrome."

The risk of subdural pneumocephalus due to uncontrolled CSF drainage during craniotomy can be minimized by: 1) identification of patients at risk; 2) vigilant observation of ventricular or lumbar CSF drainage catheters and reservoirs; 3) externalization of functioning shunts prior to craniotomy with the patient in the sitting or head-up position.

#### REFERENCES

1. Driesen W, Elies W: Epidural and subdural hematomas as a complication of internal drainage of cerebrospinal fluid in hydrocephalus. *Acta Neurochir (Wien)* 30:85–93, 1974
2. Milhorat TH: Hydrocephalus, *Pediatric Neurosurgery*. Philadelphia, F. A. Davis, 1978, pp 91–135
3. Portnoy HD, Schutte RR, Fox JL, et al: Antisiphon and reversible occlusion valves for shunting in hydrocephalus and preventing postshunt subdural hematomas. *J Neurosurg* 38:729–738, 1973
4. Lunsford LD, Maroon JC, Sheptak PE, et al: Subdural tension pneumocephalus: Report of two cases. *J Neurosurg* 50:525–527, 1979

Anesthesiology  
52:271–273, 1980

### Hemodynamic Effects of Prosthesis Insertion during Knee Replacement without Tourniquet

KAMRAN SAMII, M.D.,\* EDITH ELMELIK, M.D.,† DANIEL GOUTALIER, M.D.,‡ PIERRE VIARS, M.D.,§

During recent total knee replacement operations in which bone cement was used, release of the tourniquet was followed by an acute and significant pulmonary vascular obstruction,<sup>1</sup> which may explain the reported complications of hypotension and cardiac arrest.<sup>2,3,4</sup> Although a tourniquet decreases hemorrhage and facilitates the surgical procedure, this operation may also be performed without a tourniquet.

In this study we observed the intraoperative hemodynamic changes during total knee replacement performed without a tourniquet.

#### METHODS

Eight patients (mean age 70 years, range 60–78 years) without cardiorespiratory disease were studied. All received a so-called Guepar prosthesis, which requires insertion with acrylic bone cement. Mean duration of the operations was 125 min.

Premedication with atropine, 0.5 mg, im, and diazepam, 10 mg, im, was followed by spinal anesthesia to T10 with tetracaine. Diazepam was infused during operation at a rate of approximately 0.02 mg/min. The patients were drowsy and breathed ambient air to which oxygen was added at 3 l/min. The estimated blood loss was replaced with whole blood and averaged 1,260 ml. Lactated Ringer's solution was administered in a mean volume of 740 ml.

\* Chef de Clinique Assistant in Anesthesiology and Intensive Care.

† Assistant in Anesthesiology and Intensive Care.

‡ Professor of Orthopedic Surgery.

§ Professor of Anesthesiology and Intensive Care.

Received from the Department of Anesthesiology and Intensive Care of the Pitie-Salpetriere Hospital, Paris, France, and the Departments of Anesthesiology and Intensive Care and Orthopedic Surgery of the Henri-Mondor Hospital, Créteil, France. Accepted for publication September 19, 1979.

Address reprint requests to Dr. Samii: Departement d'Anesthesie-Reanimation, Hospital Bicetre, 78, rue du General Leclerc, 94270 Le Kremlin Bicetre, France.

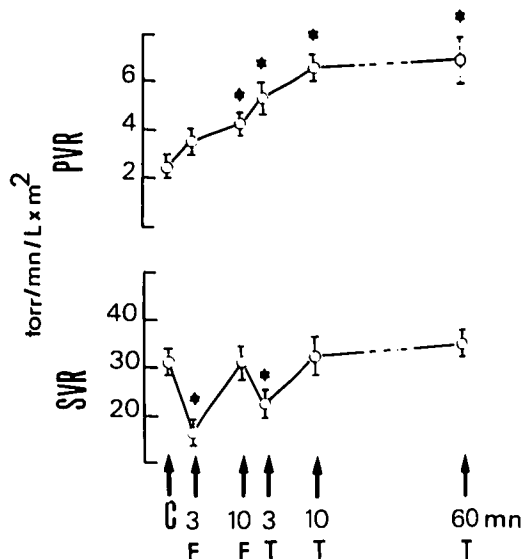


Fig. 1. Mean values  $\pm$  SEM of pulmonary vascular resistance (PVR) and systemic vascular resistance (SVR). Measurements were taken immediately before (C) femoral insertion of cement and prosthesis; twice after that procedure (F; at 3 and 10 min); and following tibial insertion (T; at 3, 10, and 60 min).

Central venous pressure (CVP), pulmonary arterial pressure (PAP), pulmonary-artery wedge pressure (PWP), and cardiac output by the thermal dilution method (CO) were measured using a Swan-Ganz triple-lumen thermistor catheter. Mean arterial pressure (MAP) was measured by a radial-artery catheter. Heart rate (HR) was determined from a standard ECG lead. Cardiac index (CI), systemic vascular resistance (SVR), pulmonary vascular resistance (PVR), left ventricular stroke work index (LVSWI), and right ventricular stroke work index (RVSWI) were calculated as previously described.<sup>1</sup> Blood gases were analyzed with standard electrodes at 37 C, and values were corrected to measured body temperature.

Preoperative measurements were performed two hours before the operation. Measurements were also

taken immediately before (C) and twice after (F) femoral insertion of cement and prosthesis (at 3 and 10 min). This was followed by tibial insertion (T), after which additional data were recorded at 3, 10, and 60 min.

All statistical analyses were performed with the Student *t* test for paired samples.

## RESULTS

The hemodynamic data are summarized in table 1. Preoperative hemodynamic values were within normal limits and did not change significantly during spinal anesthesia before prosthesis insertion. Three minutes after femoral insertion PAP, PVR, and RVSWI were unchanged. They were increased significantly ( $P < 0.05$ ) 10 min after femoral insertion and remained elevated until the study ended. The CVP elevation was not significant. At 3 min after each prosthesis insertion, there were transient, significant ( $P < 0.05$ ) decreases in MAP, SVR, and LVSWI.

These systemic hemodynamic changes ( $P < 0.05$ ) were more important clinically after femoral prosthesis insertion than after tibial insertion. No particular treatment was applied because the hypotension lasted  $\leq 60$  sec in all patients. Values of CI and HR did not change during the study.

Changes in PVR and SVR are shown in figure 1.

Blood-gas analyses during the study did not demonstrate hypoxemia ( $\text{PaO}_2 \geq 82$  torr), hypercapnia ( $\text{PaCO}_2 \leq 39$  torr), and acidosis ( $\text{pH} \geq 7.37$ ).

## DISCUSSION

Our results show important pulmonary and systemic hemodynamic changes after insertion of bone cement and prosthesis when a tourniquet is not used.

Increases in PAP and PVR were not associated with physiologic causes of pulmonary vasoconstriction such as decreased cardiac output, hypoxemia, hypercapnia, or acidosis. Thus, these changes suggest a pulmonary

TABLE 1. Hemodynamic Data

	Preoperative	C	3 min F	10 min F	3 min T	10 min T	60 min T
PAP (torr)	18.2 $\pm$ 1.4	19.2 $\pm$ 1.4	20.7 $\pm$ 2.6	29.7 $\pm$ 4.6*	29.8 $\pm$ 4.3*	29.0 $\pm$ 4.0*	28.0 $\pm$ 2.5*
PVR (torr/min/l $\times$ m <sup>2</sup> )	3.8 $\pm$ 0.4	2.5 $\pm$ 0.3	3.6 $\pm$ 0.6	4.2 $\pm$ 0.4*	5.1 $\pm$ 0.7*†	6.4 $\pm$ 0.7*	6.8 $\pm$ 1.0*
CVP (torr)	4.2 $\pm$ 1.5	7.8 $\pm$ 1.5	7.5 $\pm$ 1.6	10.3 $\pm$ 1.3	9.7 $\pm$ 1.5	8.8 $\pm$ 1.6	8.8 $\pm$ 1.8
PWP (torr)	7.2 $\pm$ 1.9	12.5 $\pm$ 1.3	12.0 $\pm$ 1.9	15.2 $\pm$ 2.0	15.0 $\pm$ 2.3	10.8 $\pm$ 2.6	11.6 $\pm$ 1.6
MAP (torr)	102 $\pm$ 0.9	100 $\pm$ 5	51 $\pm$ 4*	109 $\pm$ 11	82 $\pm$ 12*†	107 $\pm$ 10	98 $\pm$ 10
HR (beats/min)	88 $\pm$ 7	79 $\pm$ 6	94 $\pm$ 4	84 $\pm$ 8	88 $\pm$ 8	88 $\pm$ 7	83 $\pm$ 7
CI (l/min/m <sup>2</sup> )	3.4 $\pm$ 0.1	3.0 $\pm$ 0.1	3.0 $\pm$ 0.3	3.1 $\pm$ 0.2	2.9 $\pm$ 0.2	3.0 $\pm$ 0.2	2.7 $\pm$ 0.2
SVR (torr/min/l $\times$ m <sup>2</sup> )	30 $\pm$ 2	31 $\pm$ 2	16 $\pm$ 2*	31 $\pm$ 3	22 $\pm$ 3*†	32 $\pm$ 3	34 $\pm$ 2
RVSWI (g $\cdot$ m/m <sup>2</sup> )	7.9 $\pm$ 0.9	6.3 $\pm$ 0.4	6.7 $\pm$ 1.1	9.9 $\pm$ 0.6*	10.7 $\pm$ 1.4*†	11.4 $\pm$ 1.2*	8.6 $\pm$ 0.8*
LVSWI (g $\cdot$ m/m <sup>2</sup> )	53 $\pm$ 5	44 $\pm$ 3	18 $\pm$ 3*	54 $\pm$ 6	39 $\pm$ 6*†	52 $\pm$ 5	40 $\pm$ 4

Mean values  $\pm$  SEM are shown. Data were obtained two hours prior to anesthesia; before (C) and after (F) femoral prosthesis insertion; and after tibial prosthesis insertion (T).

\* = significantly different from C values ( $P < 0.05$ ).

† = significantly different from 3-min F values ( $P < 0.05$ ).

vascular obstruction and explain the rise in RVSWI. The transient fall in MAP observed 3 min after each prosthesis insertion (F and T) was due to an acute systemic vasodilation consistent with the decrease in SVR and the constant value of CI. Such a fall in arterial pressure has been similarly seen during total hip replacement surgery,<sup>6,7</sup> which is also performed without a tourniquet.

A vasodilatory action of bone cement at high temperature has been suggested as a cause of this hypotension.<sup>6,8</sup> However, the exact role of the release of fat, bone marrow, air, or monomers of acrylic cements into the vascular compartment is difficult to determine.<sup>5</sup>

When no tourniquet is used, the progressive pulmonary vascular obstruction may allow the bone cement to follow open channels in the lung, which may cause systemic vasodilation. This may explain why 3 min after femoral prosthesis insertion (3 min F)—when PVR has not yet increased—the fall in MAP and SVR is more important than it is 3 min after tibial insertion, when PVR has already increased (see fig. 1).

When a tourniquet was used<sup>1</sup> for the same operation, a progressive increase of pulmonary vascular obstruction occurred earlier, but transient systemic vasodilation was not observed.

The use of a tourniquet prevents acute systemic vasodilation, even after the release of the tourniquet. This may be due to an even and immediate distribution of particular matter and bone cement into the lung, with less bone cement reaching the systemic circulation. However, a tourniquet does not suppress the elevations of PAP and PVR, the latter increases with a shorter delay (3 min after the release of the tourniquet).

In conclusion, when a total knee replacement using bone cement is performed without a tourniquet, the prosthesis insertions induce a progressively increased pulmonary vascular obstruction and a transient but acute fall in arterial pressure. Thus, the operation may be particularly dangerous, and the possibility of such acute hemodynamic changes may be accentuated by a pre-existing hypovolemia. However, if this surgical procedure is chosen, hemodynamic therapy should be adapted to it. Intravascular volume must always be adequate and the use of alpha- and beta-adrenergic drugs such as epinephrine seems logical when a major episode of hypotension occurs during prosthesis insertion.

The authors thank Mr. K. Samii, B.S., for the revision of the manuscript.

#### REFERENCES

1. Samii K, Elmelik E, Mourtada MB et al: Hemodynamic changes during total knee replacement. *ANESTHESIOLOGY* 50:239–241, 1979
2. Arden G: Total joint replacement of the knee in rheumatoid arthritis. *J Bone Joint Surg* 53:150, 1971
3. Duparc J, Desmonts JM, Oliver H, et al: Accidents graves après mise en place de prothèses totales scellées du genou. *Nouv Presse Méd* 4:253–256, 1975
4. Harris NH: Cardiac arrest and bone cement. *Br Med J* 3: 523, 1970
5. Hallin G, Modig G, Nordgreen L, et al: The intramedullary pressure during the bone marrow trauma of total hip replacement. *Ups J Med Sci* 79:51–55, 1974
6. Frost PM: Cardiac arrest and bone cement. *Br Med J* 3:524, 1970
7. Modig J, Malmberg P: Pulmonary circulatory reactions during total hip replacement surgery. *Acta Anaesthesiol Scand* 19: 219–237, 1975
8. Cohen CA, Smith TC: The intraoperative hazard of acrylic bone cement: Report of a case. *ANESTHESIOLOGY* 35: 547–549, 1971

Anesthesiology  
52:273–275, 1980

## Failure of Divided Doses of Succinylcholine to Reduce the Incidence of Muscle Pains

D. B. WILSON, M.B., F.F.A.R.C.S.,\* AND J. W. DUNDEE, M.D., PH.D., F.F.A.R.C.S., M.R.C.P.†

Postoperative muscle pains continue to be a major side effect of succinylcholine. Various methods have been used to reduce the incidence and severity of these pains, the most widely used being pretreatment

with a nondepolarizing drug prior to succinylcholine injection<sup>1</sup> and bed rest for 24 hours. Because nondepolarizing drugs are long-acting, pretreatment with them limits the usefulness of succinylcholine in outpatient analgesia and during short operations. In 1977, Baraka<sup>2</sup> reported that pretreatment with succinylcholine, *i.e.*, giving a small, 10-mg dose prior to a paralyzing dose of 1 mg/kg, reduced the incidence and severity of muscle fasciculation. The present study was designed to determine

\* Senior Registrar.

† Professor and Chairman.

Received from the Department of Anaesthetics, The Queen's University of Belfast, Northern Ireland. Accepted for publication October 7, 1979.

Address reprint requests to Dr. Dundee.