

Anesthesiology
51:577, 1979

Optimal Placement of a Central Venous Pressure Catheter before Cardiopulmonary Bypass

To the Editor:—Valid determinations of central venous pressure (CVP) are essential during cardiopulmonary bypass. Because we routinely use a pulmonary-artery catheter for both CVP and pulmonary arterial pressure monitoring during open-heart surgery, we find it mandatory to ensure that the proximal opening of the catheter (30 cm hole) has not been advanced beyond the point where the caval vein clamp is going to be placed for total cardiopulmonary bypass. We have found the following to be an easy and reliable technique for assuring that CVP monitoring is occurring. After the surgeon has inserted the caval catheters for venous drainage, the superior vena cava is clamped and the CVP continuously recorded. When the proximal hole of the catheter is placed beyond the clamp (fig. 1, *A*) no change in the CVP will occur. In contrast, when the catheter is optimally placed with the proximal hole above the clamp (fig. 1, *B*) the CVP will increase with caval clamping. Recording the changes in CVP before cardiopulmonary bypass with and without clamping the superior vena cava is a simple technique to ensure the optimal placement of a CVP or pulmonary-artery catheter.

JENS PETER RASMUSSEN, M.D.
Associate Professor

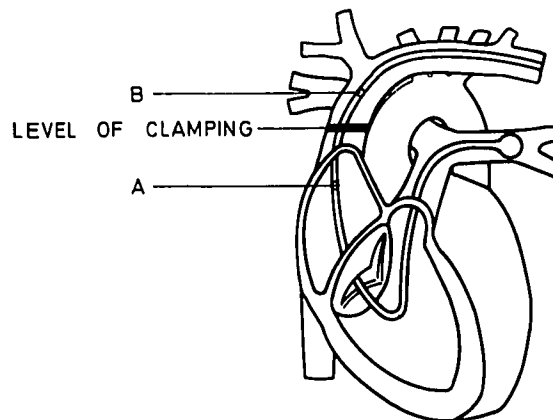


FIG. 1. Pulmonary-artery catheter in place with the central venous pressure port below (*A*) and above (*B*) the site of clamping of the superior vena cava during cardiopulmonary bypass.

BENT HUSUM, M.D.
Instructor in Anesthesia
Department of Anesthesia
Faculty of Medicine
University of Copenhagen
Gentofte Hospital
2900 Hellerup, Denmark

(Accepted for publication July 19, 1979.)

Anesthesiology
51:577-578, 1979

Ketamine Anesthesia of a Catatonic Schizophrenic Patient

To the Editor:—Ketamine anesthesia has been stated to be contraindicated for patients who have psychiatric disorders.¹ Recently we had the opportunity to use ketamine for an individual with the diagnosis of catatonic schizophrenia. The patient had sustained a 16 per cent thermal burn on the anterior abdomen and legs from attempted self-immolation during a "religious experience." Her catatonia was resolving when she was scheduled for skin grafting. Ketamine anesthesia was chosen because repeated procedures were planned. Preoperative medications consisted of meperidine, hydroxyzine, and atropine, in addition to haloperidol, 10 mg, *qid*. The skin grafting lasted

three hours, during which time ketamine, 410 mg, was given intravenously. Postoperative recovery from the anesthesia was rapid and uneventful; the patient reported no hallucinations, and no extra psychotropic medication was needed. Moreover, ketamine anesthesia was administered for subsequent skin graftings, again without complication.

Psychiatric disease *per se* should not be an absolute contra-indication for ketamine anesthesia. Providing adequate psychotropic medications are given and the nursing staff alerted to treat promptly excitatory phenomena, ketamine can be used safely and effectively in these patients.