

## Continuous Axillary Analgesia for Traumatic Hand Injury

RICHARD ROSENBLATT, M.D.,\* FRAN PEPITONE-ROCKWELL, Ph.D.,† MALCOLM J. MCKILLOP, M.D.‡

We present a case of a mutilating hand injury in a teenager, for which axillary analgesia by a continuous infusion provided postoperative control of pain. Significant psychological problems resulted from the injury; these are also reviewed.

## REPORT OF A CASE

A healthy right-handed 15-year-old boy amputated his index finger and lacerated multiple tendons in his right hand while operating a table saw. Emergency microvascular reanastomosis with multiple tendon repairs was planned, with an anticipated operative time in excess of six hours. Continuous axillary anesthesia was selected for the surgical procedure and to provide postoperative analgesia. In the operating room the patient was sedated with diazepam, 10 mg, iv, the right axilla aseptically prepared, and a sterile tourniquet placed on the upper arm to prevent distal spread of the anesthetic solution. A quarter-inch incision was made at the intersection of the pectoral fold and axillary artery. An 18-gauge, 5-cm Teflon®-coated intravenous catheter threaded over a 22-gauge, 8.75-cm spinal needle was introduced through the incision and advanced centrally along the axis of the artery at a 30-degree angle to the skin. With a nerve stimulator attached to the spinal needle, the neurovascular bundle was located when median nerve stimulation produced contraction of the palmaris longus. The position of the needle within the neurovascular sheath was confirmed by injecting 2 ml 3 per cent 2-chloroprocaine through the spinal needle, abolishing the twitch. Next, 20 ml each of bupivacaine, 0.75 per cent, and 2-chloroprocaine, 3 per cent, were injected, whereupon the outer catheter was advanced up the now distended neurovascular bundle, the spinal needle discarded, and the catheter sutured in place. An intravenous extension tube, flushed with bupivacaine, was connected to the catheter, and the insertion site covered with an occlusive dressing.

Unfortunately, the trauma was so extensive that only repair of the lacerated tendons was performed. The operation lasted two hours and was otherwise uneventful.

In the recovery room, the catheter position was confirmed radiographically (fig. 1) by injecting 10 ml Renografin 60®. Infusion of bupivacaine, 0.25 per cent, 10 ml/hr, was begun while residual analgesia was still present. A volumetric infusion pump was used to maintain a constant flow rate of bupivacaine. Regional analgesia of the hand was continued for the next two days, during which the patient did not need supplemental narcotics. No complication occurred postoperatively: vital signs remained normal,

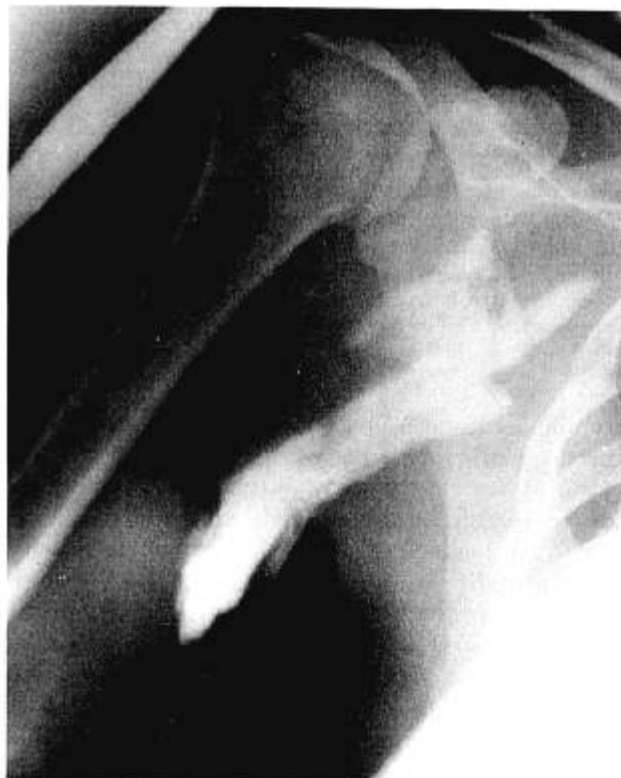

FIG. 1. Roentgenogram demonstrating the placement of the catheter within the axillary sheath following the injection of 10 ml Renografin 60®.

and anesthetic toxicity was seen. During the infusion, serum concentration of bupivacaine was measured periodically (fig. 2). Residual analgesia persisted for several hours after the infusion was discontinued. Negative bacteriologic cultures were obtained from the local anesthetic reservoir bottle and the distal catheter. Four days after operation, the patient was discharged. He has since recovered partial use of his hand and has returned to school.

## DISCUSSION

Continuous brachial plexus analgesia using a supraclavicular,<sup>1</sup> axillary,<sup>2</sup> or interscalene<sup>3,4</sup> catheter and *intermittent* injections of local anesthetic has been described. In this case, postoperative analgesia was provided solely by the continuous axillary infusion, without complications from the catheter insertion or the local anesthetic infusion. No difficulty was encountered with the volumetric infusion pump, which eliminated the need for repeated injections.

Substantive questions remain unresolved with this

\* Assistant Professor, Department of Anesthesiology.

† Assistant Professor, Department of Psychiatry.

‡ Resident, Department of Anesthesiology.

Received from the University of California, Davis, Sacramento, California. Accepted for publication May 20, 1979.

Address reprint requests to Dr. Rosenblatt: Department of Anesthesiology, University of California, Davis, 4301 X Street, Sacramento, California 95817.

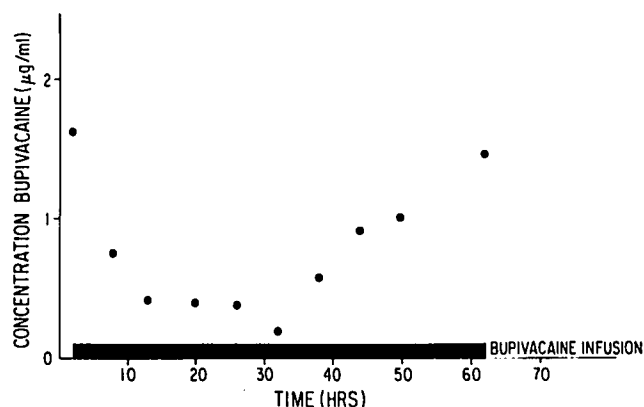


FIG. 2. A graph depicting serum bupivacaine concentrations from initial axillary injection until cessation of local anesthetic infusion. Bupivacaine concentrations are in  $\mu\text{g/ml}$ . At zero hour, the initial single-dose axillary injection was performed, and at approximately 2 hours (the beginning of the heavy black bar), the infusion began.

technique. Bupivacaine, 0.25 per cent, was chosen based on prior experience with continuous infusion epidural anesthesia.<sup>5</sup> The infusion rate, however, cannot readily be determined, since the only endpoints are inadequate analgesia or systemic toxicity. The 10 ml/hr infusion rate was tried since a single axillary injection of 40 ml bupivacaine, 0.25 per cent, lasts four hours. Although this is below the toxic dose of bupivacaine, significant plasma accumulation developed during the second day (the convulsant blood level in monkeys is  $4.5 \mu\text{g/ml}$ <sup>6</sup>), indicating that metabolism and excretion of the local anesthetic was exceeded by the infusion. This could be a posologic problem, which, together with the pharmacokinetics of long-term local anesthetic administration, needs to be studied further. Finally, the risks of prolonged axillary analgesia beyond those described for the single-injection technique are unknown.

This injury not only proved physically and emotionally traumatic to the patient, but also was occupationally debilitating, because he was a carpenter's apprentice. The psychological stress was accentuated by the mother, who recently had had a close relative die in the same hospital, and was hysterical upon her son's admission. The mother, being allowed to room-in, spent the next four days continuously with her son. Throughout the hospitalization, she displayed overt anxiety—crying and abusive behavior—as a result of her obsessive morbid ruminations.

By contrast, her son demonstrated remarkable adult-like calmness. Under normal circumstances an injury of this magnitude, coupled with potential loss

of occupation, would be psychologically devastating. However, the severity was reduced by presenting the patient with a behavioral paradigm: Indeed, the injury was terrible and it should hurt proportional to the trauma. Since it was not painful, it could not be as serious as implied. Chapman and Cox<sup>7</sup> have found that postoperative anxiety can potentiate pain. In this situation, a reversal occurred: because pain was absent, anxiety did not appear.

Fright, uncertainty, and helplessness have also been implicated as three major psychological determinants capable of modulating postoperative pain.<sup>8</sup> Undoubtedly the mother was empathetically experiencing all three, while her son, having no pain, felt neither frightened nor helpless. The regional analgesia, by relieving the pain, minimized the psychological issues.

While a chronic pain syndrome would not normally be anticipated with this operation, it can occur in similar circumstances. Alleviating the pain by prolonged regional analgesia diminished the psychological impact of the injury and possibly prevented the development of chronic pain.

In summary, a traumatized hand was maintained pain-free intraoperatively and for two days postoperatively with continuous axillary analgesia. No complication was seen, and the analgesia provided significant psychological benefit to the patient.

The authors are indebted to Abbott Laboratories for the volumetric infusion pump used in this study; Department of Anesthesia, University of California, Los Angeles, for performing the bupivacaine determinations; and John Eisele, M.D., and Jack Reitan, M.D., for reviewing the manuscript.

#### REFERENCES

1. Ansbro FP: Method of continuous brachial plexus block. *Am J Surg* 71:716-722, 1946
2. Selander D: A new method for axillary blocks: Catheter instead of needles. *International Anesthesia and Critical Care Reporter* 2:6 May 1978
3. DeKrey JA, Schroeder CF, Buechel DR: Continuous brachial plexus block. *ANESTHESIOLOGY* 30:332, 1969
4. Manriquez RG, Pallares V: Continuous brachial plexus block for prolonged sympathectomy and control of pain. *Anesth Analg (Cleve)* 57:128-130, 1978
5. Rosenblatt RM, Raj P: Experience with volumetric infusion pumps for continuous epidural analgesia. *Regional Anesthesia* 4:3-5, 1979
6. De Jong RH: *Local Anesthetics*. Springfield, Ill., Charles C Thomas, 1977, pp 95
7. Chapman CR, Cox GB: Anxiety, pain and depression surrounding elective surgery. *Psychosomat Res* 21:7-15, 1977
8. Chapman CR, Cox GB: Determinants of Anxiety in Elective Surgery Patients, Stress and Anxiety. Volume 4. Edited by CB Spielberger. New York, John Wiley and Sons, 1978