

physical means to be the mean of their hydrogen ion concentration and not the mean of their *pH* values.

I'm reminded of the statistician who drowned while swimming in a Texas creek, the average depth of which was 6 inches from one year to the next.

ADOLPH H. GIESECKE, JR., M.D.
*Department of Anesthesia
Parkland Memorial Hospital
Dallas, Texas 75235*

REFERENCES

1. Feinstein AR: On central tendency and the meaning of mean for *pH* values. *Anesth Analg (Cleve)* 58:1-3, 1979
2. Drummond GB: More on calculation of mean *pH* values. *Anesth Analg (Cleve)* 58:63, 1979
3. Krause PD: Statistical analysis of *pH* data. *Anesth Analg (Cleve)* 57:143-144, 1978
4. Giesecke AH Jr, Beyer CW, Kallus FT: More on interpretation of *pH* data. *Anesth Analg (Cleve)* 57:379-381, 1978
5. Giesecke AH Jr: Averaging values for gastric *pH* incorrect. *ANESTHESIOLOGY* 50:70-71, 1979

(Accepted for publication June 12, 1979.)

Anesthesiology
51:483, 1979

Hazard Associated with New Foretrend® Anesthesia Machine

To the Editor:—During scheduled follow-up inspection of new equipment recently introduced to clinical service, we found that the table-top surface of a Foregger Foretrend gas machine had acquired a tilt, sloping down from front to rear. When our other identical units, placed in service at the same time, were then examined, we found that three of the four shared the same problem. The rear edge of the table top of one machine had slipped down far enough to expose both the upper and lower O-rings used to seal the chrome vertical gas delivery tube, thereby allowing a gas leak. This tube normally connects the right-hand side of the back bar assembly to the plumbing below the table top. The difficulty was traced to inadequate tightening of the set screws that bind the table top assembly to the vertical support posts. The combined weight of the top itself, any equipment placed thereon, and the suspended gas cylinders gradually pushed the rear mounts lower and lower on the posts. Since the vertical gas delivery tube uses an O-ring seal at both ends, the distance between the two O-ring seats is critical. When the table top assembly is displaced 1 cm, both O-rings come out of their seats and a leak results.

We suggest that all Foregger Foretrend model anesthesia machines now in use be carefully examined to ensure that the table top is in the correct position,

with the O-rings on the vertical gas delivery tube properly seated within the hex nut on the table top and in the aluminum block on the back bar, and that the set screws holding the table top be checked for a secure attachment to the vertical posts. Failure to achieve the proper seal with both O-rings will allow a leak. Correspondence with the manufacturer's representative suggests that this problem is less likely to occur in the presence of the full drawer assembly option, as the box that houses the drawer slides serves as additional mechanical support for the table top. Older models do not share the problem, as the table top is held in place by pins that transfix the posts, rather than by set screws.

DANIEL F. DEDRICK, M.D.
*Instructor in Anaesthesia
Harvard Medical School
Assistant in Anesthesia
Massachusetts General Hospital*

C. DAVID MIERAS
*Biomedical Engineering Technician
Department of Anesthesia
Massachusetts General Hospital
Boston, Massachusetts 02114*

(Accepted for publication June 14, 1979.)

Anesthesiology
51:483-484, 1979

Optimal Positioning for Cervical and Thoracic Operations

To the Editor:—The Relton-Hall scoliosis operating frame* has achieved considerable popularity among

orthopedic surgeons and anesthesiologists. While providing patient stability, it allows the anterior abdominal wall to be free from external pressure, thereby decreasing spinal venous plexus engorgement. The height of the operating frame requires the

* Imperial Surgical Company, 3585 St. Clair Avenue, E., Scarborough, Ontario, Canada.

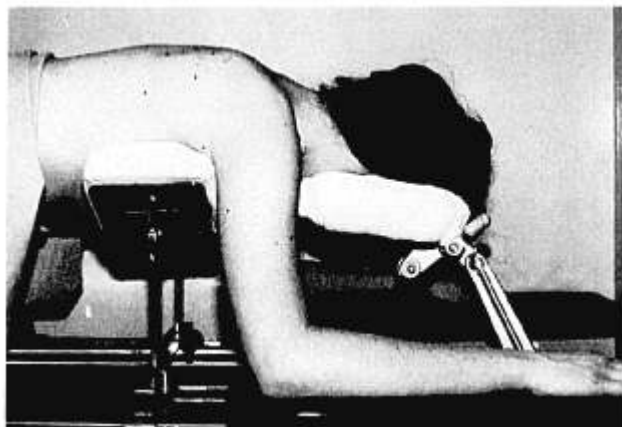


FIG. 1. The Mayfield neurosurgical horseshoe headrest in use with the Relton-Hall operating frame. The cephalad posts of the operating frame are behind the arms, leaving the axillae free. (Illustration kindness of Susan Hitchins, R.N., and Thomas P. Keon, M.D.)

head be supported at a considerable distance above the operating table. In the original¹ and subsequent² report of its use, pillows constructed from many folded sheets supported the head, which was then turned to the side. This is less than ideal, because the head tends to be unstable. We have substituted the Mayfield neurosurgical horseshoe headrest,[†] and found that it allows the head to be securely maintained

[†]Model 35-1078, -1076, Codman & Shurtleff, Inc., Randolph, Massachusetts 02368.

at the proper height (fig. 1). The disadvantages of the horseshoe neurosurgical headrest include pressure on the eyes if the head is not correctly positioned on the headrest, which has been adjusted to the correct width. The risk of trauma to the eyes is greatest in the pediatric population, due to the great variation in the transverse diameters of the frontal bone. Despite this disadvantage, we have employed the horseshoe headrest with the Relton-Hall frame in 30 procedures without complications attributable to position or these devices.

EUGENE K. BETTS, M.D.

Assistant Anesthesiologist

*The Children's Hospital of Philadelphia
34th Street and Civic Center Boulevard
Philadelphia, Pennsylvania 19104*

and

*Assistant Professor of Anesthesia at
The Children's Hospital of Philadelphia
University of Pennsylvania
Philadelphia, Pennsylvania 19104*

REFERENCES

1. Relton JES, Hall JE: An operation frame for spinal fusion. *J Bone Joint Surg* 49B:327-332, 1967
2. Martin JT: Anesthesiologic considerations: Orthopedics, Positioning in Anesthesia and Surgery. Edited by JT Martin. Philadelphia, W. B. Saunders, 1978, pp 183-192

(Accepted for publication June 14, 1979.)

Anesthesiology
51:484-485, 1979

Thrombotic Occlusion of a Nasotracheal Tube

To the Editor:—We wish to call attention to a hazard of endotracheal intubation. A young female patient had sustained massive head trauma in a bicycle accident, necessitating prompt neurosurgical intervention. Her trachea was intubated in the emergency room using a nasotracheal tube with a low-pressure cuff. The intubation was associated with brisk bleeding from the nares. After intubation, her lungs could be ventilated easily, and breath sounds on auscultation were normal. The endotracheal tube was not, however, suctioned after intubation. About an hour later, during the craniotomy, complete occlusion of the airway developed abruptly. A patent airway was secured by reintubation orally with a new endotracheal tube.




FIG. 1. The obstructed endotracheal tube and the intraluminal thrombus.