

Radial Arterial Function following Percutaneous Cannulation with 18- and 20-gauge Catheters

Robert F. Bedford, M.D.*

Radial arterial function was evaluated in 108 patients following 24 hours of percutaneous cannulation with either 18- or 20-gauge cannulas. Arteriography, Doppler ultrasound examination, and Allen's test disclosed an 8 per cent incidence of radial-artery occlusion following cannulation with 20-gauge cannulas, compared with a 34 per cent incidence of occlusion with 18-gauge cannulas ($P < .05$). Vessels that occluded were significantly smaller in diameter than were patent vessels (mean $2.00 \pm .09$ mm SE vs. $2.22 \pm .05$ mm, $P < .05$). Occluded vessels also contained significantly greater amounts of thrombotic material (0-3+) just prior to decannulation than those that remained patent ($2.42 \pm .13$ vs. $1.20 \pm .11$, $P < .001$). The incidence of arterial occlusion increases linearly as the ratio of cannula outer diameter to vessel-lumen diameter increases. (Key words: Monitoring, blood pressure; Arteries, radial; Complications, thrombosis.)

IN RECENT YEARS, percutaneous radial-artery cannulation has become a common monitoring technique. Although generally safe and simple, it frequently results in temporary radial-artery occlusion, which is usually asymptomatic and resolves spontaneously.¹

The influence of cannula size on the incidence of vessel occlusion remains controversial. Downs *et al.*² found a significantly greater amount of thrombus formation in vessels cannulated with 18-gauge cannulas compared with 20-gauge cannulas, whereas we were unable to find a difference in the incidences of subsequent arterial occlusion between these two sizes of cannulas.¹ Neither of these studies controlled the duration of cannulation, however, and the incidence of occlusion increases the longer the cannula remains in the artery.^{1,3}

In an effort to further identify the risks of percutaneous radial-artery cannulation, we initiated a prospective study of vessel function following a standard period of cannulation with either 18- or 20-gauge Teflon† cannulas. In addition, we compared one brand of radiopaque and non-radiopaque cannulas, since most manufacturers now offer both types.

Methods and Materials

During a nine-month period we studied 108 consecutive patients who underwent percutaneous

radial-artery cannulation lasting 22-26 hours. Of these cannulations, 92 were performed for monitoring during major elective operations. Informed consent for this study was obtained from these patients during the preoperative interviews, and the radial arteries were cannulated with four types of Teflon catheters, in random sequence; 1) 20-gauge Cathlon IV,† 2) 18-gauge Cathlon IV, 3) 18-gauge Longdwell,§ and 4) 18-gauge Longdwell-radioopaque. An additional 16 cannulations were performed with 20-g Cathlon IV catheters for monitoring patients who were undergoing emergent operations.

Allen's test⁴ for both radial- and ulnar-artery patency and Doppler ultrasound examination were performed in the operating room to document patency of both vessels prior to radial-artery cannulation. When a palmar blush did not appear within 5 seconds of release of the ulnar artery, collateral circulation to the hand was considered inadequate for radial-artery cannulation. Six patients were not subjected to cannulation due to inadequate collateral circulation bilaterally. Our technique of percutaneous radial-artery cannulation has been described.¹ In this study, however, only a 3-cm length of catheter was introduced below skin level. All catheters were flushed with a continuous 3 ml/hr infusion of 0.9 per cent saline solution containing heparin (2 units/ml) via an Intraflow® system.¶ No patient received systemic anticoagulants postoperatively.

On the first postoperative day, arteriography was performed by injecting 25 per cent Hypaque solution,** 5 ml, through the catheter while a roentgenogram of the wrist and hand was obtained simultaneously. A 100-cm focal-film distance was utilized to minimize magnification error. With this technique, vessel size could be determined to the nearest .25 mm. Arteriography was not performed on the patients who had emergent procedures, since informed consent had not been obtained prior to cannulation.

The arteriograms were interpreted independently by two radiologists who did not know the types of cannulas used or the subsequent clinical findings. Thrombus formation was quantitated on a 0-3+ scale as outlined by Downs *et al.*²: 0 = no visible thrombus, 1+ = small amount of thrombus visible, 2+ = moderate thrombus, 3+ = vessel occluded by thrombus.

* Assistant Clinical Professor of Anesthesia, Columbia University College of Physicians and Surgeons; Attending Anesthesiologist, Mary Imogene Bassett Hospital, Cooperstown, New York 13326. Present address: Department of Anesthesia, University of Virginia Medical Center, Charlottesville, Virginia 22903.

Accepted for publication March 17, 1977. Supported in part by a grant from the Stephen Carleton Clark Foundation of the Mary Imogene Bassett Hospital.

Presented at the Annual Meeting of the American Society of Anesthesiologists, October 1976.

Address reprint requests to Dr. Bedford.

† Trademark, Dupont Co.

‡ Jelco Laboratories, Raritan, New Jersey 08869.

§ Becton-Dickinson Company, Rutherford, New Jersey 07070.

¶ Sorenson Research, Salt Lake City, Utah 84115.

** Sodium Diatrizoate, U.S.P., Winthrop Laboratories, New York, New York 10016.

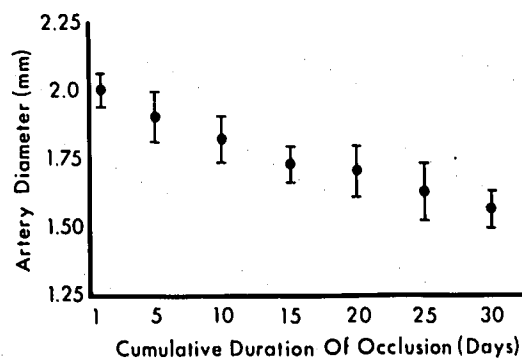


FIG. 1. The overall time courses of recanalization in 25 patients with occluded radial arteries plotted against vessel sizes as determined by arteriography. The vessels that required the longest periods to recanalize tended to be smaller than those that recanalized after only a few days. Bars indicate means \pm SE.

The catheters were removed after 24.3 ± 0.3 SEM hours of cannulation. Direct digital pressure was maintained over the arterial puncture site for 5 minutes or until hemostasis was assured, and a sterile dressing was applied.

Following decannulation, radial arterial function was evaluated daily until the patient was discharged from the hospital (follow-up interval: 13.4 ± 1.3 SEM days). A vessel was considered occluded when, over a period of 24 hours or longer, the Allen's test filling time from the radial artery was longer than 10 seconds, and when an area of absent flow was found with Doppler examination as previously described.¹ Careful physical examination of the wrist and hand was also performed daily, looking for evidence of embolization, discoloration of the skin, infection, or ischemia. When physical examination demonstrated recanalization of an occluded radial artery, the duration of occlusion was noted. In the cases of patients with occluded vessels who were lost to follow-up before recanalization occurred, the durations of occlusion were recorded as being greater than the numbers of days they were actually followed. Cumulative recanalization data were then analyzed as lasting *longer than* the number of days followed.

Statistical comparisons for incidences of arterial

occlusion were made using Yate's correction for chi-square analysis; all other comparisons were performed with Student's *t* test for non-paired data.

Results

Table 1 summarizes the clinical findings with regard to radial-artery occlusion following cannulation with the four types of catheters studied. Among all the patients cannulated with 20-gauge Cathlon IV catheters, there was essentially no difference in the incidences of vessel occlusion between those undergoing emergent operations and those who had elective procedures (6 and 8 per cent, respectively). In contrast, there was a 30 per cent incidence of occlusion following cannulation with 18-gauge Cathlon IV catheters ($P < .05$ versus the 20-gauge Cathlon IV cannula).

Radiopaque Longdwell catheters induced no more occlusive lesions than did non-radiopaque Longdwell catheters (31 and 36 per cent, respectively). In fact, there was no significant difference in the thrombogenicities of the three types of 18-gauge cannulas studied. Accordingly, additional data were analyzed by comparing all cannulations with 18-gauge cannulas and all those with 20-gauge cannulations.

Catheter dysfunction, as evidenced by dampening of the pulse-pressure contour or difficulty in aspirating blood samples, occurred in 20 per cent of the cannulations with 20-gauge cannulas and 13 per cent of the cannulations with 18-gauge cannulas. This difference was not significant. Arteriography demonstrated, however, that accumulation of thrombus was responsible for dysfunction of 18-gauge catheters (all these vessels were completely occluded just prior to decannulation), whereas the 20-gauge cannulae became dysfunctional from kinking in the subcutaneous tissues.

The arteriographic findings also demonstrated that those vessels that were found to be occluded by physical examination contained significantly greater quantities of thrombus (on a 0–3+ scale) just prior to decannulation than did those arteries that remained patent (mean $2.42 \pm .13$ SEM versus $1.2 \pm .11$, $P < .001$). In addition, the mean diameter of the occluded arteries ($2.00 \text{ mm} \pm 0.09$ SE) was significantly smaller ($P < .05$) than that of the vessels that were not occluded ($2.22 \text{ mm} \pm 0.05$).

Although 25 cannulated radial arteries in this study became occluded, there was no clinical evidence of distal ischemia or embolization. There was one instance of purpuric discoloration of the skin, which developed over an occluded radial artery, but this cleared spontaneously over a seven-day period without progressing to an overt skin slough.

An unexpected finding in this study was that the duration of radial-artery occlusion was related to vessel size. Occlusions that required the longest times to recanalize occurred in the smallest vessels, whereas larger vessels required relatively shorter periods for blood flow to be re-established (fig. 1).

TABLE 1. Summary of 108 Consecutive Percutaneous Radial-artery Cannulations of 24-hour Duration

Type of Cannula	Number of Patients	Incidence of Vessel Occlusion (Per Cent)
Elective operations (with arteriography):		
Longdwell, 18-gauge	22	36
Longdwell (radiopaque), 18-gauge	26	31
Cathlon IV, 18-gauge	20	30
Cathlon IV, 20-gauge	24	8
Emergent operations:		
Cathlon IV, 20-gauge	16	6

Discussion

The results of this study indicate that after 24 hours of percutaneous radial-artery cannulation there is a significantly lower incidence of vascular occlusion following the use of 20-gauge catheters compared with 18-gauge catheters. Arteriography demonstrates that these occlusive lesions appear to be caused by the accumulation of thrombus while the cannula is in place. The increased thrombogenicity of 18-gauge catheters may result from a greater surface area over which clot can form (20 per cent larger than that of 20-gauge catheters). Postmortem microscopic examination of cannulated vessels, however, suggests that damage to the radial arterial intima also initiates the formation of thrombus.¹ That a higher incidence of occlusion occurs in smaller vessels and that they require longer periods to recanalize suggest that they sustain more trauma during cannulation than do larger vessels.

Plastic catheters are made radiopaque by impregnation with heavy metal salts. It has been shown that radiopaque polyethylene arteriography catheters are more thrombogenic *in vivo* than identical non-radiopaque catheters.⁵ To our knowledge, however, there has been no comparison of plain and radiopaque Teflon cannulas used for arterial monitoring. We found no difference between the plain and radiopaque Longdwell catheters with regard to either the amounts of thrombus formed or the incidences of arterial occlusion and cannula dysfunction observed. Apparently the size of the cannula plays a more important role in the formation of occlusive vascular lesions than does the composition of the Teflon from which the cannula is manufactured.

Since post-cannulation radial-artery occlusion was found to be related to both vessel size and catheter size, these variables were combined by calculating the percentage of the vessel lumen occupied by the cannula (vessel cross-sectional area = π [diameter/2]², cannula cross-sectional area = π [cannula outer diameter/2]²). The ratio of these areas when plotted against the incidence of arterial occlusion results in a remarkably straight line (fig. 2). Large catheters, such as the Longdwell 18-gauge, occupy almost the entire lumen of smaller arteries and result in a very high incidence of arterial occlusion. Conversely, the smaller 20-gauge catheters, which occupy only 15–20 per cent of the lumens of relatively large arteries, rarely induce arterial occlusion.

In this study, using a 5-second filling time for the Allen's test palmar blush to appear, no ischemic complication resulted from the 25 radial-artery occlusions induced. In a previous study of radial-artery thrombosis,¹ we observed a 10 per cent incidence of distal ischemia when a 15-second Allen's test filling time was used. In addition, we now perform a more meticulous examination, with particular attention to capillary filling of the thumb and thenar eminence. Using these more stringent criteria, 7

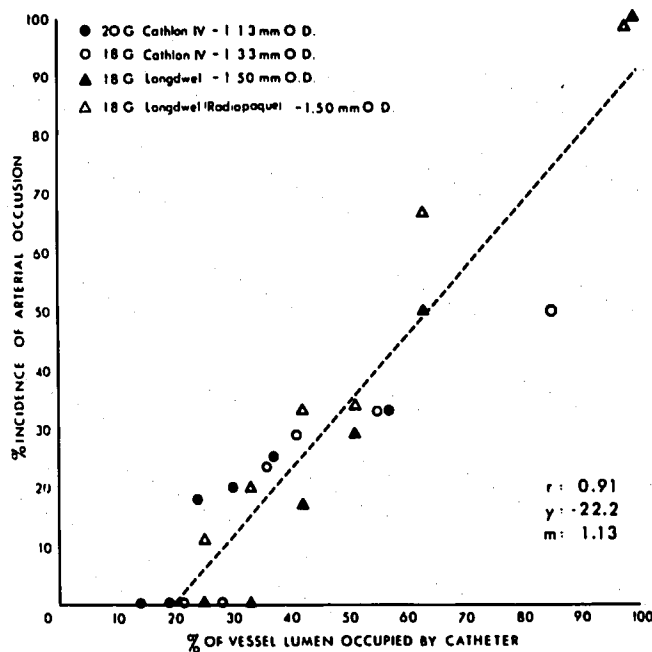


FIG. 2. Radial arterial thrombosis after 24 hours of cannulation. The incidence of arterial occlusion increases linearly as more of the vessel lumen area is occupied by cannula. Small cannulas in large vessels generated very few occlusive lesions, whereas large cannulas almost always caused occlusion of small arteries.

per cent of the patients in this study had a satisfactory Allen's test on one side but not on the other. We chose not to cannulate the radial arteries of six additional patients who had ulnar-artery Allen's test filling times in excess of 5 seconds bilaterally.

In summary, we found that the incidence of post-cannulation radial arterial occlusion can be decreased significantly by using 20-gauge cannulas instead of 18-gauge cannulas. In addition, small radial arteries (less than 2 mm in diameter) are more likely to occlude and remain thrombosed longer than large radial arteries (more than 2.25 mm in diameter). We urge that adequate collateral circulation from the ulnar artery be documented prior to percutaneous radial-artery cannulation in order to decrease the possibility of vascular complications associated with this procedure.

References

1. Bedford RF, Wollman H: Complications of percutaneous radial-artery cannulation: An objective prospective study in man. *ANESTHESIOLOGY* 38:228–236, 1973
2. Downs JB, Rackstein AD, Klein EF Jr, et al: Hazards of radial-artery catheterization. *ANESTHESIOLOGY* 38:283–286, 1973
3. Brown AE, Sweeney DB, Lumley J: Percutaneous radial-artery cannulation. *Anaesthesia* 24:532–536, 1969
4. Allen EV: Thromboangiitis obliterans: Methods of diagnosis of chronic occlusive arterial lesions distal to the wrist, with illustrative cases. *Am J Med Sci* 178:237–244, 1929
5. Schlossman D: Thrombogenic properties of vascular catheter materials *in vivo*. *Acta Radiol (Diagn)* 14:186–192, 1973