

more inaccessible. The position of the needle shaft was reidentified with the aid of a portable fluoroscope and marked with a metal needle. A 5-cm incision was necessary to remove the needle shaft, which had migrated an additional centimeter deeper. The T10 spinal anesthesia level was adequate for removal of the missing needle shaft, as well as the intramedullary femoral nail.

DISCUSSION

The metal needle shaft had become separated from the plastic hub (figs. 1 and 2) because the binding between the two was insufficient and obviously did not meet the usual standards of the manufacturer.

The complication might have been avoided if the junction of the hub and needle had been tested prior to use. The metal needle shaft might also have been more amenable to recovery if the introducer had not been inserted to the hub. The admonition to avoid the introduction of needles completely to the hub has been made frequently^{2,3}. The security bead was designed to limit the depth to which a needle could be inserted; however, this feature is not incorporated in any disposable needle currently available.

Because broken pieces of needle tend to wander, immediate removal is indicated. If a needle is diagnosed as broken while still fixed in its relationship to a second needle or stylette, the intact item should be left in place as a marker. If needle breakage is discovered after the proximal portion has been removed, a second needle should be

inserted as a marker along the tract of the broken needle. The relationship of the marker needle to the broken needle can be verified by tactile sensations or x-ray and the broken fragment removed following surgical exposure. Broken needles are particularly a problem when breakage occurs in deep inaccessible areas such as those involved while administering spinal, caudal, paravertebral, sacral, or lumbar sympathetic blocks. Indeed, the most detailed discussions of broken-needle retrieval exist in literature dealing with spinal anesthesia.^{4,5}

The era of disposable needles has been associated with neglect of precautions previously proven to be indicated for the use of needles incorporated in regional block administration. Disposable needles should be checked prior to use for weakness, particularly at the needle-hub injunction. When executing any block, needles of various lengths should be available so that insertion of needles to the hub can be avoided.

REFERENCES

1. Bonica JJ: Principles and Practice of Obstetric Analgesia and Anesthesia. Volume I. Philadelphia, F. A. Davis, 1967, pp 562, 633
2. Adriani J: Labat's Regional Anesthesia Technique and Clinical Applications. Philadelphia, W. B. Saunders, 1967, p 370
3. Bonica JJ: The Management of Pain. Philadelphia, Lea and Febiger, 1953, p 223
4. Maxson LH: Spinal Anesthesia. Philadelphia, J. B. Lippincott, 1938, pp 172-176
5. Lahey FH: The removal of broken spinal needles. JAMA 93:518-519, 1929

Anesthesiology
46:148-150, 1977

Partial Recovery from Pancuronium Neuromuscular Blockade Following Hydrocortisone Administration

ELSIE F. MEYERS, M.D.*

In 1952, Torda and Wolff¹ observed that adrenocortical hormones restored decreased neuromuscular action potentials toward normal in hypophysectomized animals. We believe the following to be the first reported case in which adrenocortical extracts improved neuromuscular function of a patient with supposed adrenal insufficiency.

REPORT OF A CASE

A 44-year-old Caucasian man was anesthetized for vitrectomy and lensectomy because of proliferative

diabetic retinopathy, vitreous hemorrhage, and retinal detachment of the right eye. He had been known to be diabetic for 22 years; cryohypophysectomy had been performed two years previously in an attempt to halt progression of retinopathy. His diabetes mellitus was well controlled. Otherwise, the past medical history was unremarkable.

Physical examination revealed bilateral diabetic retinopathy and neuropathy of both feet and legs. Weight was 84 kg and height 180 cm; blood pressure ranged between 120/90 and 160/90 torr. The patient appeared euthyroid.

Medications included cortisone, 37.5 mg/day in divided doses, sodium levothyroxine, 0.1 mg/day, methyltestosterone, 10 mg/day, and lente insulin, 80 units in the morning, 35 units in the evening.

Routine laboratory studies disclosed no abnormality except elevated postprandial blood glucose levels.

* Assistant Professor of Anesthesiology, Department of Anesthesiology, Washington University School of Medicine, 660 South Euclid Avenue, St. Louis, Missouri, 63110.

Accepted for publication September 20, 1976.

Address reprint requests to Dr. Meyers.

Medications the evening before operation were cortisone acetate, 100 mg, im, substitution of 25 units regular insulin for the evening dose of lente insulin, and pentobarbital, 100 mg, p.o., for sleep. On the morning of operation, one and a half hours prior to induction of anesthesia, the patient received cortisone acetate, 100 mg, im, and his usual doses of levothyroxine and methyltestosterone. Cyclopentolate hydrochloride (Cyclogyl®) and phenylephrine drops were used to dilate the pupil of the right eye. Premedication consisted of droperidol, 5 mg, im, one and a half hours prior to induction of anesthesia.

On arrival in the operating room, the patient appeared well sedated and calm. Fasting blood glucose was 75 mg/dl.

After placement of appropriate monitors and warming blanket, anesthesia was induced with diazepam, 10 mg, iv, and sodium thiopental, 100 mg, iv. Following pretreatment with *d*-tubocurarine, 4.5 mg, and topical lidocaine laryngotracheal spray, 160 mg, endotracheal intubation was accomplished with difficulty, facilitated by succinylcholine, 140 mg, iv. A peripheral nerve stimulator was applied. Following disappearance of the succinylcholine block, vigorous twitch response was present. Anesthesia was maintained with nitrous oxide-oxygen (4:2 l/min flow) and intermittent halothane, 0.5–1 per cent. Because the patient could not tolerate 0.5 per cent halothane continuously, pancuronium was employed. An initial dose of 5 mg pancuronium was administered, followed by increments of 1.5–2 mg. A total of 12 mg pancuronium was given during the first three hours of anesthesia. Ventilation was controlled with an Ohio ventilator (tidal volume, 850 ml, rate, 10/min). A visible single-twitch response to the peripheral nerve stimulator was maintained.

After almost four hours of anesthesia, the patient became profoundly paralyzed although no pancuronium had been given for almost an hour. Responses to single twitch and to tetanic stimulation disappeared, and only slight posttetanic potentiation was present. Blood pressure remained low (95–100/70 torr) even though halothane had been discontinued for a half hour. During the first three hours, discontinuing halothane in the face of equally low blood pressures had been quickly followed by increases to 140–180/90–120 torr. Body temperature remained normal, serum electrolytes were within normal limits, and blood glucose levels ranged from 75 to 225 mg/dl. No insulin had been given.

Inadequate replacement of adrenocortical hormone was suspected.^{2–5} Hydrocortisone sodium succinate, 100 mg, iv, was given. Within 4 minutes the peripheral nerve stimulator demonstrated brisk twitches; a spontaneous breathing pattern returned. Blood pressure rose to 180/100 torr; the pulse remained at 80/min.

The surgeon was still instrumenting the eye. Halothane, 1.5 per cent was administered to prevent movement, then decreased to 0.5 per cent for the remaining 30 min. Blood pressure stabilized at 120–130/80 torr. At the end of the operation the peripheral nerve stimulator demonstrated vigorous twitches, but some fade and posttetanic facilitation were evident. Reversal was completed with atropine, 2 mg, and neostigmine, 5 mg, iv. The trachea was extubated and the patient admitted to the postanesthesia recovery room, where he was responsive and calm. Vital signs were stable. During

the 4.5 hours of anesthesia, he had received 1,000 ml of 5 per cent dextrose in lactated Ringer's solution and 150 ml of lactated Ringer's solution.

His usual medications were resumed the following day. The postoperative course was uneventful, marred only by an insulin reaction on the day of discharge from the hospital (seven days postoperatively).

DISCUSSION

This patient showed no evidence of the common sequelae to hypophysectomy, such as anemia, diabetes insipidus, or hypersensitivity to insulin, which may pose problems for the anesthesiologist. No sign of hypoadrenalism was present. Sensitivity to anesthetic agents is common in patients who have severe diabetes mellitus and/or hypopituitarism.^{6,7} The immediate increase of blood pressure following corticosteroid replacement was probably due to increased cardiac output.³ This response is, in itself, strongly suggestive of an underlying endocrine abnormality.⁸

The partial reversal of neuromuscular blockade following corticosteroids was unexpected. However, a review of the literature reveals that in adrenalectomized and hypophysectomized animals a defect of neuromuscular transmission has been found.¹ A patient with panhypopituitarism manifested electromyographic and histologic evidence of neuromuscular change.⁹ Woodbury¹⁰ observed that adrenalectomized animals have defects in transmission at the cord level, at the neuromuscular junction, and in muscle, and that all three sites are equally sensitive to the lack of adrenocortical hormones. He also pointed out that ACTH improves neuromuscular function of patients who have myasthenia gravis. Stewart¹¹ described two cases of flexor muscle spasm in hypopituitarism, and postulated that the syndrome follows the shift of water and electrolytes with disturbed sodium transport that occurs in cortisol deficiency. He theorized that there may be a direct effect on muscle contractility, as on neuromuscular transmission, and that free transfer of Na and K ions across the surface membrane of the motor end-plate may well be hindered in cortical deficiency.

The present report suggests that there may be a defect of neuromuscular transmission in patients who have adrenal cortical insufficiency.

The author expresses special thanks to Carol Mondia for her invaluable aid in translation.

REFERENCES

1. Torda C, Wolff HG: Effect of pituitary hormones, cortisone and adrenalectomy on some aspects of neuromuscular function and acetylcholine synthesis. *Am J Physiol* 169: 140–149, 1952
2. Cope CL: *Adrenal Steroids and Disease*. Second edition. Philadelphia, J. B. Lippincott, 1972, pp 557–568

3. Locke W, Schally AV: The Hypothalamus and Pituitary in Health and Disease. Springfield, Ill, Charles C Thomas, 1972, pp 290-347
4. Myles AB, Daly JB: Corticosteroid and ACTH treatment. Baltimore, Williams and Wilkins, 1974, pp 162-167
5. Pearson OH: Endocrine consequences of hypophysectomy. *ANESTHESIOLOGY* 24:563-567, 1963
6. Meyers EF, Wilson S: Vitrectomy: A new challenge for the anesthesiologist. *Anesth Analg (Cleve)* 54:58-64, 1975
7. Wilson AM: Anesthesia for Sheehan's syndrome: A case report. *Br J Anaesth* 40:996-998, 1968
8. Vandam LD, Moore FD: Adrenocortical mechanisms related to anesthesia. *ANESTHESIOLOGY* 21:531-552, 1960
9. Vio M, Fiaschi A, Ferrari G: Neuromuscular complications in the course of panhypopituitarism. *Acta Neurol (Napoli)* 28:425-432, 1973
10. Woodbury DM: Relation between the adrenal cortex and the central nervous system. *Pharmacol Rev* 10:275-357, 1958
11. Stewart AG, Sprunt JG: Hypopituitarism and flexor muscle spasm. *Acta Endocrinol (Kbh)* 53:489-498, 1966

Anesthesiology
46:150-151, 1977

Modification of Nitrous Oxide-induced Intracranial Hypertension by Prior Induction of Anesthesia

JOHN R. PHIRMAN, M.D.,* AND HARVEY M. SHAPIRO, M.D.†

Reports have documented intracranial pressure (ICP) elevations in neurosurgical patients associated with the induction of anesthesia with nitrous oxide.^{1,2} Our recent observations of ICP changes in a deeply comatose patient confirm the ability of nitrous oxide to elevate ICP and indicate that prior induction of anesthesia with diazepam and thiopental can block intracranial hypertension due to nitrous oxide.

REPORT OF A CASE

A previously healthy, 90-kg, 22-year-old man was admitted to the University of California Medical Center in San Diego with a history of the abrupt onset of headache followed by deepening coma. Cerebral angiography revealed an arteriovenous malformation of the upper brainstem.

Following performance of a ventriculostomy (opening CSF pressure 19 mm Hg), the patient was admitted to the neurologic intensive care unit. Five days after admission, a tracheostomy was performed under local anesthesia. Continuous cerebrospinal fluid drainage was necessary to maintain ICP below 20-25 mm Hg. Three days later the patient was scheduled for a ventriculo-peritoneal cerebrospinal fluid shunt. At the time of the shunt procedure his neurologic status had stabilized. He remained comatose, with a bilateral decerebration response to painful stimuli. His pupils were pinpoint and non-reactive to light, corneal reflexes were intact, and there was no response to caloric testing.

* Resident.

† Associate Professor of Anesthesia/Neurosurgery.

Received from the Departments of Anesthesia and Surgery (Neurosurgery), University of California, San Diego, California. Accepted for publication September 20, 1976. Supported in part by the Medical Research Service of the Veterans Administration.

Address reprint requests to Dr. Shapiro: Anesthesia Research—151, Veterans Administration Hospital, 3550 La Jolla Village Drive, San Diego, California 92161.

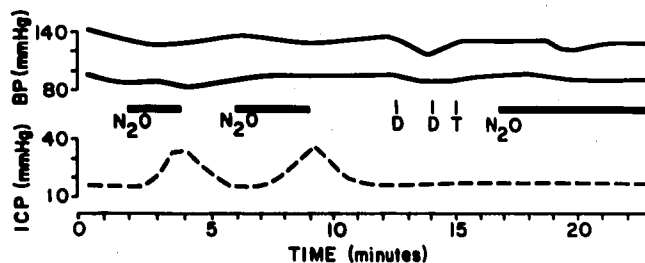


FIG. 1. Blood pressure (BP) and intracranial pressure (ICP) responses to repeated administration of 70 per cent nitrous oxide (N₂O). The patient was paralyzed and ventilated with 100 per cent oxygen prior to and between administrations of N₂O. Diazepam (D) was administered in divided doses of 15 and 5 mg, respectively. Thiopental (T), 150 mg, was given once.

In the operating room, following placement of a brachial blood pressure cuff and attachment of the tracheostomy tube to a semiclosed circuit of an anesthesia machine, the patient's ICP was measured by connecting the ventriculostomy tubing to an electronic pressure transducer. End-tidal CO₂ was continuously determined by a Beckman LBII CO₂ analyzer through a 100-cm length of low-deadspace tubing inserted into the tracheostomy tube.

The patient was then given 10 mg of pancuronium bromide and ventilated with 100 per cent oxygen at a constant frequency of 12 with a tidal volume of 1,100 ml. Following 10 minutes of stabilization ICP was 15 mm Hg, blood pressure 139/96 mm Hg, and end-tidal CO₂ 31 mm Hg. Figure 1 depicts the changes in ICP and blood pressure that occurred thereafter. Within 60 seconds following the introduction of nitrous oxide in oxygen into the breathing circuit (71 N₂O + 31 O₂), ICP increased. When ICP had risen to about 35 mm Hg, the breathing gas was abruptly switched to 100 per cent oxygen. Shortly thereafter, ICP returned to its baseline value of 15 mm Hg. This cycle was repeated on a second exposure to nitrous oxide.

Diazepam (20 mg) and thiopental (150 mg) were