

airway pressure from 40 to 28 cm H₂O as the helium concentration was increased from 20 to 80 per cent. P_{aCO_2} was also reduced, from 63 to 45 torr. P_{aO_2} decreased proportionally with reduction in $F_{I_{O_2}}$.

After total occlusion of the right mainstem bronchus and partial occlusion of the left mainstem bronchus, the following hemodynamic data (mean \pm SE) were obtained ($n = 6$): CO = 2.7 ± 0.65 l/min; SV = 23.1 ± 6.40 ml; HR = 120 ± 5 beats/min; MAP = 115 ± 7 torr; PR = 2.56 ± 0.91 torr/ml/sec. These variables were not significantly altered during administration of the helium-oxygen mixture.

DISCUSSION

The low-density helium-oxygen mixture promoted better gas flow through the narrow orifice, as indicated by the reduction in peak airway pressure. As ventilation improved, the P_{aCO_2} decreased.

Graham's law of diffusion states that the gas flow rate through a narrow orifice is inversely proportional to the square root of its density.⁶ Hence the lighter the gas mixture, the greater the flow rate through a narrow orifice. This was demonstrated in our animal studies, in which ventilation was improved after helium was added. The densities and relative gas flow rates are summarized in table 2.

Forty per cent helium with 60 per cent oxygen was the optimal mixture for maintaining desirable arterial blood-gas values in the acutely airway-obstructed dogs. The low density of helium made it possible to ventilate the lungs through a restricted orifice, requiring less driving pressure to fill the lung. An oxygen-helium mixture can substantially improve the efficiency of breathing during upper airway obstruction.

The authors thank Dr. Fredrick Cheney for his helpful suggestions for preparing this paper.

REFERENCES

1. Egan DF: Helium therapy. *Fundamentals of Inhalation Therapy*. St. Louis, C. V. Mosby, 1969, pp 275-278.
2. Barach AL: The use of helium as a new therapeutic gas. *Anesth Analg (Cleve)* 14:210-215, 1935.
3. Barach AL: The use of helium in the treatment of asthma and obstructive lesions in the larynx and trachea. *Ann Intern Med* 9:739-765, 1935.
4. Barach AL: The therapeutic use of helium. *JAMA* 107:1273-1280, 1936.
5. Warner H, Gardner R, Toronto A: Computer based monitoring of cardiovascular functions in postoperative patients. *Circulation (suppl 1)* 37:68-74, 1968.
6. MacIntosh R, Mushin WW, Epstein HC: Helium-oxygen mixture. *Physics for Anesthetists*. Second edition. Oxford, Blackwell, 1958, pp 192-195; 250-251.

Esophageal Perforation of Unusual Etiology

WILLIAMS E. PEMBLETON, M.D.,* AND JAMES W. BROOKS, M.D.†

When perforation of the esophagus occurs during anesthesia the mechanism by which it was produced is not always apparent. It may be associated with difficulty in laryngoscopy and insertion of the endotracheal tube. The following report presents an unusual etiologic

factor of this complication—the presence of a pharyngoesophageal, or Zenker's, diverticulum.

REPORT OF A CASE

A 40-year-old white woman was admitted for removal of chronically infected adenoidal tissue. Past medical history was noncontributory. Physical examination disclosed no abnormality except the presence of excess adenoidal tissue, and results of routine laboratory determinations were within normal limits.

Hydroxyzine, 50 mg, meperidine, 75 mg, and atropine, 0.4 mg, were given im at 9:35 AM. At 10:30 AM anesthesia was induced with 250 mg thiopental followed by succinylcholine, 70 mg, iv, and 4 ml of

* Clinical Professor of Anesthesia.

† Professor of Surgery.

Received from the Departments of Anesthesia and Thoracic Surgery, Medical College of Virginia, Richmond, Virginia. Accepted for publication July 21, 1976.

Address reprint requests to Dr. Pembleton: Suite 506, 1805 Monument Avenue, Richmond, Virginia 23219.

4 per cent lidocaine, administered intratracheally. Visualization of the larynx was not difficult. The endotracheal tube was deflected away from the glottis and into the left pyriform sinus three or four times before being successfully introduced. The intubation was not considered traumatic or actually difficult. The operation was confined to the nasopharynx. During the afternoon the patient complained of discomfort in her neck, which was attributed to the procedure, and in the upper chest. Examination of the chest was negative, and vital signs and temperature were normal. However, the next morning there was obvious crepitation in the neck and upper chest, and x-ray studies with contrast medium revealed extravasation from the hypopharynx. Exploration of the neck later that day disclosed a 3-mm perforation of the left pyriform fossa. The wound did not close in the expected period of a week to ten days, a fistula developed, and subsequently, drainage of an abscess that had formed was carried out. Drainage continued for ten weeks, and the patient was then discharged with the sinus tract still present.

DISCUSSION

Follow-up x-ray studies revealed a diverticulum in the cricopharyngeal area (fig. 1), which evidently had been perforated by the endotracheal tube and which accounted for the delay in closure of the fistula.

There are areas of weakness in the lateral pharyngeal wall associated with vestigial structures of the bronchial clefts and the constrictor muscles. The latter are incomplete in several areas, allowing passage of various structures such as the eustachian tube and the stylopharyngeus nerve. There is a weak area between the cricopharyngeus and the muscle fibers of the esophagus, where the diverticulum was present in this patient. Any of these sites can be the location for development of a diverticulum, either congenital or

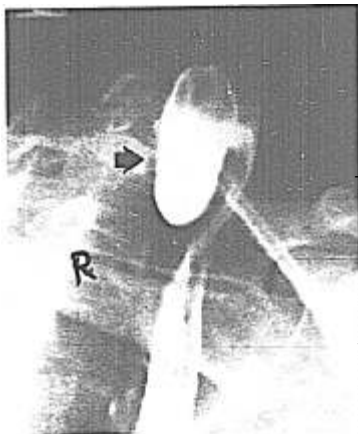


FIG. 1. Diverticulum filled with barium.

produced by increased intrapharyngeal pressure.¹

The incidence of such diverticula is not known, but is obviously low.² When the series of events described in this report does occur, a perforated esophageal diverticulum should be suspected.

REFERENCES

1. Wilson CP: Pharyngeal diverticula, their cause and treatment. *J Laryngol Otol* 76:151-156, 1962
2. Tribble WM: The surgical treatment of Zenker's diverticulum. *South Med J* 68:1260-1263, 1975