

consciousness. This suggests that the catheter had entered the subarachnoid space, an impression confirmed by easy aspiration of fluid that contained glucose and had a physiologic pH. The concentration of bupivacaine found in the aspirate also supports this conclusion. Wilkinson and Lund¹ found that after epidural block with bupivacaine, the maximum concentration of local anesthetic in the cerebrospinal fluid was 31 $\mu\text{g}/\text{ml}$. The concentration we obtained (205 $\mu\text{g}/\text{ml}$) is equivalent to 35 mg of bupivacaine distributed in a 170-ml volume. Finally, the development of a typical post-lumbar-puncture headache indicates that the subarachnoid space was entered.

Numerous cases of inadvertent spinal anesthesia have occurred with bupivacaine²⁻⁴ and other agents.⁵ Our case is unique in that spinal anesthesia occurred late in a previously satisfactory epidural anesthesia.

In conclusion, we report an incident of late appearance of total spinal anesthesia following uneventful epidural block. It must be assumed that the catheter penetrated the dura and en-

tered the subarachnoid space, although we are at a loss to explain the mechanism. Total spinal anesthesia might have been avoided had the epidural catheter been aspirated prior to the reinforcement dose of anesthetic. This event stresses the necessity for continuous monitoring during epidural anesthesia.

REFERENCES

1. Wilkinson GR, Lund PC: Bupivacaine levels in plasma and cerebrospinal fluid following peridural administration. *ANESTHESIOLOGY* 33:482-486, 1970
2. Gillies IDS, Morgan M: Accidental total spinal analgesia with bupivacaine. *Anaesthesia* 28: 441-445, 1973
3. Crawford JS: The strange case of the (inadvertent) continuous spinal. *Br J Anaesth* 46:82, 1974
4. Hartley M: The strange case of the inadvertent spinal. *Br J Anaesth* 47:420, 1975
5. Moore DC: Complications of regional anesthesia. *Regional Anesthesia: Recent Advances and Current Status, Clinical Anesthesia*. Edited by JJ Bonica. Philadelphia, F.A. Davis, 1971, pp 217-251

A Cervical Mass Associated with Positive Pressure on the Airway

MYRNA C. NEWLAND, M.D.,* JAMES W. CHAPIN, M.D.,† DANIEL W. WINGARD, M.D.†

The spontaneous appearance of a mass in the neck shortly after induction of anesthesia in a 9-year-old boy was cause for concern. Several possibilities were considered for differential diagnosis, and finally anesthesia was discontinued and further evaluation was done to make a definitive diagnosis.

REPORT OF A CASE

A 9-year-old white boy was admitted to the hospital for operative correction of an undescended right testicle. The past medical history was un-

remarkable except for a behavior problem, for which he was currently receiving psychiatric care. He had two younger siblings, both of whom were healthy. Physical examination revealed that the patient was thin and of average stature and build. The head was small and measured in the third percentile. The neck was slender, and no mass was palpable. The thyroid was normal in size, and the trachea was in the midline. The lungs were clear, and heart murmurs were not detected. The remainder of the examination was within normal limits, except for five *café-au-lait* spots over the right scapula and an empty right scrotal sac. Blood pressures in both arms and legs were normal. Results of laboratory tests were within normal limits. A roentgenogram of the chest showed a prominent aortic knob and possible rib notching. An electrocardiogram was consistent with borderline left ventricular hypertrophy. A cardiology consultation led to the recommendation that the patient be followed in cardiology clinic at six-month intervals and that a slight coarctation of the aorta could not be ruled out. Operation was not contraindicated at this time.

* Assistant Professor.

† Instructor.

‡ Professor and Chairman.

Received from the Department of Anesthesiology, University of Nebraska Medical Center, Omaha, Nebraska 68105. Accepted for publication December 1, 1975.

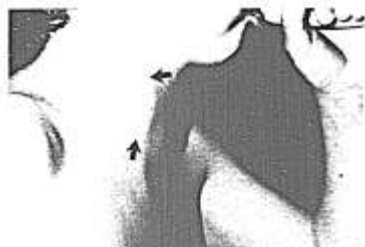


FIG. 1. Lateral view of the neck while the patient is expanding a balloon. Arrows outline the mass.

The patient was brought to the operating room after premedication with 50 mg meperidine and 0.3 mg atropine, im, 45 minutes before the scheduled operation, and anesthesia was induced with high flows of nitrous oxide, oxygen, and increasing amounts of halothane added to a semiclosed circle

system. When the dressing gown was removed after induction, a 3 × 4-cm mass was noticed in the right neck. It appeared to inflate and deflate in response to positive-pressure breathing by mask. The mass was soft and crepitant to palpation and did not appear to pulsate. Coarse breath sounds were heard clearly over the mass. Upon release of all positive pressure, the mass did not completely disappear.

Consideration was made of several possibilities, including branchial cleft cyst, laryngeal or tracheal cyst, venous aneurysm, and pulmonary cyst. Anteroposterior and lateral roentgenograms of the neck were obtained and photographs were taken. Because of the elective nature of the operation and lack of a positive diagnosis, the procedure was cancelled.

In the recovery room, the swelling disappeared completely. It could be made to reappear with bag-and-mask positive pressure or by a Valsalva maneuver by the patient (fig. 1). Radiologic evaluation the following day showed herniation of the cupola of the right lung above the level of the clavicle during a Valsalva maneuver (fig. 2). (The discrepancy in the apparent sizes of the mass may be related to variation in the patient's effort and cooperation). This was interpreted as a defect in Sibson's fascia with herniation of lung tissue into the fascial planes of the neck.

The patient later underwent uneventful anesthesia and operation for correction of an undescended testicle and circumcision. No treatment was recommended for the herniation of the lung while he remains asymptomatic.

DISCUSSION

The differential diagnosis of a cervical mass includes a long list of abnormalities. Considering only those conditions that enlarge with positive pressure on the airway, one should consider pharyngeal pouch, laryngocoele, vascular dilatation, and herniation of the lung. The diagnosis can be made by obtaining a lateral roentgenogram of the neck during the Valsalva maneuver, or with fluoroscopy using contrast material for an esophagogram or laryngogram with positive pressure on the airway.

Herniation of the lung has been reported only rarely. Fewer than three hundred cases have been described. The original classification of pulmonary hernias was made by Morel-Lavellee¹ in 1847. He classified the hernias by location, cervical, thoracic, and diaphragmatic, and by etiology, congenital or acquired. Acquired hernias were further subdivided into traumatic, consecutive (those following some

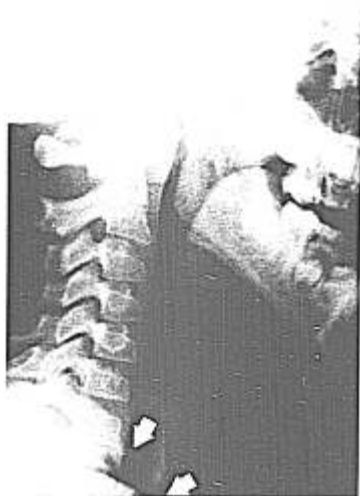

FIG. 2. Lateral roentgenogram of the neck, showing herniation of cupola of the right lung above the clavicle during a Valsalva maneuver.

time after injury), spontaneous, and pathologic (following abscess, tumor, etc).

Most early reported cases were related to trauma.² In recent years, congenital cervical pulmonary hernias in children and young adults have been described.^{3,4} They may be associated with other congenital defects and, when present, any Valsalva maneuver will increase the herniation. When they are asymptomatic, no treatment is necessary. Supraclavicular herniation of the lung in the emphysematous adult patient is not uncommon.⁵ Symptomatic pulmonary hernias may require operative repair, and Munnell⁶ has described a variety of techniques that have been used.

A rare and unexpected case of cervical herniation of the lung has been presented. This abnormality should be kept in mind in the differential diagnosis of a mass in the neck,

especially in association with positive pressure on the airway or the Valsalva maneuver.

REFERENCES

1. Morel-Lavellee A: Hernies du poulmon. Bull Soc Chir Paris 1:75, 1845-1847
2. Montgomery JG, Lutz H: Hernia of the lung. Ann Surg 82:220-231, 1925
3. Catalona WJ, Crowder WL, Chretien PB: Occurrence of hernia of Morgagni with filial cervical lung hernia: A hereditary defect of the cervical mesenchyme? Chest 62:340-347, 1972
4. Stearman MD, Majd M, Lopresti JM: Congenital cervical herniation of the lung. Med Ann DC 40:759-760, 1971
5. Fenichel NM, Epstein BS: Pulmonary apical herniations. Arch Intern Med 96:747-751, 1955
6. Munnell ER: Herniation of the lung. Ann Thorac Surg 5:204-212, 1968

A Safe Surface Electrode for Peripheral-nerve Stimulation

AARON F. KOPMAN, M.D.*

In 1974, Lippmann and Fields reported burns at the site of skin contact with metal ball electrodes used in conjunction with a peripheral nerve stimulator.¹ As a result of that report, the manufacturer of the most widely available such stimulator now advocates that only subcutaneously inserted needle electrodes be used with this unit.² The manufacturer specifically discourages the use of any surface electrode.

Bruner³ and Gray⁴ quickly expressed reservations as to the necessity for such a severe restriction on the use of this unit. We also believe that this injunction against skin electrodes is unwarranted if care is taken in preparation of the skin and a suitable electrode is selected. We examined this hypothesis

in 100 adult patients undergoing surgical procedures in which the use of muscle relaxants and a nerve stimulator was deemed advantageous.

MATERIALS AND METHODS

The NDM long-term monitoring electrode[†] was used as the skin electrode in all patients. This is a disposable pre-gelled silver/silver chloride electrode with an adhesive foam pad backing. The connecting lead wires between electrode and peripheral nerve stimulator (mushroom snap connector to male banana plug) were also obtained from NDM Corporation.[‡]

In studies of the first 50 patients, a Wellcome peripheral nerve stimulator was selected, because it is widely distributed and it was the unit mentioned by Lippmann and Fields. Since the Wellcome peripheral nerve stimulator is no longer being manufactured,

* Assistant Professor of Clinical Anesthesiology, State University of New York, School of Medicine at Stony Brook.

Received from the Department of Anesthesiology, Long Island Jewish-Hillside Medical Center, New Hyde Park, New York 11040. Accepted for publication December 21, 1975.

Address reprint requests to Dr. Kopman at Long Island Jewish-Hillside Medical Center.

† NDM Corporation, P.O. Box 1408, Dayton, Ohio. Catalog #01-1010.

‡ Catalog #03-2542.