

Evaluation of Percutaneous Cannulations of the Dorsalis Pedis Artery

JOHN A. YOUNGBERG, M.D.,* MAJOR, MC, AND EDWARD D. MILLER, JR., M.D.,† MAJOR, MC

Several studies of the reliability and complications involved when radial or ulnar arteries are used for intra-arterial monitoring have been done, but little has been written concerning cannulation of the dorsalis pedis artery. Spoerel *et al.*¹ stated that the average mean pressure in the dorsalis pedis artery is approximately 4 torr higher than that in the radial artery. Johnstone and Greenhow² reported that peak pulse pressure was 5–20 torr higher in the dorsalis pedis artery than in the radial artery. To determine whether cannulation of the dorsalis pedis artery is clinically acceptable, we prospectively evaluated the complication rate of cannulation of the dorsalis pedis artery by physical examination and Doppler-flow studies during long-term follow-up.

MATERIALS AND METHODS

Thirty dorsalis pedis artery cannulations were performed in 28 patients (14 males, 14 females) undergoing general anesthesia. Their ages ranged from 31 to 76 years, with a mean of 49 years. All dorsalis pedis arteries were cannulated with a 20-gauge Teflon Abbocath-T catheter (1½ inches long, .024 inch ID).

All patients were examined preoperatively with a directional Doppler Model 806 and by physical examination to determine patency

of both the dorsalis pedis and posterior tibial arteries. The dorsalis pedis and posterior tibial arteries were occluded and the great and second toes were blanched manually by a second person. The Doppler 15-degree pencil probe was placed first over the dorsalis pedis artery and pressure was released over that artery while the posterior tibial artery remained occluded. The toes were checked for color and extent of relative flow noted as registered by the Doppler meter. This procedure was repeated for posterior tibial arterial flow while the dorsalis pedis artery was kept occluded. Cannulation was not performed unless the toes flushed in <10 seconds and posterior tibial arterial flow was considered adequate. Pulse strength and blood pressures, taken by Doppler apparatus, were recorded for both feet and an arm. No diabetic patient was included in the study.

The dorsalis pedis artery was cannulated after appropriate preparation and the cannula connected to an 84-inch flexible arterial pressure line leading to the strain gauge. The line and cannula were taped firmly to the foot. The foot was then placed in the neutral position.

All arterial cannulas were flushed with solutions containing 2 units of heparin per ml. Solutions used were physiologic saline (NS), 5 per cent dextrose in water (D5W), D5W½NS, Ringer's lactate (RL), D5WRL, and D5W.2NS. Three-milliliter injections were used to flush the cannulas whenever the pulse tracing was damped. Six patients had continuous infusion of solution via Intrallo. The total volume of flush solution was recorded for every patient.

All pressures were recorded prior to anesthesia, during the procedure, and after operation until cannula removal. Blood pressures from the arm were taken by cuff and read from the sphygmomanometer on the anesthesia machine. Blood pressures from the dorsalis pedis artery were determined simultaneously and read from an E for M monitor Model IR-4H. The sphygmomanometer and strain gauge had been calibrated against mercury prior to use.

* Third-year Resident, Anesthesia and Operative Service, Brooke Army Medical Center, Fort Sam Houston, Texas 78234.

† Assistant Chief of Anesthesia and Research Director, Anesthesia and Operative Service, Brooke Army Medical Center, Fort Sam Houston, Texas 78234. Present address: Assistant Professor of Anesthesiology, University of Virginia Medical Center, Charlottesville, Virginia 22903.

Accepted for publication August 24, 1975. Presented in part at the Gulf Coast Residents Conference at Gainesville, Florida, May 25, 1975.

The opinions or assertions contained herein are the private views of the authors and are not to be interpreted as official or reflecting the view of the Department of the Army or the Department of Defense.

Address reprint requests to Dr. Miller.

While the cannula was in place, the foot was checked for color, pulses, signs of infection or hematoma formation, and signs of ischemia or embolization, and the patient was queried as to discomfort or other sensations. After cannula removal, all patients were followed by directional Doppler measurements and visual inspection of the foot. Readings were made on relative flows in both feet and an arm employing a 15-degree angle pencil probe transcutaneously. Blood pressure and pulse magnitude were also recorded. All readings were compared with those obtained before anesthesia, and the cannulated artery was compared with the non-cannulated dorsalis pedis artery. Patients were followed daily while in the hospital and seen weekly for four weeks after discharge whenever possible. Arterial occlusion was considered present if compression of the posterior tibial artery resulted in more than 15-second blanching of the great and second toes in the test described above. Occlusion was confirmed by use of the directional Doppler demonstrating retrograde flow distally with loss of the signal upon occlusion of the posterior tibial artery.

RESULTS

Twenty-six of 30 cannulas were successfully passed into the dorsalis pedis artery on the first attempt. Average cannulation time was 8.22 hours (range 2–25 hours). Two patients experienced complete thrombosis. In one of these patients, the skin over the instep of the foot became mottled two days after cannula removal. This cleared spontaneously over a three-day period without residual signs or symptoms. In both cases of complete thrombosis, retrograde flow distal to the area of occlusion was demonstrated with the directional Doppler. The Doppler technique showed decreased flow in one additional patient.

When cuff systolic pressures were compared with monitor systolic pressures, the monitor readings from the dorsalis pedis arterial lines tended to be approximately 10 torr higher. Figure 1 demonstrates this relationship. When cuff diastolic pressures were compared with monitor diastolic pressures, the monitor readings were 15–20 torr lower. Figure 2 demonstrates this relationship.

Two patients were cannulated on two sepa-

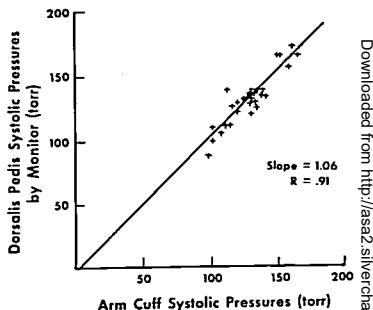


FIG. 1. Comparison of systolic pressures taken by monitor and by arm cuff.

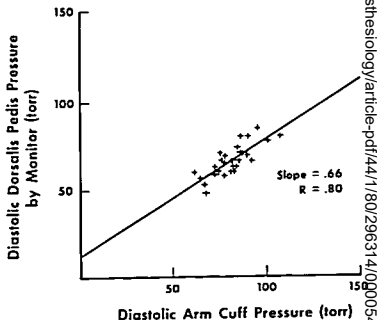


FIG. 2. Comparison of diastolic pressures taken by monitor and by arm cuff.

rate occasions. Patient HM had the right dorsalis pedis artery cannulated on two separate occasions and patient JD had the right dorsalis pedis artery cannulated on one day and the left on another. Systolic pressures by cuff and arterial line correlated well on both occasions.

DISCUSSION

Many complications from radial-artery cannulation or puncture have been reported. Hematoma and ecchymosis formation occurred in approximately 50 per cent of radial-artery cannulations as evaluated by Brown

Downloaded from <http://asa2.silverchair.com/anesthesiology/article-pdf/44/1/80/296314/0000542-19760100-00022.pdf> by guest on 18 April 2024

*et al.*³ In radial arteries cannulated less than 24 hours thrombosis or diminished flow developed in approximately 20–25 per cent following cannula removal.^{3,4} In addition, expanding aneurysm of the radial artery after repeated puncture,⁵ gangrene of the hand after brachial-artery or radial-artery cannulation,^{6,7} and possible cerebral embolism following flushing of a radial arterial cannula have been reported.⁸⁻¹⁰

The dorsalis pedis artery would seem to be a likely alternative to the radial or ulnar artery for intra-arterial monitoring. There is usually good collateral flow to the foot, primarily by the posterior tibial artery and, to a lesser extent, by the peroneal artery.^{11,12} This method of monitoring may not be suitable for all patients, however. The dorsalis pedis artery has been found to be non-palpable in approximately 5 per cent of children¹³ and absent in approximately 12 per cent of adults.¹⁴ In addition, in patients with severe occlusive vascular disease arterial pressures in the foot may not be representative of those in the upper extremity.^{15,16} Finally, Spoerel *et al.* demonstrated that the main blood supply to the toes comes from the dorsalis pedis artery in approximately 16 per cent of cases.¹

Spoerel *et al.*,¹ Johnstone and Greenhow,² and Furman *et al.*¹⁷ report the results of dorsalis pedis monitoring to be reliable. This study helps to confirm these prior reports by demonstrating an *r* value of 0.91 in comparing dorsalis pedis arterial systolic with arm systolic pressures and an *r* value of 0.8 when diastolic pressures are compared. Although the actual readings for the dorsalis pedis and arm cuff pressures were not the same, the difference between these readings was fairly consistent throughout the recordings for a given patient. Spoerel *et al.*, in a study of simultaneously cannulated radial and dorsalis pedis arteries, found that, under normotensive conditions, the mean pressure in the dorsalis pedis artery is approximately 4 torr higher.¹

In addition to the reliability of the measurement, a lower incidence of thrombosis of dorsalis pedis arteries when compared with radial arteries cannulated for the same length of time is important. Brown *et al.*³ reported an incidence of decreased flow in radial

arteries after cannulation of 20 per cent, and Bedford *et al.*⁴ reported a thrombosis rate of 25 per cent. In both groups, the radial artery was cannulated less than 24 hours. In the present study, cannulation of the dorsalis pedis artery for less than 24 hours resulted in thrombosis in 6.7 per cent of the patients. The patients in this study and those in Bedford's group were followed for at least a week after cannulation, and were evaluated by both physical examination and Doppler technique. As pointed out by Bedford *et al.*,⁴ almost all thromboses will occur within seven days after cannulation.

The reason or reasons for the lower incidence of thrombosis of the dorsalis pedis artery observed in this study are only speculative at this point. Brown and co-workers could demonstrate no difference between the incidences of thrombosis with polyvinylchloride and Teflon catheters following radial-artery cannulation.³ However, Downs *et al.*⁸ found a lower incidence of thrombosis in arteries cannulated with a Teflon catheter compared with polypropylene catheters. Jones and Crain¹⁸ demonstrated a significant increase in thrombosis of veins cannulated with polyvinylchloride catheters compared with Teflon catheters. In our study, we used a 20-gauge Teflon catheter.

In summary, percutaneous cannulation of the dorsalis pedis artery has been shown to be easy to perform, reliable, and relatively safe for intra-arterial monitoring. The incidence of thrombosis was significantly less than that in radial arteries after cannulation. No major complication was associated with 30 percutaneous cannulations of the dorsalis pedis artery in this study.

REFERENCES

1. Spoerel WE, Deimling P, Aithen R: Direct arterial pressure monitoring from the dorsalis pedis artery. *Can Anaesth Soc J* 22:91–99, 1975
2. Johnstone RE, Greenhow DE: Catheterization of the dorsalis pedis artery. *ANESTHESIOLOGY* 39:654–655, 1973
3. Brown AE, Sweeney DB, Lumley J: Percutaneous radial artery cannulation. *Anesthesia* 24:532–536, 1969
4. Bedford RF, Wollman H: Complications of percutaneous radial artery cannulation. *ANESTHESIOLOGY* 38:228–236, 1973

5. Mathieu A, Dalton B, Fischer JE, et al: Expanding aneurysm of the radial artery after frequent puncture. *ANESTHESIOLOGY* 38:401-403, 1973
6. Dalton B, Laver MB: Vasospasm with an indwelling radial artery cannula. *ANESTHESIOLOGY* 34:194-197, 1971
7. Katz AM, Birnbaum M, Moylan J, et al: Gangrene of the hand and forearm: A complication of radial artery cannulation. *Crit Care Med* 2:270-272, 1974
8. Downs JB, Rackstein AD, Klein EF, et al: Hazards of radial artery catheterization. *ANESTHESIOLOGY* 34:194-197, 1971
9. Lowenstein E, Little JW III, Hing HL: Prevention of cerebral embolization from flushing radial artery cannulas. *N Engl J Med* 285:1414-1416, 1971
10. Gan D, Mallick HP, Brewis RAL, et al: Cerebral damage from declotting Scribner shunts. *Lancet* 2:77-79, 1969
11. Conrad MC: *Functional Anatomy of the Circulation to the Lower Extremities*. Chicago, Year Book Medical Publishers, 1971
12. Gray H: *Anatomy of the Human Body*. Twentieth edition. Philadelphia, Lea and Febiger, 1973
13. Barnhorst BA, Boener HB: Prevalence of congenitally absent pedal pulses. *N Engl J Med* 278:264-265, 1968
14. Huber JF: The arterial network supplying the dorsum of the foot. *Anat Rec* 80:373, 1941
15. Carter SA: Response of ankle systolic pressure to leg exercise in mild or questionable arterial disease. *N Engl J Med* 287:578-582, 1972
16. May AG, Van de Berg L, DeWeese JA, et al: Critical arterial stenosis. *Surgery* 54:250-259, 1963
17. Furman EF, Hairabet JK, Roman DG: The use of indwelling radial artery needles in paediatric anesthesia. *Br J Anaesth* 44:531-532, 1972
18. Jones MV, Craig DB: Venous reaction to plastic intravenous cannulae, influence of cannula composition. *Can Anaesth Soc* 19:491, 1972

Hazards of Anesthesia and Operation in Maple-syrup-urine Disease

ADRIAN DELANEY, LCDR, MC USN,* AND THOMAS J. GAL, LCDR, MC USNR†

Maple-syrup-urine disease, or branched-chain ketonuria, is a metabolic disorder involving the branched-chain amino acids leucine, isoleucine, and valine (fig. 1).¹ The metabolic defect appears to involve oxidative decarboxylation of the metabolites, alpha keto acids (fig. 2). The result is an accumulation of these keto acids and the amino acids themselves in blood and urine. The latter has the odor of maple syrup. This same sweet caramel-like odor is also apparent in other secretions such as perspiration and cerumen. Although the exact source of this is unknown, the alpha keto acids also have a similar odor in small amounts. Despite the fact that all

of the metabolites proximal to the block accumulate, the deleterious effects seem most clearly related to elevated levels of the amino acids themselves. The characteristic clinical picture appears within the first five days of life: poor feeding habits, progressing to lethargy and convulsions. The diagnosis is suggested by the characteristic odor of the urine and confirmed by high blood levels of branched-chain and alpha keto acids, and demonstration of the metabolic block in peripheral leukocytes or fibroblasts in the skin.² Although dietary therapy is associated with prolongation of survival, mental retardation and permanent neurologic signs usually result. This is largely because most foods have a high content of branched-chain amino acids, and a normalized diet with stringent withdrawal of the compounds is not easily achieved.

Since the initial description of maple-syrup-urine in 1954, nearly 100 cases have been reported. The frequency of this disease with severe symptoms is estimated to be about one in 250,000 live births.³ Recently, however,

* Resident in Anesthesia.

† Staff Anesthesiologist. Present address: Assistant Professor, Department of Anesthesiology, University of Virginia Medical Center, Charlottesville, Virginia 22901.

Received from the Department of Anesthesia, Naval Regional Medical Center, Portsmouth, Virginia 23708. Accepted for publication September 6, 1975.

Address reprint requests to Dr. Gal.

Downloaded from <http://ajph.aaph.org/> by guest on 18 April 2024