

9. Crawford JS, Burton M, Davies P: Anaesthesia for section: further refinements of a technique. *Br J Anaesth* 45:726-732, 1973
10. Kalappa R, Ueland K, Hansen JM: Maternal acid-base status during cesarean section under thiopental, N₂O and succinylcholine anaesthesia. *Am J Obstet Gynecol* 109:411-417, 1971
11. Stenger V: A study of the acid base balance of the fetus and the newborn and its relation to the mother. *Am J Obstet Gynecol* 90: 625-629, 1964
12. Bowe ET, Beard RW, Finster M, et al: Reliability of fetal blood sampling. Maternal-fetal relationships. *Am J Obstet Gynecol* 107:279-287, 1970
13. Drage JS, Kennedy C, Schwarz BK: Apgar score as an index of neonatal mortality. *Obstet Gynecol* 24:222-230, 1964
14. Benaron HBW: Effects of anoxia during labor and immediately after birth on the subsequent development of the child. *Am Obstet Gynecol* 80:1129-1142, 1960
15. Saling E: Technik der endoskopischen mikrobloodentnahme am feten. *Geburtshilfe Frauenheilkd* 24:464-469, 1964
16. Crawford JS: Awareness during operative obstetrics under general anaesthesia. *Br Anaesth* 43:179-184, 1971
17. Moir DD: Anaesthesia for caesarian section. An evaluation of a method using low concentrations of halothane and 50 per cent oxygen. *Br J Anaesth* 42:136-142, 1970
18. Sampson JJ, Rose EM, Quinn R: Estimation of the work of obstetric labor and its significance in heart disease. *Am J Obstet Gynecol* 49:719-734, 1945
19. Kerr MC, Scott DB, Samuel E: Studies of the inferior vena cava in late pregnancy. *Br Med J* 1:532-533, 1964

An Unusual Ocular Complication after Anesthesia

ROBERT B. RICHARDSON, M.D.,* CHARLES M. McBRIDE, M.D.,†
RALPH G. BERKELEY, M.D.,‡ WILLIAM S. DERRICK, M.D.§

Diminished vision in a patient after anesthesia is of interest and concern to the anesthesiologist.¹ This report describes the occurrence of acute epithelial edema of the cornea and marked decrease in visual acuity after general anesthesia in a patient with previously undetected endothelial dystrophy of the cornea, a complication heretofore unreported, to our knowledge.

REPORT OF A CASE

A 60-year-old woman weighing 65 kg was admitted to the hospital for a right iliac node dissection and perfusion. She had had a malignant melanoma removed from her right leg 6 weeks earlier with general anesthesia. Eight months prior to the present admission, she had had a bilateral Keller operation for hallux valgus with general anesthesia. Physical examination, including examination of sclerae, conjunctivae, and pupils, revealed no abnormality. Complete blood count, activated coagulation time, total serum proteins, blood urea nitrogen, and serum calcium were within normal ranges. Urine, chest roentgenogram, and electrocardiogram were normal.

Preoperative medication was meperidine (Demerol), 75 mg, hydroxyzine (Vistaril) 35 mg, and atropine, 0.4 mg, administered im 45 minutes preoperatively. Induction of anesthesia was accomplished with thiopental (Pentothal) 250 mg iv, and nitrous oxide, 66 per cent in oxygen, and halothane 1.0 per cent. Endotracheal intubation was accomplished easily following succinylcholine (Anectine) 50 mg, given iv. Five per cent boric acid ophthalmic ointment was instilled into the conjunctival sac of each eye and the lids were closed.

Following a right iliac node dissection, the patient was given heparin, 200 units/kg. Catheters were placed in the external iliac artery and vein and passed to mid-thigh. The right lower extremity was isolated by an Esmarch tourniquet and the patient was put on a pump with a bubble oxygenator

* Associate Anesthesiologist, M.D. Anderson Hospital; Assistant Professor of Anesthesiology, University of Texas at Houston.

† Associate Surgeon, M. D. Anderson Hospital; Associate Professor of Surgery, University of Texas at Houston.

‡ Chief, Ophthalmology Services, M. D. Anderson Hospital; Clinical Assistant Professor of Ophthalmology, University of Texas at Houston.

§ Head, Department of Anesthesiology, M. D. Anderson Hospital; Professor of Anesthesiology, University of Texas at Houston.

Received from the University of Texas System Cancer Center, M. D. Anderson Hospital and Tumor Institute, Houston, Texas 77025. Accepted for publication February 9, 1975.

Address reprint requests to Dr. Richardson, Department of Anesthesiology, M. D. Anderson Hospital, G-415, 6723 Bertner Avenue, Houston, Texas 77025.

that had been primed with saline solution and blood. A systemic leak from the isolated extremity was detected with the use of radioactive iodinated serum albumin, $2 \mu\text{Ci}$, injected into the pump circuit and monitored with a radioactivity counter over the ventricular blood volume. Perfusion was with melphalan, (Alkeran), 120 mg, at 39°C for 45 minutes, followed by Dextran 70, 750 ml, washout. The leg was then refilled with 500 ml of heparinized blood. Bypass was discontinued and protamine, 4 mg/kg, given to neutralize systemic heparin. The total systemic drug leak was 2 per cent. Anesthesia was maintained with nitrous oxide, 60 per cent, and halothane 0.5–1.0 per cent. Ventilation was manually assisted throughout the procedure, which lasted 5½ hours.

Upon awakening from anesthesia approximately an hour after admission to the recovery room, the patient complained of severe frontal headache, nausea, blurred vision, and pain and lacrimation in both eyes. The conjunctivae were reddened but not edematous. Pupils were equal and pinpoint, and visual acuity was limited to finger counting at one foot. Intraocular pressures were soft by finger tension. A fluorescein-stripe test was negative in both eyes, without evidence of corneal abrasion. Although meperidine, 75 mg, im, had already been given for postoperative pain, further administration of narcotics was interdicted and the patient slept following administration of diazepam (Valium) 10 mg, iv.

On the morning of the first postoperative day, the patient's headache and tearing had subsided. However, she continued to complain of blurred vision, which she described as "like being in a fog." She could read one-inch print at a distance of one foot. In the afternoon, visual acuity was 20/25 in each eye with correction. Intraocular pressure was 12 torr in both eyes by applanation tonometry (normal 10–22 torr). Slit-lamp examination revealed Fuchs' endothelial dystrophy with marked stromal edema involving the central areas of both corneas and slight bedewing of the left epithelium. Vision rapidly improved over the next two days with use of dexamethasone (Decadron), 0.1 per cent, eye drops. The patient had been unaware of her corneal disease prior to this episode of acute epithelial edema.

Three months after discharge from the hospital the patient returned for postsurgical evaluation. She had continued to use the dexamethasone eye drops and reported having better vision since leaving the hospital then she had had before operation. Visual acuity was: right eye 20/25, left eye 20/20 with correction. Slit-lamp photographs were made of both corneas (fig. 1).

DISCUSSION

Fuchs' dystrophy is a chronic, slowly progressive degeneration of the corneal endothelium, characterized initially by central guttata and thickening of Descemet's membrane of

the cornea, which results in decompensation of corneal physiology and eventual overhydration of the stroma and epithelium.² Although Lorenzetti *et al.*³ reported an incidence of cornea guttata of 66 per cent in the age group 40–99 years, it is impossible to correlate precisely the extent of the guttata and the amount of endothelial dysfunction or to predict the interval between onset of guttata and the appearance of epithelial edema.⁴ The combination of endothelial damage and increased intraocular pressure is a major cause of acute epithelial edema. Moreover, in affected persons, when the eyes are closed during sleep the edema increases, since there is no loss of fluid from the cornea by evaporation. As the day wears on and the lids are open more evaporation from the epithelial surface occurs and the edema may diminish.⁴ Although factors known to increase intraocular pressure during anesthesia include venous congestion of orbital veins as a result of coughing, straining or breath-holding⁵; succinylcholine⁶ and hypercapnia,⁷ our patient had not had clinically evident corneal edema during either of her two previous operations. In view of the high incidence of cornea guttata in the population, and since we have seen no previous report of this complication following anesthesia in patients with endothelial dystrophy, we must assume that anesthesia-related factors were not the most likely cause of corneal edema in the patient.

Certain metabolic inhibitors can lead to corneal edema. The cardiac glycoside, ouabain (g-strophanthin), at a concentration of $3 \times 10^{-7}\text{M}$ is known to cause acute corneal edema in experimental animals,⁸ and small topical doses of nitrogen mustard (mechlorethamine, HN_2) can cause increased permeability of the endothelium resulting in corneal edema without producing histologic changes.⁹ Although our search of the literature failed to reveal any report on the effect of melphalan on the corneal endothelium, Ogawa *et al.*¹⁰ found 37 per cent survival of human bone marrow cells following exposure in culture for one hour to $2.2 \times 10^{-6}\text{M}$ melphalan. Assuming a normal blood volume of 4.2 liters in our patient,¹¹ the 2 per cent systemic leak that occurred during perfusion represents a melphalan concentration of $1.87 \times 10^{-6}\text{M}$. Moreover, since the half-life of melphalan in blood

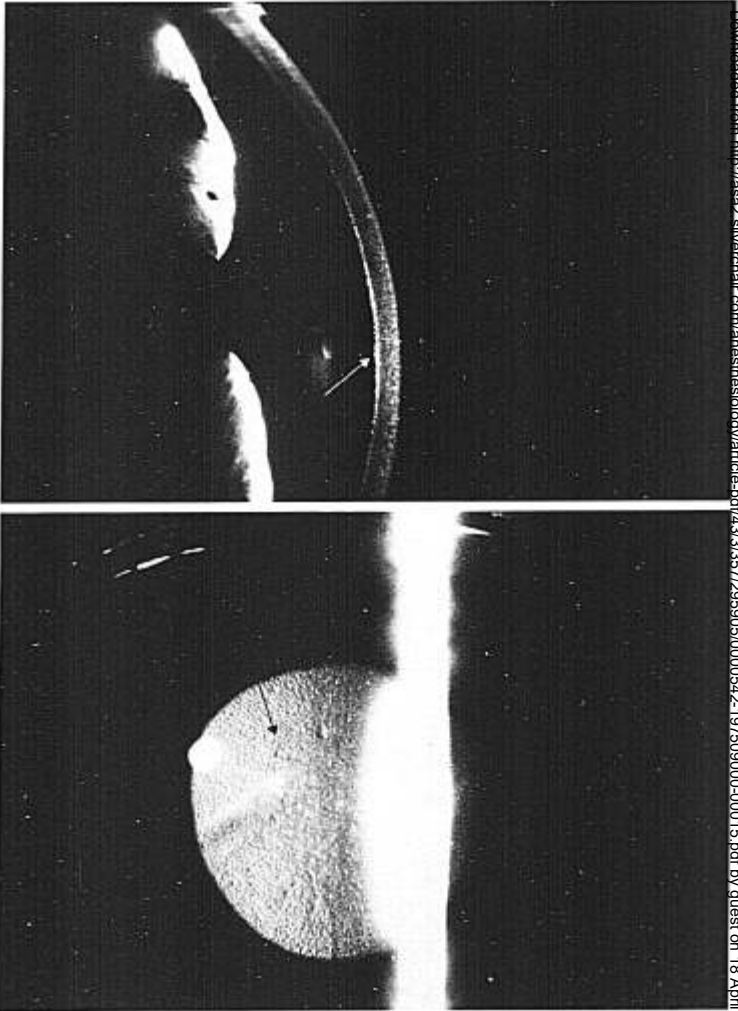


FIG. 1. Slit-lamp photographs of the patient's corneas. Lateral view of right cornea (above) showing central guttata (arrow) ($\times 2.5$ before reproduction). Frontal view of left cornea (below) showing characteristic beaten-silver appearance of Fuchs' dystrophy (arrow) ($\times 2$ before reproduction).

Downloaded from <http://asa2.silverchair.com/anesthesiology/article-pdf/43/3/357/295905/0000542-197509000-00015.pdf> by guest on 18 April 2024

at 37 C is 105–120 min,¹² it is conceivable that the drug could have reached the endothelial cells, which were already compromised, and produced temporary changes that resulted in acute failure to maintain normal corneal hydration, with resultant onset of edema.

Although a single case fails to provide conclusive evidence, the available data suggest that acute corneal edema in our patient probably resulted from cytotoxic effects of melphalan, although the condition, once initiated, could have been exacerbated by anesthesia-related factors and prolonged closure of the eyes.

The authors thank Dr. Stuart O. Zimmerman, Professor of Biomathematics, for advice and criticism, Johnny Justice, Jr., for slit-lamp photography of the patient's corneas, and J. E. Cirincione for photographic assistance.

REFERENCES

1. Wylie WD, Churchill-Davidson HC: Neurological and ophthalmic complications of anesthesia, *A Practice of Anaesthesia*. Third edition. Chicago, Year Book Medical Publishers, 1972, pp 1258–1268
2. Goldman JN, Kuwabara T: Histopathology of corneal edema, *Corneal Edema*. International Ophthalmology Clinics, Edited by CH Dohlman. Boston, Little, Brown and Company, 1968, pp 561–579
3. Lorenzetti DWC, Uotila MH, Parikh N, et al: Central cornea guttata: Incidence in the general population. *Am J Ophthalmol* 64: 1155–1158, 1967
4. Boruchoff SA: Clinical causes of corneal edema. *Corneal Edema*. International Ophthalmology Clinics. Edited by CH Dohlman. Boston, Little, Brown and Company, 1968, pp 581–600
5. Macri FJ: Vascular pressure relationships and the intraocular pressure. *Arch Ophthalmol* 65:571–574, 1961
6. Schwartz H, de Roeth A: Effect of succinylcholine on intraocular pressure in human beings. *ANESTHESIOLOGY* 19:112–113, 1958
7. Beaugie A, Samuel JR: Some observations on the effect of carbon dioxide on intraocular pressure in man. *Br J Anaesth* 45:119, 1973
8. Trenberth SM, Mishima S: The effect of ouabain on the rabbit corneal endothelium. *Invest Ophthalmol* 7:44–52, 1968
9. Maumenee AE, Scholz RO: The histopathology of the ocular lesions produced by the sulfur and nitrogen mustards. *Bull Johns Hopkins Hosp* 82:121–147, 1948
10. Ogawa M, Bergsagel DE, McCulloch EA: Sensitivity of human and murine hemopoietic precursor cells to chemotherapeutic agents assessed in cell culture. *Blood* 42:851–856, 1973
11. Moore FD: The blood volume in health, *Metabolic Care of the Surgical Patient*. Philadelphia, W. B. Saunders, 1959, p 146
12. Williams K: Table 14, *Biological Alkylating Agents*. Edited by WCJ Ross. London, Butterworths, 1962, p 98

A Coagulation Disorder during Reanastomosis of Small-intestinal Bypass

ROBERT W. VAUGHAN, M.D.,* AND LESLIE WISE, M.D.†

Jejunioileal bypass is frequently employed for the treatment of massive exogenous obesity. Unfortunately, some intestinal bypass patients experience persistent severe diarrhea with electrolyte disturbances. Other

serious complications also occur, namely, renal calculi, nephrocalcinosis, cholelithiasis, gastric hyperacidity, peripheral neuropathy, pulmonary embolism, vitamin deficiencies, hepatic steatosis, cirrhosis, and in some cases, hepatic failure.¹

Reanastomosis of the small bowel to restore its integrity may become necessary in patients with severe hepatic dysfunction. This report emphasizes a potentially lethal coagulopathy that was encountered in such a patient.

* Associate Professor of Anesthesiology.

† Associate Professor of Surgery.

Received from the Departments of Anesthesiology and Surgery, Washington University School of Medicine, 660 South Euclid Avenue, St. Louis, Missouri 63110. Accepted for publication February 9, 1975.

Address reprint requests to Dr. Vaughan.