

9. Drake CG: Further experience with surgical treatment of aneurysm of the basilar artery. *J Neurosurg* 29:372-392, 1968
10. Drake CG: The surgical treatment of aneurysms of the basilar artery. *J Neurosurg* 29:436-446, 1968
11. Gissen AJ, Matteo RS, Housepian EM, et al: Elective circulatory arrest during neurosurgery for basilar artery aneurysms. *JAMA* 207:1315-1318, 1969
12. Kelman GR, Nunn JF: Nomograms for correction of blood P_{aO_2} , P_{aCO_2} , pH and base excess for time and temperature. *J Appl Physiol* 21 (5):1484-1490, 1966
13. Small JH, Stephenson SEC: Circulatory arrest in neurosurgery. *Lancet* i:569-570, 1966
14. Campkin TV: Moderate hypothermia and circulatory arrest for neurosurgical operations. *Br J Anaesth* 37:528-532, 1965
15. Small JM, Stevenson SC, Campkin TV, et al: Elective circulatory arrest by artificial pacemaker. *Lancet* i:570-572, 1966
16. Campkin TV, Dallas SM: Elective circulatory arrest in neurosurgical operations. *Br J Anaesth* 40:527-531, 1968
17. Rovit RL: Operative hypotension for intracranial vascular surgery using pacemaker induced ventricular tachycardia. *J Neurosurg* 35:15-58, 1971
18. Fein JM, Weinstein J, McVeety H, et al: Pacemaker induced hypotension for intracranial aneurysm surgery. *Arch Surg* 107:374-378, 1973
19. Bendixen HH: Pacemaker induced hypotension (editorial). *Arch Surg* 107:363, 1973

Arytenoid Cartilage Dislocation Following Prolonged Endotracheal Intubation

YUPADI PRASERTWANITCH, M.D.,* JOHN J. H. SCHWARZ, M.D.,† LEROY D. VANDAM, M.D.†

Well-known laryngeal complications of endotracheal intubation include mucous membrane abrasion, glottic and subglottic edema of varying severity, and formation of laryngeal granuloma. We report here an unusual complication, arytenoid cartilage dislocation, in a patient with a complicated history of heart disease and prolonged intubation following open-heart surgery.

REPORT OF A CASE

A 61-year-old Caucasian man was transferred from another hospital for cardiac catheterization. He had had renal failure at the age of 12 years and rheumatic heart disease in childhood, with an asymptomatic residual heart murmur of mitral regurgitation. About four years prior to admission hypertension had been noted and treatment with

digoxin and ethacrynic acid begun because of heart failure.

Six weeks prior to admission, the patient sustained a myocardial infarction, which was treated at another hospital, followed by pneumonitis and peripheral thrombophlebitis, which were treated with Dicumarol; however, treatment was discontinued when gastric bleeding occurred. The patient was readmitted to the same hospital five weeks later with a second myocardial infarction, accompanied by ventricular tachycardia which progressed to ventricular fibrillation. Resuscitation which included external cardiac massage and nasotracheal intubation was successful after 1½-2 hours. Before his transfer to this hospital an attempt to extubate the trachea was unsuccessful because of development of pulmonary edema.

On admission the patient was found to have a flail chest, probably the result of chest compression, infiltration of the right lower lobe, and collapse of the right upper lobe. Mechanical ventilation of the lungs with positive end-expiratory pressure was necessary for a few days to overcome hypoxia. Nasotracheal intubation was maintained for a total of 11 days.

Cardiac catheterization revealed almost complete obstruction of all main coronary vessels, as well as aortic regurgitation and aortic stenosis. After still another episode of pulmonary edema, the patient underwent coronary-artery bypass grafting and aortic valvuloplasty three weeks after admission. Tracheal intubation was easily done using a plastic tube of 8.5-mm internal diameter. The patient fared well during the operation, which lasted about 7½ hours. Upon extubation of the trachea the following morning, hoarseness of voice, thought to be the result of laryngeal

* Clinical Fellow in Anaesthesia, Harvard Medical School, Junior Assistant Resident in Anaesthesia, Peter Bent Brigham Hospital.

† Instructor in Otolaryngology, Harvard Medical School, Junior Associate in Surgery (Otolaryngology), Peter Bent Brigham Hospital.

‡ Professor of Anaesthesia, Harvard Medical School, Anaesthesiologist-in-Chief, Peter Bent Brigham Hospital.

Received from the Departments of Anaesthesia and Surgery (Otolaryngology), Harvard Medical School and Peter Bent Brigham Hospital, Boston, Massachusetts 02115. Accepted for publication June 25, 1974.

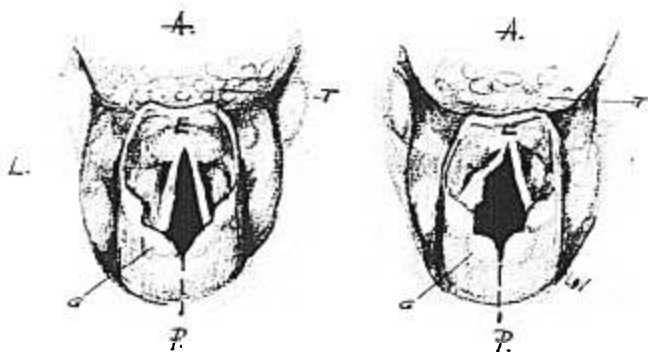


FIG. 1. Normal glottis on the left (L), abnormal on the right. A, anterior; P, posterior; G, glottis. Dotted line in the center. Note abducted distorted left cord indicative of arytenoid dislocation. (Drawing from a sketch made at laryngoscopy.)

edema, was noted. When hoarseness persisted for three weeks and the patient could not talk above a whisper, indirect laryngoscopy was performed, revealing dislocation of the left vocal cord. The dislocation presumably occurred at the time of the second intubation. Treatment planned was either intracordal injection of Teflon paste or reconstructive surgery following full recovery from the cardiac operation.

DISCUSSION

To our knowledge, arytenoid dislocation following endotracheal intubation has not hitherto been reported. J.J.H. Schwarz and W.W. Montgomery have seen this injury in several patients with histories of repeated recent intubations undergoing open-heart surgery followed by prolonged intubation. According to them, fracture or dislocation of the arytenoid cartilage can be caused by trauma caused by the laryngoscope in performing both diagnostic laryngoscopy and laryngoscopy for endotracheal intubation. The tracheal tube *per se* seldom, if ever, is the cause of the injury. Thus, direct trauma caused by endoscopy can be avoided by proper technique. The clinical picture of fracture or dislocation of the arytenoid cartilage is essentially that of a weak voice with antecedent history of laryngeal instrumenta-

tion or intubation. On examination, as seen in this patient, the affected arytenoid cartilage is dislocated laterally or posterolaterally (fig. 1). The overlying mucosa is sometimes denuded, with whitish cartilage protruding. The cricoarytenoid joint is dislocated, and the true cord on the affected side is held in abduction, unable to appose the opposite with attempts at phonation. The affected cord moves only slightly in adduction, and the injury prevents the normal range of vibratory motion. Treatment is afforded by reduction and cricoarytenoid arthrodesis, as described by Montgomery.¹

In our patient, presence of the endotracheal tube initially for 11 days while he was moving about and being moved may have caused damage, but not to the extent of dislocation. Within 23 days, reintubation took place. Although it was virtually nontraumatic, a period of 24 hours was apparently enough to dislocate the cartilage, perhaps enhanced by coughing with suctioning, movement of the larynx with each breath, and turning from side to side for postural drainage.

REFERENCES

1. Montgomery WW: Surgery of the Upper Respiratory System. Volume 2. Philadelphia, Lea and Febiger, 1973, pp 458-466

§ Personal communication.