

## Clinical Workshop

C. PHILIP LARSON, JR., *Editor*

### Electrocution in the Operating Room

DAVID H. ATKIN, M.D.,\* AND LOUIS R. ORKIN, M.D.†

This report of an electric-shock injury to a patient and her physician is presented to alert others to the possibility of a similar occurrence.<sup>1,2</sup> To our best knowledge, these circumstances have not been previously reported, and analysis of these events suggests certain precautions.

#### REPORT OF INCIDENT

A 57-year-old woman was brought to the operating room for surgical repair of an ankle fracture under spinal anesthesia. The ground plate of an electrocautery unit was placed beneath the patient's buttocks. Skin surface-contact electrodes for EKG monitoring were placed one on each shoulder and a third on the precordium. The monitor showed a normal lead I tracing. Operation was begun and the electrocautery was used without mishap.

During operation, the anesthesiologist was annoyed by interference on the EKG tracing, which she attributed to a faulty wall-socket connection. A nurse disconnected the power plug of the monitor from its wall receptacle and reconnected it to a different receptacle. During the transfer the anesthesiologist was palpating the patient's temporal artery. When the power connection was made, the anesthesiologist felt a shock in the hand contacting the patient, causing reflex withdrawal. The patient's body made a sudden jerking movement. The power connection of the EKG monitor

was immediately disconnected. The anesthesiologist recovered quickly and found that the patient was cyanotic, apneic, and pulseless. Oxygen was administered by controlled ventilation with a mask and closed-chest cardiac massage was instituted. A spontaneous peripheral pulse was palpable after several seconds of massage, the arterial pressure returned, and the operation was completed. The patient and the anesthesiologist recovered fully with no untoward sequelae.

The EKG monitor and the power receptacles in the operating room were inspected. Figure 1A shows the proper wiring for a power plug and figure 1B shows the actual wiring of the plug. The chassis ground is connected to the "neutral" prong (no. 1) rather than the "ground" prong (no. 3). Figure 2A shows the usual wiring for a wall receptacle, and this was how the first receptacle was wired. Figure 2B shows the reversed-polarity wiring of the second receptacle.

When the faulty plug was used with the first receptacle, the chassis was connected to the neutral side of the power line. The EKG "ground" lead was thus connected to the neutral line. Since the voltage difference between neutral and ground is of the order of one volt in this system, no serious shock occurred. When the faulty plug was connected to the reversed polarity of the second receptacle, the chassis, and hence the EKG ground lead, was at about 110 volts with respect to true ground. Figure 3 shows the complete circuits causing

\* Resident.

† Professor and Chairman.

Received from the Department of Anesthesiology, Albert Einstein College of Medicine, Bronx, New York 10461. Accepted for publication July 25, 1972.

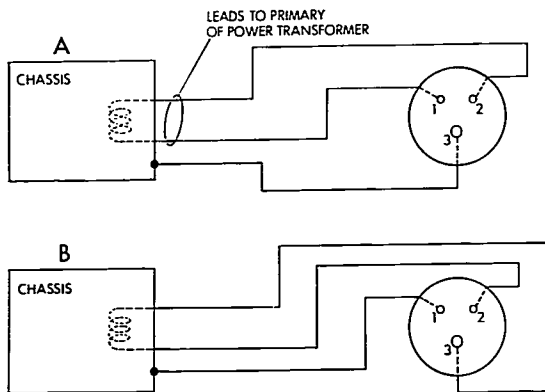


FIG. 1. A, correct wiring; B, faulty wiring.

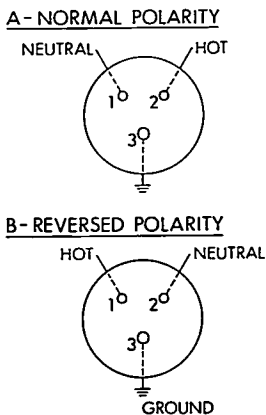


FIG. 2. Wiring of power receptacles. Positions 1, 2, and 3 correspond to those in figures 1 and 3. A, first receptacle—normal polarity; B, second receptacle—note reversed polarity of positions 1 and 2.

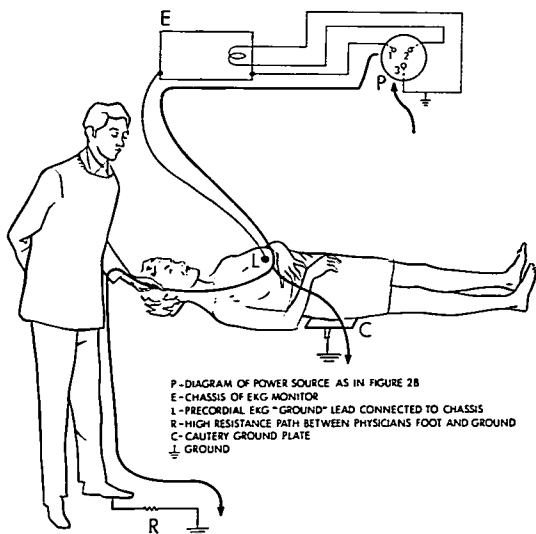
the shocks to both the patient and the physician. Between the precordial EKG lead and the electrocautery ground plate at the buttocks, 110 volts ac developed, with a resistance small

enough to permit sufficient current flow to electrocute the patient. The path through the physician was of much higher resistance. This was because of high resistance contact between her skin and the patient's skin, high resistance contact to the conductive floor, and high resistance from the conductive floor to the true ground. The intensity of current through this path was thus limited to several milliamperes, causing only discomfort. The physician could have suffered a more severe shock had she provided lower resistance to ground through another chassis, for example, a suction machine.

#### DISCUSSION

Because the improperly wired EKG monitor had been in use for some time without a shock reported, we thought that the receptacle with reversed polarity must have been the only one so wired in the operating rooms. The building code for this city has no requirements for standardized-polarity wiring in hospitals, and at the time this hospital was built there was no requirement for separate ground conductors; conduits were used instead. We tested all receptacles and found that 20 per cent of those in the operating rooms had reversed polarity, which probably had been present for the 15 years since the hospital was built. This has since been corrected.

FIG. 3. Pathways of shock current. The heavy line traces the completed circuits between prongs 1 and 3. Both patient and physician provide connections to ground. About 110 volts ac existed between prongs 1 and 3, i.e., between precordium and ground plate.



Shocks from this monitor probably were not reported sooner because the oscilloscope trace did not appear when it was connected to a reversed-polarity source. Under these circumstances, no power was delivered to the transformer of the equipment. On such occasions the monitor might be replaced with another, the user assuming that it was out of order. Subsequently, the technician testing the monitor on a normally-wired power receptacle could conclude that it was working properly. We believe that this explains how the equipment was used repeatedly without shocking a patient. The unusual factor in this incident was that the monitor was already in contact with the patient when the second power connection was made. The electric shock occurred immediately, before the absence of the oscilloscope trace could be noted.

Positioning of electrodes and other electrical contacts should take into consideration the possible current paths of accidental leaks. The paths should be arranged so as to favor conduction through an extremity rather than

through the trunk, especially the precordium. The "left leg" lead of the EKG in this case was attached precordially. During "lead 1" monitoring, this precordial lead becomes "grounded" to the chassis of this type of monitor and, therefore, was the electrode supplying the line voltage to the patient. It is recommended that precordial leads for EKG monitoring be avoided and that only limb leads be used.

Isolated power systems are now being used in many patient-care areas. The isolation transformer and the line-isolation monitor offer protection against macroshock hazards such as the one reported here. The leak from power line to chassis is detected by this system, providing a warning before the equipment is used on a patient.

#### REFERENCES

1. Bruner JMR: Hazards of electrical apparatus. *ANESTHESIOLOGY* 28:396-425, 1967
2. Hopps JA: Shock hazards in operating rooms and patient-care areas. *ANESTHESIOLOGY* 31: 142-155, 1969