

## A Monitoring System Incorporating Ultrasonic Fetal Cardiotachometry and Uterine Electromyography

PAUL J. POPPERS, M.D.,<sup>\*</sup> MIECZYSLAW FINSTER, M.D.,<sup>\*</sup>  
STEPHEN R. TOPAZ, B.S.M.E.,<sup>†</sup> F. J. HATKE, M.S.E.E.<sup>‡</sup>

Monitoring of fetal status during labor and delivery was pioneered by Saling,<sup>1</sup> Caldeyro-Barcia,<sup>2</sup> Hon,<sup>3,4</sup> and Hammacher.<sup>5</sup> The last three of these investigators have shown the great value in the diagnosis of fetal distress of correlating changes in fetal heart rate with uterine contractions. Confirmation of the diagnosis can be obtained by analysis of fetal capillary-blood gases according to the method of Saling.<sup>6</sup>

The monitoring equipment designed by Hon records fetal heart rate and intrauterine pressure for accurate determination of early, late and variable decelerations, as defined by him.<sup>7,8</sup> However, because the technique is invasive, monitoring cannot start until the uterine cervix is partially dilated and the membranes are ruptured.<sup>9</sup> Only highly skilled personnel can initiate the procedure. In addition, it carries the risks of contamination, trauma, and uterine perforation.<sup>10</sup> Therefore, there is a definite need for a method of fetal monitoring which is noninvasive and applicable during the entire course of labor. It should be safe for the mother and fetus and relatively simple to use. This paper describes a system that meets these requirements.<sup>†</sup> The system uses ultrasonic kinetotachometry to register fetal heart rate changes and electromyography to record uterine contractions.

<sup>\*</sup> Associate Professor.

<sup>†</sup> Biomedical Engineer.

Received from the Departments of Anesthesiology and of Obstetrics and Gynecology, College of Physicians and Surgeons, Columbia University, New York; the Services of Anesthesia and of Obstetrics and Gynecology, The Presbyterian Hospital in the City of New York; and the Department of Biomedical Research, Roche Medical Electronics Division, Hoffmann-La Roche Inc., Cranbury, New Jersey. Presented in part at the 10th Congress of the Scandinavian Society of Anaesthesiologists, Lund, Sweden, 1971.

<sup>‡</sup> Prototype developed by the Medical Electronics Division, Hoffmann-La Roche Inc., Cranbury, New Jersey.

### METHODS

A transducer emitting ultrasonic waves is placed on the abdomen of the parturient. The emission is aimed at the fetal heart. The ultrasound is reflected from the surface of the beating heart. Thus, there is phasic motion towards and away from the external transducer, each systole and diastole of the heart causing a Doppler frequency shift in the reflected ultrasound. The registered Doppler signals are fed into a tachometer for counting of the heart rate.

The transducer assembly consists of three transmitting crystals, 8 cm apart, arranged in triangular fashion around a central receiving crystal. Ultrasound with an energy of less than 5 mW/cm<sup>2</sup> is continuously emitted at a frequency of 2 MHz, in a wide beam that usually allows detection of fetal heart motion from a standard position in the midline halfway between the umbilicus and the symphysis pubis.

Any sound energy, including ultrasound, consists of sinusoidal positive and negative phases, representing compression and rarefaction of the medium through which the sound energy is propagated. Spacing the phases irregularly according to a random code labels the continuously emitted ultrasonic energy. This allows determination of the distance between the abdominal surface of the mother and the fetal heart, the time elapsed between emission and return of the signal being proportional to the distance travelled, and the velocities of sound in various soft tissues being nearly constant and known. Signal coding also makes it possible selectively to enhance impulses returning from a target whose distance has been determined. A replica of the randomly coded signal is retained and delayed for the time necessary for the emitted energy to travel to and from the target at the known distance. The return signal is then compared with the retained one. If the reflected signals

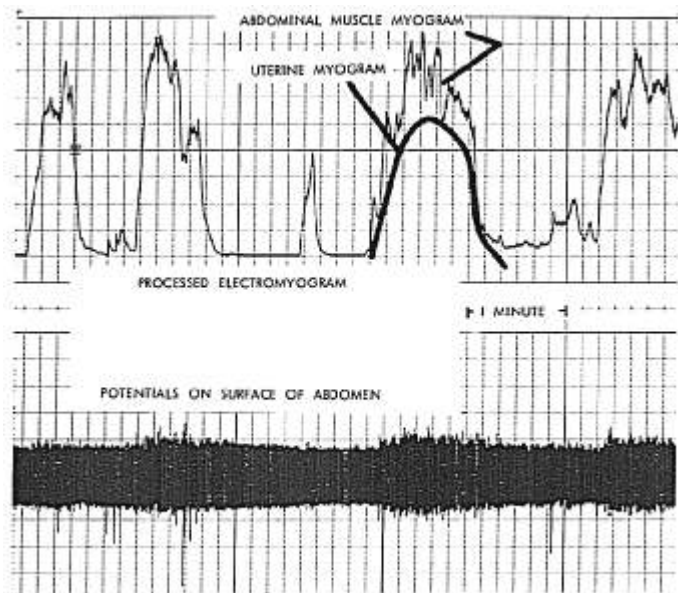


FIG. 1. Integration of alternating-current potentials into a uterine myogram. The superimposed short spikes represent potentials generated by the abdominal wall musculature. The maternal electrocardiographic signals have been filtered out.

actually come from the predetermined depths, the positive and negative phases in the emitted and retained signals coincide and reinforce each other. However, signals reflected from interfaces that do not lie within the preselected depth range return either early or late in relation to the retained delayed signal. Then the positive and negative phases of the emitted and retained ultrasound energy do not correlate, and attenuate each other.

The uterine contractions are monitored by electromyographic signals. Surface electrodes on the abdomen pick up both alternating and direct currents. The former are fast action potentials generated by contracting muscles, whereas direct-current potentials are associated with tissue metabolism. A differential amplifier is used to process only the alternating-current components, which are then re-

corded. Only currents with frequencies between 45 and 400 Hz are accepted for processing. The rationale is that maternal ECG signals detected on the abdomen have frequencies below this band width, and that there are no useful signals above it. Signals within the band width are rectified and integrated to indicate uterine muscle activity. The result is a uterine myogram with a slow build-up and decline which may last 1 to 2 minutes. Superimposed upon it, short-lasting spikes of the skeletal myogram are detectable (fig. 1).

#### RESULTS

Forty-nine patients in labor were monitored for a total time of nearly 42 hours. Localization of the fetal heart was first sought by placing the transducer assembly in the midline be-

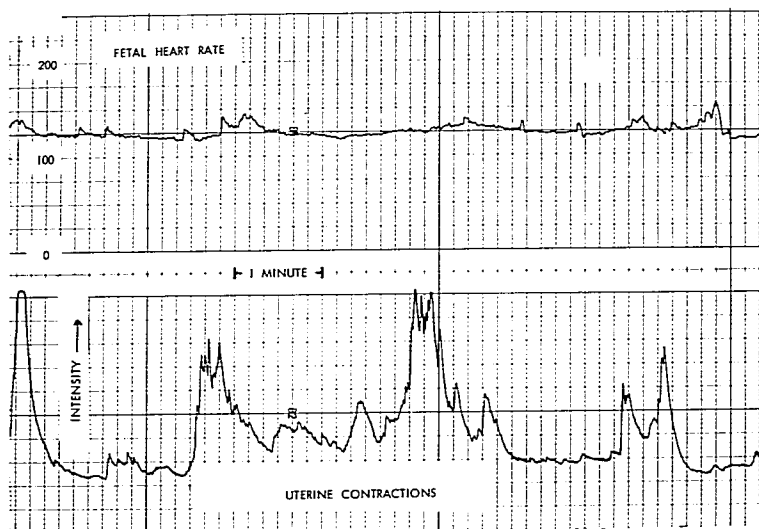


FIG. 2. Simultaneous recording of the fetal heart rate and integrated uterine electromyogram. The uterine contractions do not affect the fetal heart rate.

tween the symphysis pubis and the umbilicus. The fetal heart usually could be located 8 to 12 cm below the abdominal surface.

Placement of the ultrasound transducer in non-standard positions was necessary for detection of fetal heart motion in 11 patients. Of these, only three had normal vaginal deliveries, one of which complicated by fetal distress. Three other patients needed cesarean section because the fetuses were in a transverse lie or otherwise failed to descend into the pelvis. Midforceps extraction was indicated in three instances. In the one case of twin pregnancy, the fetal heart localizations were in the right and left lower quadrants. Finally, there was one fetal death in the series. Because the fetal head initially was not engaged, high placement of the ultrasonic transducer was necessary. With the cervix uteri only 1-2 cm dilated, the head did descend into the pelvis, immediately after which the fetus suddenly died. Delivery occurred several hours later. A double loop of umbilical

cord around the neck of the fetus was found to be the cause of death.

Figure 2 is an example of the simultaneous recording of fetal heart rate and uterine electromyogram. There are no variations in heart rate related to uterine contractions. Figures 3 and 4 are segments of the recordings from the case in which the fetus died. They show an episode of severe fetal bradycardia and a typical late deceleration, transient in nature, lasting approximately 40 seconds, which are indicative of fetal distress. This was not recognized at the time of monitoring because at that time apparatus for immediate display of signals was not yet available, the data being recorded on magnetic tape.

#### DISCUSSION

The combination of ultrasonic Doppler cardiometry with uterine electromyography constitutes a new approach to a fetal monitoring system. It differs from the ultrasound method described by Bishop<sup>21</sup> in that a radar-

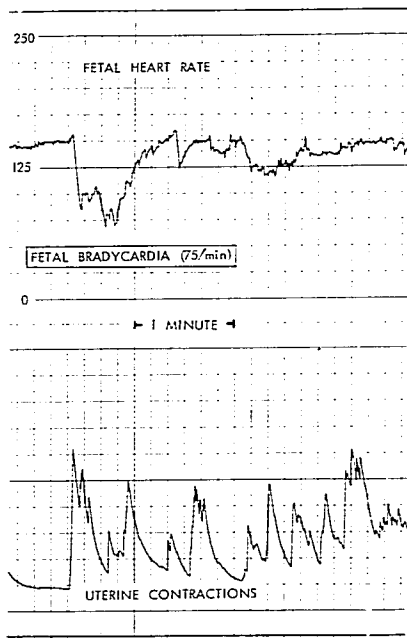
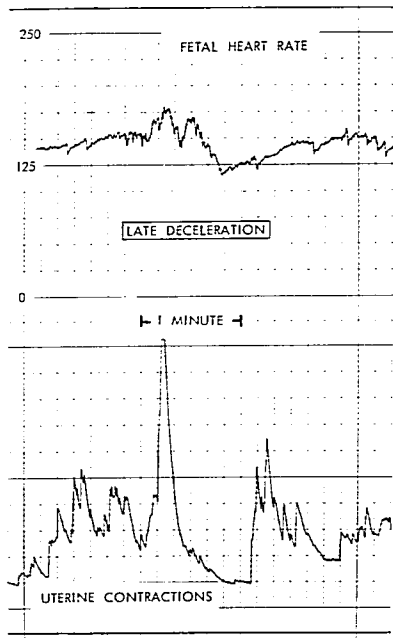


FIG. 3 (left). Simultaneous recording of the fetal heart rate and integrated uterine electromyogram. It shows severe fetal bradycardia, lasting 35 seconds, occurring during a period of frequent contractions.

FIG. 4 (right). Simultaneous recording of the fetal heart rate and integrated uterine electromyogram. Typical example of late deceleration in fetal heart rate, lasting 45 seconds.



like ranging process shows the exact depth of the fetal heart. It also eliminates or attenuates signals returning from other tissue planes. The width of the emitted sound beam is such that fetal cardiometry usually can be accomplished with the transducer in one central location during the greater part of labor. The ultrasonic transducer may have to be shifted downward when the fetal head approaches the pelvic floor. The need to place the ultrasonic transducer in a non-standard position appears to have prognostic significance in terms of complicated delivery.

The energy output of the transducer does not exceed  $5 \text{ mW/cm}^2$  at a frequency of 2 MHz. At present there is no evidence that this amount of energy can cause adverse biological effects in mother or fetus.<sup>12-14</sup>

It should be realized that reliable tachometry of Doppler impulses is difficult to accomplish. Depending on how the ultrasonic energy reaches the fetal heart, which often shifts its position, the sound waves are reflected from one or several surfaces. One or more Doppler signals, usually of different intensities, may be produced by each heartbeat. As

a result, two strong signals from one cardiac cycle may be counted as two heartbeats by the tachometer, and certain weak signals may not be counted at all. To arrive at a usable rate recording, short-term signal averaging is necessary. Beat-to-beat analysis, possible with direct recording of fetal ECG complexes, is much less feasible with indirect cardiota- chometry.

Indirect recording of uterine contractions cannot show their absolute strength, or the resting tone of the uterus. However, in electro-myography the amplitude of the signal is determined by the number of muscle fibers firing. Thus, the amplitude may indicate the relative intensities of individual contractions. In fact, there is evidence of a direct relationship, in the second stage of labor, between intrauterine pressures and uterine electrical activity as measured by three pairs of internal electrodes.<sup>15</sup> Tokodynamometry is not capable of giving this information.

Figures 3 and 4 demonstrate that, despite extremely short duration, and despite occurrence in very early labor, fetal bradycardia or late deceleration may be highly significant. In the case reported here these heart rate changes suggest fetal distress resulting from abnormal fetal oxygenation. Marginal before labor, oxygenation became inadequate as soon as uterine contractions reached normal intensity. Indeed, nuchal cord strangulation was observed at birth. The important consideration is that these phenomena could not have been detected by conventional methods. This emphasizes the desirability of electronic monitoring of the fetal heart rate in relation to uterine activity throughout the course of labor. Equally clear is the need for instantaneous recording and rapid, accurate interpretation of data.

The indirect technique that combines ultrasonic fetal cardiota- chometry and uterine electro-myography appears useful in most instances, especially in the early stages of labor. It remains true, however, that direct monitoring yields greater precision. The design of a monitoring system that incorporates the features of

the external method described here with those of the invasive approach would seem desirable to meet clinical requirements for continuous fetal monitoring during labor.

## REFERENCES

1. Saling E: Technik der endoskopischen Mikrolutentnahme am Feten. *Geburtshilfe Frauenheilkd* 24:464-469, 1964
2. Caldeyro-Barcia R, Mendez-Bauer C, Poseiro JJ, et al: Control of human fetal heart rate during labor, International Symposium on The Heart and Circulation in the Newborn and Infant. Edited by DE Cassels. New York, Grune & Stratton, Inc., 1966, p 18
3. Hon EH: Electronic evaluation of the fetal heart rate. *Am J Obstet Gynecol* 83:333-353, 1962
4. Hon EH: The diagnosis and treatment of fetal distress, *Prenatal Life*. Edited by HC Mack. Detroit, Wayne State University Press, 1970, pp 91-107
5. Hammacher K: Die kontinuierliche elektronische Ueberwachung der foetalen Herztaetigkeit vor und waehrend der Geburt. *Gynaecol Geburtshilfe* 2:793-803, 1967
6. Kubli FW, Berg D: The early diagnosis of fetal distress. *J Obstet Gynaecol Br Comm* 72:507-512, 1965
7. Paul RH, Hon EH: A clinical fetal monitor. *Obstet Gynecol* 35:161-168, 1970
8. Hon EH, Quilligan EJ: The classification of the fetal heart rate. II: A revised working classification. *Conn Med* 31:779-784, 1967
9. Roux JF, Wilson R, Yeni-Komshian H, et al: Labor monitoring. A practical experience. *Obstet Gynecol* 36:875-880, 1970
10. Haverkamp A, Watson AB: Uterine perforation: A complication of continuous fetal monitoring. *Am J Obstet Gynecol* 110:667-669, 1971
11. Bishop EH: Ultrasonic fetal monitoring. *Clin Obstet Gynecol* 11:1154-1164, 1968
12. Southam CM, Beyer H, Allen AC: The effects of ultrasonic irradiation upon normal and neoplastic tissues in the intact mouse. *Cancer* 6:390-396, 1953
13. Boyd E, Abdulla U, Donald I, et al: Chromosome breakage and ultrasound. *Br Med J* 2:501-502, 1971
14. Safety of Sonar in Obstetrics. Editorial, *Lancet* 1:1158-1160, 1970
15. Wolfs C, van Leeuwen M, Rottinghuis H, et al: An electromyographic study of the human uterus during labor. *Obstet Gynecol* 37:241-246, 1971