

12. Lvoft R, Wilcken DEL: Glucagon in heart failure and in cardiogenic shock. *Circulation* 45:534-542, 1972
13. Klein SW, March JE, Mahon WA: Cardiovascular effects of glucagon in man. *Can Med Assoc J* 98:1161-1164, 1968
14. Dixon WJ, Massey FJ Jr: *Introduction to Statistical Analysis*. Second edition. New York, McGraw-Hill, 1957, pp 124-130
15. Mostert JW, Evers JL, Hobika GH, et al: The valsalva maneuver as a clinical test for circulatory congestion in chronic uremia. *J Surg Oncology* 2:207-219, 1970
16. Neff MS, Kim KE, Persoff M, et al: Hemodynamics of uremic anemia. *Circulation* 43: 876-883, 1971
17. Gambino SR: *Water, electrolytes, acid-base and oxygen*. Todd-Sanford Clinical Diagnosis. Fourteenth edition. Edited by I Davidsohn, JB Henry. Philadelphia, Saunders, 1969, p 670
18. *Ibid*: p 663 for p11 and P_{CO₂}.
19. Domino EF, Chodoff P, Corssen G: Pharmacologic effects of CL-581, a new dissociative anesthetic in man. *Clin Pharmacol Ther* 6:279-291, 1966
20. Kreuscher H, Gaugh H: Die Wirkung des Phencyclidinderivatives Ketamine (CL-581) auf das kardiovaskuläre System des Menschen. *Anaesthesist* 16:229-233, 1967
21. Virtue RW, Alanis JM, Mori M, et al: An anesthetic agent: 2-orthochlorophenyl 2-methylamine cyclohexanone HCl (CL-581). *ANESTHESIOLOGY* 28:823-833, 1967
22. Dowdy EA, Kaya K: Studies of the mechanism of cardiovascular response in CL-581. *ANESTHESIOLOGY* 29:931-943, 1968
23. Traber DL, Wilson RD: Involvement of the sympathetic nervous system in the pressor response to ketamine. *Anesth Analg (Cleve)* 248-252, 1969
24. Traber DL, Wilson RD, Priano LL: Blockade of the hypertensive response to ketamine. *Anesth Analg (Cleve)* 49:420-426, 1970
25. Traber DL, Wilson RD, Priano LL: The effect of beta adrenergic blockade on the cardiopulmonary response to ketamine. *Anesth Analg (Cleve)* 49:604-613, 1970
26. Epstein SE, Levey GS, Skelton CL: Adenyl cyclase and cyclic AMP: Biochemical link in the regulation of myocardial contractility. *Circulation* 43:437-450, 1971
27. Westlie L, Andersen A, Jervell J, et al: Cardiovascular effects of glucagon. *Acta Med Scand* 189:179-184, 1971
28. Shimosato S, Etsten BE: Effect of anesthetic drugs on the heart. *Clinical Anesthesia a Decade of Progress*. Edited by LW Fabian. Philadelphia, Davis, 3/1969, pp 18-72
29. Sechzer PH, Egbert LD, Linde HW, et al: Effect of CO₂ inhalation on arterial pressure. ECG and plasma catecholamines and 17-OH corticosteroids in normal man. *J Appl Physiol* 15:454-458, 1960

Anesthetic Management of Lobectomy for Massive Pulmonary Hemorrhage

HAROLD CARRON, M.D., AND SUSAN HILL, M.D.

Massive pulmonary hemorrhage may necessitate emergency thoracotomy as a life-saving measure. In such a situation, anesthetic management is of critical importance for the patient's survival.

REPORT OF A CASE

A 61-year-old Caucasian woman was admitted for the third time for hemoptysis. On previous admissions, blood losses had been minimal and had been self-limiting with conservative treatment.

Received from the Department of Anesthesiology, University of Virginia Medical Center, Charlottesville, Virginia 22901. Accepted for publication May 22, 1972.

Bronchoscopy and sputum and x-ray studies revealed old cavity tuberculosis of the right upper lobe as the source of bleeding. On the current admission, hemorrhage was massive, causing acute respiratory distress. In the four hours preceding operation, 1,300 ml of blood were expectorated. Blood-gas analysis revealed P_{O₂} 61 torr, P_{CO₂} 55 torr, and pH 7.34; hematocrit was 33 per cent. Because of failure of the bleeding to abate and increasing respiratory distress, emergency pulmonary lobectomy was scheduled.

The patient, orthopneic and apprehensive, was brought to the operating room at 10:00 p.m. During insertion of additional intravenous catheters and application of monitoring devices, the patient had continuous hemoptysis of more than 600 ml in a 10-minute period. Although tracheostomy

was contemplated, the persistent coughing and hemoptysis prevented performance of the procedure. With the patient still in the sitting position, using topical anesthesia with 10 per cent cocaine, a #7 cuffed nasotracheal tube was passed blindly into the right main bronchus, where the cuff was gently inflated to occlude the right upper lobe bronchus (fig. 1). Morphine, 5 ml, was then given intravenously, and after suctioning, the anesthetic mask was placed over the patient's face to permit ventilation of the right lung through the endotracheal tube and the left around the endotracheal tube. The patient was then anesthetized with oxygen and halothane with spontaneous respiration. Anesthesia was carried to a depth adequate to maintain systolic blood pressure at 70 torr in an attempt to decrease bleeding.

As soon as the patient was adequately anesthetized, she was placed in the supine position and a low tracheostomy was performed. The cuff on the endotracheal tube was deflated, the tube with-

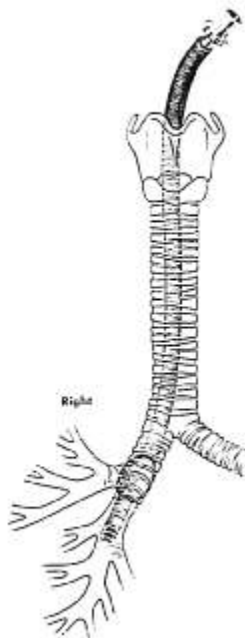


FIG. 1. Right endobronchial intubation with occlusion of the right upper lobe.

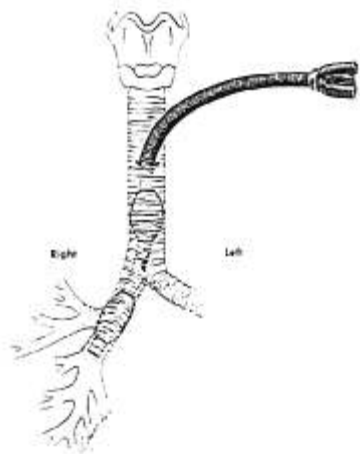


FIG. 2. Carlens tube *in situ* for occlusion of the right upper lobe bronchus.

drawn, and a Carlens tube then inserted in the reverse position with the long limb of the tube in the right main bronchus. The distal cuff was inflated to occlude the right upper lobe bronchus and the proximal cuff to occlude the trachea (fig. 2). With the bleeding controlled, vigorous tracheal toilet was performed, the patient turned to left lateral decubitus position, and an uneventful thoracotomy and lobectomy performed. At the time of incision, arterial blood-gas values of P_{O_2} 309 torr, P_{CO_2} 33 torr, and pH 7.29 attested to the adequacy of pulmonary ventilation. At the end of the surgical procedure, the Carlens tube was removed and a tracheostomy tube inserted. The patient was awake on return to the intensive care unit at 2:00 A.M. Subsequent chest x-ray showed minimal pulmonary infiltrate in the right lower lobe with a clear left lung. Recovery from operation was essentially uneventful.

Attempts at "crash" induction and endobronchial intubation of the patient with massive hemoptysis are fraught with the dangers of a blood-obscured airway, bronchospasm, hypoxia, and cardiac arrhythmias. Gentle induction of anesthesia after securing the airway in the awake patient resulted in surgical conditions calculated to control bleeding, prevent aspiration and asphyxia, and permit unhurried surgical removal of the source of hemorrhage.