A Radiographic Approach to Celiac Plexus Block

STEPHEN H. JACKSON, M.D.,* J. BRUCE JACOBS, M.D.,†
RALPH A. EPSTEIN, M.D.‡

Celiac plexus block is used diagnostically, prognostically and therapeutically. The classical approaches rely solely on surface landmarks [1, 2] or, at best, on radiologically observed bony landmarks. Precise needle placement is frequently difficult, and some experts [2, 3] advocate the use of at least 50 ml of local anesthetic solutions, presumably in an attempt to compensate for the inherent inaccuracy of the method. This problem is compounded by the fact that the block often is used in patients who have pathologic conditions such as carcinoma of the pancreas, in which distortion of normal anatomy is to be expected. The celiac plexus is anatomically related to the celiac artery. Therefore, it is logical to use the celiac artery as a landmark for a precise blocking technique. Precise needle placement has two advantages: it enables a successful block with small quantities of blocking agent, and it avoids the hazards of inadvertent puncture of vascular, neurologic and neoplastic structures. The celiac artery can be visualized by angiography, which, of itself, involves only minimal morbidity.[4, 5, 6]

TECHNIQUE [7]

Using routine angiographic technique, a radiopaque catheter is introduced into the celiac artery. A celiac angiogram is performed to document the anatomic position of the celiac artery as well as the position of the catheter tip relative to the artery. The position of the aorta is ascertained by visualization of the more proximal portion of the catheter. The patient is placed in the lateral decubitus position and the site of approach determined by the celiac angiogram. A four- to six-inch 22-gauge needle is introduced and directed to the optimal position relative to the catheter tip under biplane fluoroscopic control. Water-

* Staff Anesthesiologist, Anesthesiology Department. Present address: Department of Anesthesia, Stanford University Medical Center, Stanford, California.

† Staff Radiologist, Department of Diagnostic Radiology.

‡ Staff Anesthesiologist, Anesthesiology Department.

Received from the Anesthesiology Department and the Department of Diagnostic Radiology, Clinical Center, National Institutes of Health, Bethesda, Maryland.

FIG. 1. Celiac angiogram showing the position of the catheter relative to the celiac artery and the gross distortion of the normal vascular anatomy by the patient's extensive pancreatic carcinoma. C = catheter in aorta; CT = catheter tip; L1 = body of first lumbar vertebra.

Downloaded from http://asa2.silverchair.com/anesthesiology/article-pdf/31/4/373/288534/0000542-196910000-00020.pdf by guest on 18 April 2024

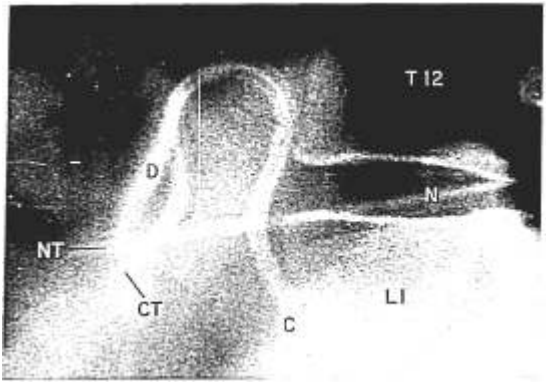

FIG. 2. Lateral fluoroscopic spot film. A radiopaque catheter is in the celiac artery. The tip of the block needle is adjacent to the celiac artery. Two ml of radiopaque dye have been injected to delineate the desired fascial plane. C = catheter in aorta; CT = catheter tip in celiac artery; D = dye; L1 = body of first lumbar vertebra; N = needle; NT = needle tip; T12 = body of twelfth thoracic vertebra.

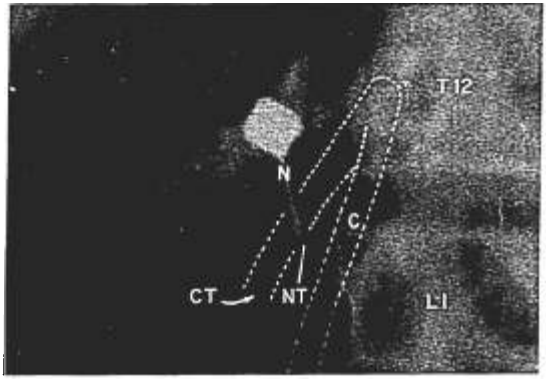

FIG. 3. Posterior-anterior fluoroscopic spot film. A radiopaque catheter is in the celiac artery. The tip of the block needle is adjacent to the celiac artery. C = catheter in aorta; CT = catheter tip in celiac artery; L1 = body of first lumbar vertebra; N = needle; NT = needle tip; T12 = body of twelfth thoracic vertebra. The catheter is outlined by broken lines.

soluble contrast medium, 2–3 ml, is injected to establish the position of the needle tip and to demonstrate free passage of contrast material in the desired fascial plane. The blocking drug is then injected. Because of the free communication and contiguity of the celiac plexus, only unilateral injection is considered necessary. A decrease in the arterial pressure, which is monitored via the angiographic catheter, provides objective confirmation of a successful block.

CASE REPORT

A 40-year-old man had intractable pain from advanced metastatic carcinoma of the pancreas. His condition had responded poorly to radiotherapy and chemotherapy. It was thought that a celiac plexus block might relieve the pain. An attempt to perform a block with a classical approach failed. Several weeks later the angiographic technique described above enabled precise localization of the celiac plexus. Figure 1 shows the catheter positioned in the celiac artery. The celiac arteriogram showed that the neoplasm had grossly distorted the normal anatomy and ex-

Downloaded from http://asa2.silverchair.com/anesthesiology/article-pdf/31/4/373/285340/0000542-196910000-00020.pdf by guest on 18 April 2024

plained the failure of the classical approach. In this patient it was necessary to introduce the block needle 4 cm to the left of the midline at the level of the inferior border of the twelfth thoracic vertebra. Under biplane fluoroscopy the needle tip was positioned adjacent to the celiac artery (figs. 2 and 3), and radiopaque dye, 2 ml, was injected prior to the injection of the anesthetic solution. A successful block was then performed with 10 ml of 2 per cent prilocaine.

References

1. Bonica, J.: The Management of Pain. Philadelphia, Lea and Febiger, 1953, pp. 446–453.
2. Adriani, J.: Labat's Regional Anesthesia. Third edition. Philadelphia, W. B. Saunders Co. 1967, pp. 405–413.
3. Moore, D.: Regional Block. Fourth edition. Springfield, Charles C Thomas, 1965, pp. 145–162.
4. Lang, E.: A survey of complications of percutaneous retrograde arteriography: Seldinger technic, Radiology 81: 257, 1963.
5. Lang, E.: Prevention and treatment of complications following arteriography, Radiology 88: 950, 1967.
6. Pollard, J., and Nebesar, R.: Abdominal angiography, New Eng. J. Med. 279: 1035, 1968.
7. Jacobs, J., Jackson, S., and Doppman, J.: A radiographic approach to celiac ganglion block, Radiology 92: 1372, 1969.

An Exercise Helmet for Physiologic Studies

Sisir K. Gupta, M.D.*

Keeping the appropriate mouthpiece in position during exercise studies has been quite a problem. An exercise helmet designed to solve the problem is presented. This helmet should also prove useful for studies of conscious patients at rest.

The helmet has three parts (fig. 1): *a*, the headpiece, a plastic circular band similar to that used in a welder's helmet, with an adjustable circumference; *b*, supporting sidebars made of lightweight aluminum; *c*, aluminum frame to hold the Rudolf three-way valve in position.

The junction of the headpiece and side bars has butterfly-nuts to allow both up-and-down and to-and-fro movement of the side bars. The junction of the side bars with the frame for the mouthpiece is also adjustable, and allows circular movement of the Rudolf valve. The rubber mouthpiece and Rudolf valve can be changed whenever necessary. As the helmet is lightweight and completely self-supporting, it permits both the investigator and the patient to concentrate on other relevant matters during the study.

Fig. 1. Exercise helmet in position.

* Fellow in Pulmonary Diseases, Veterans Administration Hospital, 1201 Northwest 16th St., Miami, Florida 33125.

The author thanks Mr. E. Fabre, Small Parts, Miami, Florida, for the construction of this device.

Downloaded from http://asa2.silverchair.com/anesthesiology/article-pdf/31/4/373/288534/0000542-196910000-00020.pdf by guest on 18 April 2024