

## PNEUMOENCEPHALOGRAPHY AND AIR EMBOLISM: SIMULATED ANESTHETIC DEATH

JAY JACOBY, M.D., JOHN R. JONES, M.D., JOHN ZIEGLER, M.D., LEON CLAASSEN, M.D.,  
JOHN P. GARVIN, M.D.

THE INJECTION of air into the spinal canal, first described by Dandy<sup>1</sup> in 1919, has become a valuable diagnostic tool in the investigation of intracranial disease. Although pneumoencephalography is generally considered to be a minor procedure, there are serious dangers associated with it. This paper calls attention to the hazards and reports our incidence of complications. Methods are suggested for the prevention, recognition and treatment of the complications.

A review of the literature from 1923 to 1950 by Coleman<sup>2</sup> disclosed 31 reported fatalities following pneumoencephalography. Of these, 13 who had cerebral lesions died within several days after the procedure. In another 13, the time relationship between encephalography and death was not stated. The remaining five died during the procedure: one, reported by Mader, had sustained birth trauma; four reported by King and Otenasek<sup>3</sup> and by Coleman<sup>2</sup> had air embolism. A series of 2,490 pneumoencephalograms was reported by Whittier<sup>4</sup> with 24 deaths, six of which he considered to be related to the procedure. There were no deaths during pneumoencephalography and all six patients had cerebral lesions incompatible with life. Schuleman<sup>5</sup> reported a series of 572 pneumoencephalograms with three deaths which occurred after an interval of at least five days.

### THE PROCEDURE

Pneumoencephalography consists of a lumbar puncture, withdrawal of cerebrospinal fluid, and injection of an equal volume of air or other gas. With the patient sitting, the gas rises to the cerebral ventricles, following which roentgenograms are made. The replacement of cerebrospinal fluid by a gas usually

results in a headache which may be so severe that it causes the patient to become uncooperative. A general anesthetic may therefore be required. Our technique in adults is to give intravenously a short acting barbiturate in amounts just sufficient to keep the patient quiet. In some instances only heavy sedation is required. In children, our method of choice has been induction of anesthesia with divinyl ether, followed by diethyl ether and oxygen. Endotracheal intubation is often carried out if difficulty in maintenance of the airway is anticipated or occurs.

### POTENTIAL HAZARDS

**Dangers Related to Location.** Pneumoencephalography is usually done in a small roentgenographic room remote from the main operating suite. In the event that the patient develops serious difficulty, aid and equipment must be summoned, or the patient and the resuscitation equipment must be moved to the operating suite. The delay may be critical. Because of personnel shortages, relatively inexperienced surgeons and anesthesiologists may be delegated to perform this minor procedure. Remote from supervision, their difficulties may be multiplied in situations where experienced assistance would avoid trouble.

**Dangers Related to the Anesthetic.** The patient for pneumoencephalogram is frequently a poor anesthetic risk due to pre-existing brain damage. In addition, there may be hypertensive or arteriosclerotic cardiovascular disease, angina, emphysema, and hypovolemia.

The patient must be in the upright position at the outset and later supine, prone and lateral for appropriate radiographic views of his skull. Moving the patient about, and rotating or flexing his head, frequently leads to airway obstruction. Abrupt change of body position may cause severe hypotension.

Brain damage may increase the patient's

Accepted for publication February 13, 1959.  
The authors are in the Division of Anesthesiology, Ohio State University, Columbus, Ohio.

sensitivity to anesthetic agents, the respiratory center may be abnormal, and the patient may be unable to maintain adequate respiratory activity even with light anesthesia and a satisfactory airway.

Since nonexplosive anesthetic agents often are not satisfactory for pneumoencephalography for children, ether by inhalation is frequently given. This introduces a hazard of fire and explosion. If the room is adequately ventilated, and the equipment so arranged that the ether vapor is blown away from the roentgenogram unit, the danger is minimized.

**Dangers Related to the Procedure.** HERNIATION OF THE MEDULLA: If cerebrospinal fluid is removed from a patient with increased intracranial pressure, the brain stem may be forced downward into the foramen magnum. This produces compression of the medullary centers. The physiological changes so produced may cause cessation of vital functions. Rapid escape of cerebrospinal fluid increases the hazard. In the presence of increased intracranial pressure, therefore, we recommend that the stylet of the lumbar puncture needle be removed slowly, to control the fluid escape.

If herniation of the brain stem should occur, prompt action may save the patient's life. Oxygenation should be maintained by positive pressure artificial respiration. If hypotension develops, vasopressor drugs should be administered intravenously. Definitive treatment of the herniation may be accomplished by restoring the pressure relationships in the cranium and spinal canal, by injecting appropriate quantities of saline solution or by replacing the spinal fluid which had been withdrawn. The pressure may also be equalized by rapid decompression of the brain. It is possible that the medulla might be dislodged by jolting a small patient in the head-down position.

**Case Report:** A 49 year old white male with a vague history of disorientation and confusion of two weeks duration was transferred from another hospital. He was scheduled for pneumoencephalogram.

Premedication consisted of atropine, 0.4 mg. 1½ hours prior to the procedure. With the patient sitting, 250 mg. of thiopental were given in divided doses prior to the lumbar puncture. Following rapid removal of about 15 ml. of spinal fluid, the patient's systolic blood pressure fell from 150 mm.

of mercury to 80 mm. and the pulse rose from 96 to 200 per minute. At the same time, respiration ceased. The lumbar puncture needle was withdrawn and the patient placed supine. An endotracheal tube was inserted and artificial respiration begun with oxygen. Phenylephrine was added to the infusion (10 mg. in 800 ml.), and the blood pressure was maintained at about 100 mm. Hg.

A tentative diagnosis of herniation of the brain stem was made. The patient was turned on his side and the lumbar puncture needle was reinserted. Twenty ml. of normal saline were rapidly injected into the subarachnoid space. A few moments later, spontaneous respirations began and the blood pressure began to rise so that it was no longer necessary to give the vasopressor drug at a rapid rate. The contemplated pneumoencephalogram was not performed; instead, the patient was taken to the operating room and a suboccipital craniotomy performed. A large tumor of the third ventricle was found and a Torkildsen procedure was performed. Because of the large size of the tumor, the prognosis was poor. The patient remained in coma and died two days later. The immediate treatment of the herniation of the medulla, however, was satisfactory in that restoration of the vital functions was quickly accomplished.

**AIR EMBOLISM:** The injection of a gas into the body may result in embolism. In pneumoencephalography, embolism is probably most often caused by faulty placement of the lumbar puncture needle. Since the needle is bevelled, a portion of the lumen may be within the subarachnoid space, and a portion may be extradural or intravascular (figs. 1 and 2); spinal fluid may thus be obtained, but when gas is injected, some enters the subarachnoid space and the remainder enters blood vessels or tissues. Tearing of the vessels within the subarachnoid space may also permit the entrance of air, because veins above the mid-cervical level have a negative intraluminal pressure. Embolism is perhaps more likely to occur in children, since a given quantity of air fills a relatively larger portion of the ventricular system, and since placement of the needle is more difficult.

The sequence of events follows a pattern: during or immediately following the injection of air, extreme pallor without cyanosis is noted. The pulse and blood pressure weaken and then disappear, respiration ceases, cyanosis may occur, and the patient appears to be dead. The early warning sign of air embolism is a peculiar gurgling noise, a "mill wheel" murmur, originating in the heart. The surgeon or

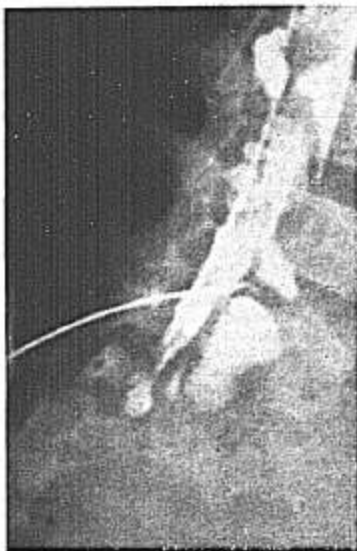

FIG. 1. Myelogram of a four and one-half year old child, showing contrast material in both the subarachnoid and the extradural spaces. Faulty placement of the needle, with the bevel partially in each space, was probably responsible.

anesthesiologist may be able to detect the characteristic sound of air in the heart by auscultation of the chest before a fatal quantity is administered. Air from peripheral veins enters the right side of the heart and the ventricle fills with froth, which prevents proper filling and emptying. Bubbles enter the pulmonary artery and may pass to the systemic side of the circulatory system. Air may also pass directly to the left side of the heart through a septal defect.

Resuscitation of patients with air embolism depends upon prompt recognition.<sup>6</sup> The treatment consists of placing the patient on his left side and in steep Trendelenburg position. In this position the apex of the right ventricle is uppermost, trapping air bubbles. This allows the heart to maintain circulatory efficiency. Since the orifice of the pulmonary artery is dependent, blood rather than froth

enters the vessel. A needle should then be inserted into the right ventricle to aspirate air and frothy blood.

**Case Report:** A ten month old white female had a poor sucking reflex for the first two months of life and was later unable to sit alone. Nystagmus was noted at eight months. She cried little and slept a great deal. On physical examination she appeared normal for her age with the exception of atonic extremities, lateral nystagmus, and lethargy. She was scheduled for pneumoencephalogram. Preoperative medication consisted of atropine sulfate, 0.15 mg, one hour prior to the induction of anesthesia. Divinyl ether was used for induction and was followed by ether and oxygen. Ten minutes later a lumbar puncture was done between the fourth and fifth lumbar vertebrae. Eighty ml. of spinal fluid were removed and replaced with helium. By the time the injection was completed, pallor was noted; respiration became gasping in character, and the lips became cyanotic. An endotracheal tube was quickly inserted and artificial respiration with oxygen was carried out. Twelve minutes later the heart stopped. Postmortem roentgenograms showed a small amount of air in the cerebral ventricles and a large amount beneath the tentorium. At autopsy, the chambers of the heart were dilated with frothy blood. The aorta was full of frothy blood, and large bubbles were seen within the arteries and veins of the brain.

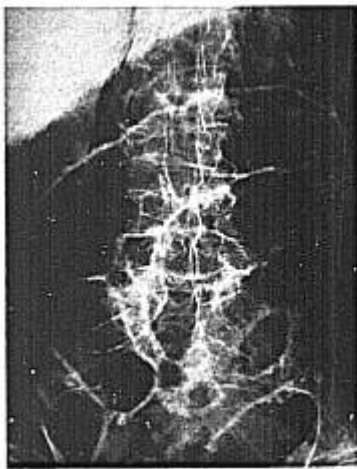


FIG. 2. Post mortem roentgenogram showing air in and around the psoas muscles. The patient was a 67 year old man who died of air embolism during pneumoencephalography.

TABLE 1  
SERIOUS COMPLICATIONS OF PNEUMOENCEPHALOGRAPHY

Age	Neurological Diagnosis	Clinical Diagnosis	Final Diagnosis	Comment
8 months	Degenerative lesion of ganglion cells in cerebral cortex and brain stem	Anesthetic death	Brain stem herniation	Confirmed by autopsy
10 months	Sclerotic changes in cortical ganglion cells	Anesthetic death	Air embolism	Confirmed by autopsy
2 months	Cerebral atrophy and aplasia	Anesthetic death	Air embolism	No autopsy—symptoms of embolism
9 months	Cerebral atrophy and aplasia	Anesthetic death	Air embolism	Confirmed by autopsy
8 months	Mental retardation (Clinical diagnosis) Microgyria	Anesthetic death	Air embolism	Confirmed by autopsy
67 years	Senile atrophy and local gliosis of brain	Anesthetic death	Air embolism	Confirmed by autopsy
49 years	Third ventricle tumor	Anesthetic death	Brain stem herniation	Resuscitated. Died after operation

In recapitulation, an apparently satisfactory lumbar puncture was performed, and no one suspected air embolism as the cause of death; therefore, no effort was made to treat it.

#### DISCUSSION

During the 10 year period, January 1948 to January 1958, general anesthesia has been administered to 1,196 patients for pneumoencephalography at Ohio State University Hospitals. Of these, 895 were children and 301 were adults. There have been seven major complications, with six deaths during the procedure. Five of the deaths were in children (table 1). The diagnosis of air embolism was made and confirmed at autopsy in four instances; one additional patient had the clinical signs of air embolism but autopsy permission could not be obtained. One patient died of herniation of the brain stem. The additional complication was another instance of brain stem herniation in which resuscitation was successful but the patient later died as a result of his brain lesion.

Premonitory signs of impending catastrophe may not be present, or they may go unnoticed. In each of these instances the physiologic

changes resulting from air embolism or herniation of the brain stem occurred rapidly, and were manifested by abrupt embarrassment or cessation of respiration and circulation. The interpretation of these signs is usually that an anesthetic complication, rather than a surgical one, has occurred. This interpretation was not substantiated at autopsy in any of our cases. If these signs develop during the procedure, two entities should immediately be brought to mind: after lumbar puncture, but before the injection of air, the most likely diagnosis is herniation of the brain stem; after the injection of air, the most likely diagnosis is air embolism. The use of oxygen or helium instead of air does not reduce the danger, since neither of these gases is very soluble in blood.

The complication of air embolism is perhaps more likely to occur in children, particularly the very young, since faulty placement of the needle is more likely to occur. It is mandatory to use short-bevelled needles in children, in addition to exercising extreme care in their placement.

Specific precautions should be taken in order to avoid catastrophe. The procedure should

be done by or under the immediate supervision of skilled surgeons and anesthesiologists. The anesthesiologist must be prepared for major resuscitative efforts, and should exercise caution in the administration of drugs and maintenance of airway. The surgeon must be careful to withdraw spinal fluid slowly and to inject air only when he is certain that the needle is properly placed.

In our series, air embolism was the principal cause of death. Our experiments with animals have shown that an audible murmur develops in the heart when only 2 ml. of air are injected intravenously. It is possible, therefore, to detect air embolism when the amount of air in the heart is innocuous. Discontinuing the injection of air at this time would prevent the serious consequences which normally follow. We recommend that the surgeon listen to the heart while he injects air. To accomplish this, he should tape a stethoscope to the patient's precordium and have the ear-pieces placed in his ears before he begins the injection.

If the patient shows signs of circulatory and respiratory collapse after lumbar puncture, but before the injection of air, the diagnosis of herniation of the medulla should be considered. The lumbar puncture needle should be left in place and the spinal fluid should be re-injected, or an equal or greater volume of saline solution should be injected. This should restore the pressure relationships within the cerebrospinal fluid system. The medulla may be dislodged from the foramen magnum, allowing the vital centers to resume their functions. The usual resuscitative measures should also be performed.

If a fatality occurs, the anesthesiologist should make every effort to have an autopsy performed. The clinical diagnosis of anesthetic death is one which is difficult to refute, without the evidence of the pathologist. During autopsy, care should be taken to open the heart and great vessels under water. Post mortem roentgenograms may be of value in establishing the diagnosis. The position of

the medulla should be determined, and it should be carefully examined for a ring of indentation caused by the pressure of the edges of the foramen magnum.

#### SUMMARY

Based upon an experience of 1,196 pneumoencephalograms, the possible complications and their treatment are discussed. Seven patients in our series developed serious complications. Two of these were herniation of the brain stem; five were air embolism. Six of these patients died.

During pneumoencephalography the onset of respiratory and circulatory collapse should bring to mind two diagnostic possibilities: herniation of the brain stem is most likely after lumbar puncture but before air injection; air embolism is most likely after air has been injected. Immediate recognition and prompt treatment of these complications may prevent a fatal outcome. The surgeon or anesthesiologist should listen constantly to the heart during the procedure. The beginning of a murmur is a signal to stop the injection of air. Autopsy and radiography are of value in establishing the correct diagnosis when air embolism or herniation of the medulla cause a simulated anesthetic death.

#### REFERENCES

1. Dandy, W.: Roentgenography of brain after injection of air into spinal canal, *Ann. Surg.* 70: 397, 1919.
2. Coleman, F. C. Schenken, J. R., and Abbott, W. D.: Air embolism during pneumoencephalography, *Am. J. Clin. Path.* 20: 968, 1950.
3. King, A. B., and Otenasek, F. J.: Air embolism occurring during cnccephalography: report of two cases, *J. Neurosurg.* 5: 577, 1948.
4. Whittier, J. R.: Deaths related to pneumoencephalography during six year period, *A. M. A. Arch. Neurol. & Psychiat.* 65: 463, 1951.
5. Schuleman, I. H.: Review of encephalograms done over a five year period, *Dis. Nerv. System* 14: 355, 1953.
6. Nicholson, M. J., and Crehan, J. P.: Emergency treatment of air embolism, *Anesth. & Analg.* 35: 634, 1956.