

Installation consists of drilling a hole in the heel of each shoe the same diameter as the lead screw anchor and enlarging each end with a countersink bit. The screw anchor will fit snugly into this hole. The $\frac{3}{8}$ -inch size is recommended as its length is almost the same as the thickness of the average heel. Any extra space is filled with molten solder, and the hot solder is leveled even with the surface of the shoe. Because of the resultant dumbbell shape of this metal core, it is self retaining; and as the metal wears at about the same rate as the heel, it requires no further attention once inserted. To insure adequate contact between this core and the wearer, a heel plate is cut from the aluminum and glued inside the shoe. The glue, however, must not cover and insulate the lead core. Most shoes have a paper or leather heel liner which can be removed and used as a pattern.

Dr. Streeter also has devised a self-retaining conductive plug using this principle which can be installed without the use of molten solder and which he hopes to make available soon.

CASE REPORT: SEPARATION OF CRANIOPAGUS

Doctors Kenneth D. Hall, John Merzig, and Forbes H. Norris, Jr., of the National Institutes of Health, Bethesda, Maryland, report an interesting anesthetic and surgical problem.

The operation consisted of separating two healthy, twin, three-month-old girls joined at the head (craniopagus), brow to brow. Although there was nothing unique in the anesthesia or procedure of surgical separation, careful attention to details was important.

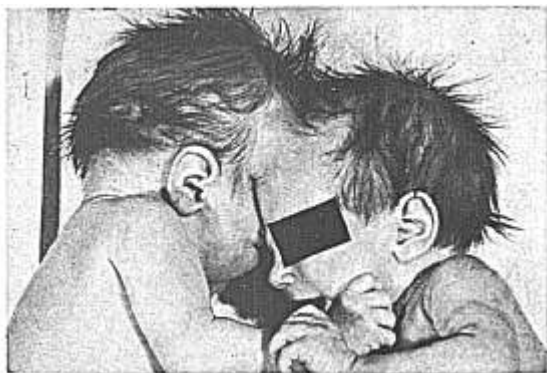

FIG. 1. Twin girls joined brow-to-brow. Separation was achieved in a 2-stage operation.

The preoperative roentgenographic and physical examinations indicated a very close connection over a large area (24 cm. circumference). Rather than perform extensive plastic procedures that might endanger the chances of survival of the infants, the surgeons elected to do a rapid separation with careful hemostasis. This was done in two stages when it was discovered, during the first operation, that the dural connections were more extensive than at first supposed. At the second operation an intimate connection between the right frontal lobe was uncovered. This included a sharing of the right anterior cere-

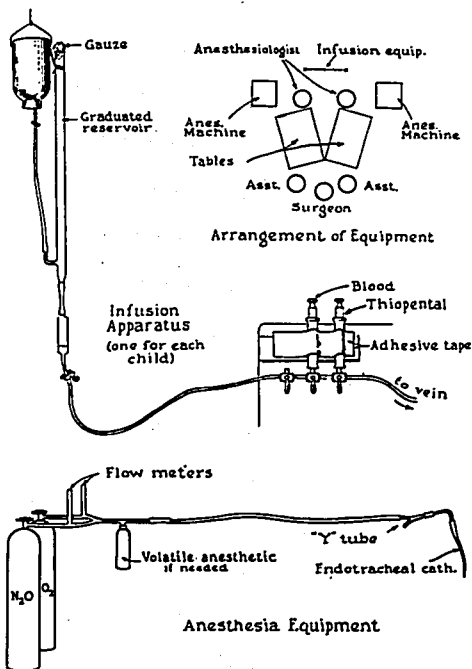


FIG. 2. Diagram of arrangement of equipment, infusion apparatus, and anesthesia equipment used in operation upon twin infants joined at the head.

bral artery. After completion of this stage the wounds were reconstituted with dural grafts derived from human material, over which homografts of skin were also placed.

The major anesthetic problems involved were threefold. The first was that of maintaining a good airway. The twins were joined brow to brow in such a position that either one or the other would have to be face down all the time. It was decided, therefore, that endotracheal intubation was necessary. Fortunately, the twins were joined enough off-center to permit the insertion of a small laryngoscope. Even so, the position made laryngoscopy so difficult that it was believed the infants should be intubated while awake, in

order to insure the best possible airway. Two lively infants in close proximity could have greatly hampered the procedure of intubation. This was avoided by careful premedication. As soon as one twin was intubated, anesthesia was slowly and carefully induced in her. Then the twins were turned 180 degrees, and the procedure was repeated on the other one. (There did not seem to be any "spill over" of anesthesia, clinically, from one twin to the other.) After both twins were intubated and had quieted from the induction, they were placed on a specially designed table in the operating room.

The second consideration was that of maintaining adequate ventilation. Because of the light plane of anesthesia maintained, assisted ventilation was not deemed necessary, and the twins breathed spontaneously throughout operation. This was confirmed by the clinical observation of good chest expansion, good color of the skin, and stability of the pulse. Because of the severe limitation of space, small Ayres Y tubes were connected directly to the endotracheal tubes (12 and 14 French, Cole) and were supplied by extra long hoses from the anesthetic machines. Since electrocautery was used, and the distance from the Ayres Y tubes to the surgical field was short, a nonexplosive anesthesia technique was mandatory. Venesections were done on both infants the day before operation, and the patients were maintained on small amounts of intravenous one per cent sodium thiopental, together with nitrous oxide, 5 liters, and oxygen, 2 liters, per minute. Additional doses of sodium thiopental were not administered until the infants became so active as to prevent good ventilation by breath-holding and was done only after other causes of irregular respiration, such as position of endotracheal tube, were ruled out. Movement of their extremities, which was observed throughout the procedure, was not considered an indication for deepening the anesthesia.

It is interesting to note that in spite of the extensive anatomical connection, there seemed to be an indication of physiologically separate circulations. In support of this suggestion are the facts that the twins were given premedication at different times and responded individually and that one twin was given nitrous oxide with a soporific result while the other twin remained awake and vigorous.

The third problem was one of maintaining correct fluid balance, electrolyte pattern, and blood volume throughout operation for both infants. The twins were well nourished, and blood electrolytes were within normal range preoperatively. Oral feedings were restricted throughout the night before surgery, but an adequate level of hydration was maintained with intravenous fluids (mostly 5 per cent dextrose in water). During operation, blood was replaced in measured amounts by means of a 10-cc. syringe, with a graduated 50-cc. buret reservoir as a check. Virtually no fluids other than blood was given during operation, but this deficiency was corrected gradually postoperatively. A weighed sponge count was made, and hematocrit readings were taken at regular short intervals. The infants' respirations, pulse rates, body temperatures, and hematocrit determinations remained within desirable limits during and after both stages of the operation.

The twins are doing well three months postoperatively. The dural grafts took well, and except for a slight wound infection one week postoperatively, there have been no serious complications.

The authors wish to thank Dr. Maitland Baldwin, who performed the surgical procedures on the twins, for his assistance in the preparation of this paper and for permission to use the photographs of the patients.

CASE REPORT: ANESTHESIA FOR A PROLONGED OPERATION

Lts. John R. Jones and Thomas B. Clay, Jr., and Lt. Comm. William H. Schwab, United States Naval Hospital at Portsmouth, report an operation lasting twenty-four and one-half hours. As part of the management of the patient, they used Arfonad to prevent hypertension and maintain blood pressure at normal levels during the period that the thoracic aorta was clamped.

The patient was a 35-year-old man (weight—182 pounds, height—6 feet, 3 inches). Three years before the present hospitalization he had fallen a distance of 20 feet, striking