

ANESTHETIC PROBLEMS OF SURGICAL CORRECTION OF AORTIC INSUFFICIENCY* †

JOHN A. O'DONNELL, M.D., AND THOMAS F. McDERMOTT, M.D.
Washington, D. C.

THE onset of decompensation in a patient with aortic insufficiency signals the beginning of the terminal phase of the disease (1). The prognosis is hopeless, and the course is progressively downhill with sudden death not an uncommon occurrence (2). Life expectancy frequently can be measured in months at best. Medical measures are unable to halt effectively this relentless course. Despite the rapid development of cardiac surgery in recent years, no surgical procedure was feasible for clinical trial in aortic insufficiency until the development of a plastic prosthetic aortic valve was reported by Hufnagel in 1951 (3). This attack on a defective cardiac valve has been tested on over 300 experimental animals in the past 6 years. The first successful clinical application of this prosthetic valve was done in September, 1952 (4). Since then, our group has anesthetized 42 patients for this surgical procedure. Our experiences in this series form the basis for this presentation.

THE SURGICAL PROCEDURE

The development and the technical application of this valve are described fully elsewhere (5). Briefly, the surgery consists of entering the chest through a posterolateral incision through the bed of the fifth rib. The aorta, distal to the origin of the subclavian artery, is freed for 4 to 6 cm. by ligating 4 to 5 pairs of intercostal vessels. It is then occluded with Pott's ductus clamps, both proximally and distally. Next, the vessel is bisected and the prosthetic valve inserted and secured by multiple point fixation (figs. 1, 2). This site for insertion was selected because the blood supply to the brain need not be interrupted, the danger of air embolism is minimized, and the high mortality associated with any manipulation of the aortic valve, itself, is eliminated. In this manner, 75 per cent of regurgitation can be controlled and maximum benefits are afforded with minimal risk for these critically ill patients.

In addition to the insertion of the valve, all patients had a left sympathectomy of the second, the third, the fourth, and the fifth thoracic ganglia. All but 3 control cases had a ligation of the left in-

* From the Department of Anesthesiology, Georgetown University Medical Center, Washington, D. C.

† Accepted for publication August 2, 1954.




FIG. 1. Prosthetic aortic valve with postmortem specimens of animal aorta.

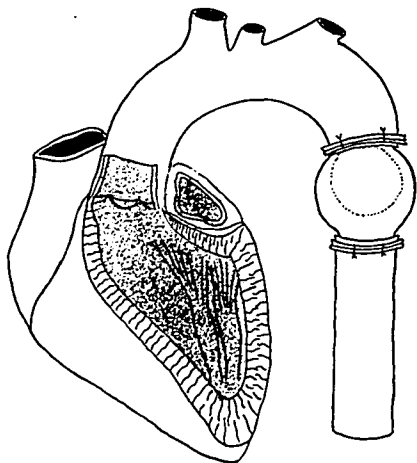


FIG. 2. Prosthetic aortic valve *in situ*.

ternal mammary artery distal to the origin of the pericardiophrenic branch. This procedure (6) is designed to increase the collateral blood supply of the left ventricle and to ameliorate the coronary insufficiency which is so prominent in this symptom complex. There

were 6 cases in which the mitral valve was palpated for stenosis, and commissurotomy was performed in 2 of these cases. One patient had a coexisting coarctation of the aorta excised at the time of insertion of his prosthetic valve.

PATHOLOGICAL PHYSIOLOGY

In order to comprehend some of the problems encountered in these poor surgical risks, we should review briefly the pathological physiology present. The incompetence of the aortic valve causes regurgitation of the blood into the left ventricle during diastole. Early in the disease, hypertrophy of the left ventricle furnishes adequate compensation, but, as time goes by, a progressively increasing strain is put on the myocardium of the left ventricle until it has dilated greatly and its weakened contractions are ineffective in emptying its chambers and maintaining adequate cardiac output. The tremendous dilatation causes mechanical respiratory embarrassment as well as technical difficulties during the procedure.

In this disease entity, the heart has pathological conditions of both the valve and the myocardium, and often the wall of the aorta is involved. Disease of the wall of the aorta may cause aneurysm and stenosis of the coronary orifices. The low diastolic pressure resulting from an incompetent valve contributes to angina and serious electrocardiographic conduction defects. Associated conditions such as mitral stenosis, coarctation of the aorta, aortitis, or aneurysm frequently are present.

Of the 42 cases anesthetized, 32 were rheumatic in origin, 6 were syphilitic, 3 were congenital, and 1 was traumatic. The sex distribution was predominantly male in a ratio of 36 to 6. Ages were from 19 to 54, with the average age being 34. All patients in this series had developed progressively increasing and medically irreversible congestive heart failure with diastolic gallop rhythm and accompanying Austin-Flint murmur. Most of the patients had some serious conduction defect, some form of heart block being the most frequent type. Over 40 per cent had intractable angina pectoris, with 10 to 20 attacks per day not infrequent. Roentgenographic evidence of cardiac enlargement was a consistent finding, marked in many cases. 85 per cent of the patients were Group IV classification and the remainder Group III (classified according to the American Heart Association). These findings are summarized in table 1.

PREOPERATIVE PREPARATION

The patients were admitted 1 week prior to operation for complete cardiac work-up, evaluation, and hospital acclimatization. Some of the preliminary procedures done are: examination of blood and urine, vital-capacity determinations (usually 50 to 75 per cent of normal

TABLE 1
CLASSIFICATION OF HEART DISEASE, AGE OF PATIENT, AND HEART SIZE

I. <i>Etiology of Heart Disease:</i>		Total No. of Cases
Rheumatic		32
Syphilitic		6
Congenital		3
Traumatic		1
		—
		42
II. <i>Classification of Heart Disease:</i>		
III		29
IV		13
		—
		42
III. <i>Age of Patient:</i>		
11-20		3
21-30		13
31-40		15
41-50		8
51-60		3
		—
		42
IV. <i>Heart Size (36 Patients):</i>		
	Heart Size (C/T—%)	
Under 50		2
50-55		7
56-60		8
61-65		9
66-70		7
Over 70		3
		—
		36

values), circulatory time, daily blood pressures on all extremities, and cardiac fluoroscopy. Congestive heart failure is treated with digitalization, ammonium chloride, and mercurial diuretics. Antibiotics in large doses, both intramuscularly and by aerosol inhalation, are administered together with adequate rest and sedation. Quinidinization, if it has been employed previously, is stopped on the day prior to operation, as the quinidinized heart is extremely difficult to resuscitate. These patients, although many are still in a critical condition, are thus in the best state that is medically possible. Since this procedure is the only hope for these patients, surgical intervention was never withheld despite the fact that some individuals were in the hopelessly terminal stages of the disease, which ordinarily would contraindicate any operation whatsoever.

ANESTHETIC MANAGEMENT

Basically, the philosophy of Pender (7) is an important one to bear in mind in these cases. Briefly stated, it is this: we must rely on the internist to bring the patient to the operating room at the optimum time and in the optimum condition for surgical intervention. Nothing

that we, as anesthesiologists, can do is designed to improve this condition. The best we can hope for is that our ministrations will not affect the patient adversely. The philosophy of the surgeon should reflect an equal dependence on his colleagues. These are cases in which the affected specialties working as a harmonious team can contribute a great deal to the patient's welfare.

These patients tolerate anesthesia very poorly for any procedure. Here, they are subjected to the added stress of an intrathoracic procedure and cardiovascular manipulation. They should be visited early, and the anesthetic procedure and the immediate postoperative expectations described briefly. Most candidates realize the limited future which medical therapy has to offer and, consequently, look forward to what this procedure may offer. However, in the preoperative visit, it is important to answer all questions fully and carefully for complete reassurance.

Premedication usually consists of a barbiturate one and a half hours preoperatively, and morphine and scopolamine 1 hour preoperatively in doses calculated to bring the patient to the operating room in a drowsy and relaxed state. Demerol[®] has been abandoned because of its belladonna reactions, as observed on several occasions. In one of our cases, the reduction of block in an auricular flutter resulted in an undesirably high ventricular rate in a postoperative patient. On the other hand, the use of scopolamine or atropine has not produced any undue tachycardia during the operative procedure.

Early in our series, the patients were induced with a minimum of pentothal,[®] then placed on a nitrous oxide-ether sequence, and intubated under direct vision with a cuffed endotracheal tube. The patients were then maintained on nitrous oxide-oxygen mixtures with small amounts of ether. One is quickly impressed with the extremely small amounts of anesthetic agent that these patients can tolerate without cardiovascular depression. One of the first patients anesthetized, 20 minutes after induction, had sudden hypotension and cardiac arrest just as intubation was being initiated. Since these patients do not tolerate any depth of anesthesia well, and since the anesthesia has to be deepest for intubation, it was decided in subsequent cases to avoid general anesthesia wherever possible and to intubate with topical anesthesia. Our procedure has been to instill 20 to 30 mg. of 1 per cent pontocaine[®] transalaryngeally following 10 per cent cocaine spray to the pharynx. Most of these patients have been intubated easily without any complications or cardiovascular depression. Following such intubation, pentothal is given until loss of consciousness is obtained and the patients are then maintained on nitrous oxide and oxygen. They are then carried in a very light plane of anesthesia with nitrous oxide and oxygen with the supplemental use of morphine intravenously or small amounts of ether.

A critical time occurs when these patients are turned from the

supine to the lateral position. There is frequently a drop in blood pressure, sometimes a very serious fall, even though the patient is in an extremely light plane of anesthesia. Since these patients have an average systolic blood pressure of 150, we believe that a systolic blood pressure over 100 is a critical minimum. Maintenance of blood pressure throughout the operation is a big problem. Prophylactically, we avoid excessive premedication and deep planes of anesthesia. Use of a dilute neo-synephrine® drip has proved to be most valuable. Serious arrhythmias, frequent with hypotension, often cease with the correction of the hypotension by this agent. Neo-synephrine® will often slow the heart rate, which may be beneficial in some cases. Because of venous spasm and tissue necrosis following the use of norepinephrine, neo-synephrine is our first choice; we have not seen any permanent benefit from the use of norepinephrine where neo-synephrine has failed.

The maintenance of anesthesia is a delicate balance between an anesthesia level that does not cause cardiovascular depression and one that provides satisfactory intrathoracic operating conditions. Endotracheal ether and oxygen will provide adequate oxygenation and suitable conditions for operation in most intrathoracic procedures, but it is either most difficult or impossible to do so in these patients without cardiovascular depression. After the pleura has been opened, we have supplemented a nitrous oxide-oxygen mixture either with small amounts of ether or with intravenous morphine. The specific action of morphine in suppressing the cough reflex makes it possible to combine a desirable light plane of anesthesia with a suitable quiet field for the surgical procedure. This presupposes gentleness in the maneuvers of the surgical team. If any evidence of hypoxia appears, 100 per cent oxygen is used with assisted respiration and frequent expansion of the lungs.

After the pleura has been closed, large amounts of nitrous oxide and oxygen mixture are used with the semiclosed method. At this time, these patients will open their eyes, show no evidence of pain, and lie quietly on the table, being cooperative and responsive to commands.

Some of the cardiovascular changes which were anticipated with complete occlusion of the aorta have not occurred. Instead of an anticipated extreme hypertension, elevations in systolic pressure have averaged 40 to 100 mm. of mercury, but occasionally no increase of pressure is measured (by auscultation in the upper extremities). After removal of the clamps, the precipitous fall in pressure may show a tendency to overshoot, recover temporarily, and then resolve into a secondary and a more gradual decline which may have to be checked by peripheral vasoconstrictors such as neo-synephrine (fig. 3).

Despite the pre-existence of serious conduction defects, exacerbation of these has not been conspicuous in our series. However, our awareness of the possibilities has caused the employment of the cathode-ray oscilloscope as well as a direct-writing electrocardiographic instrument.

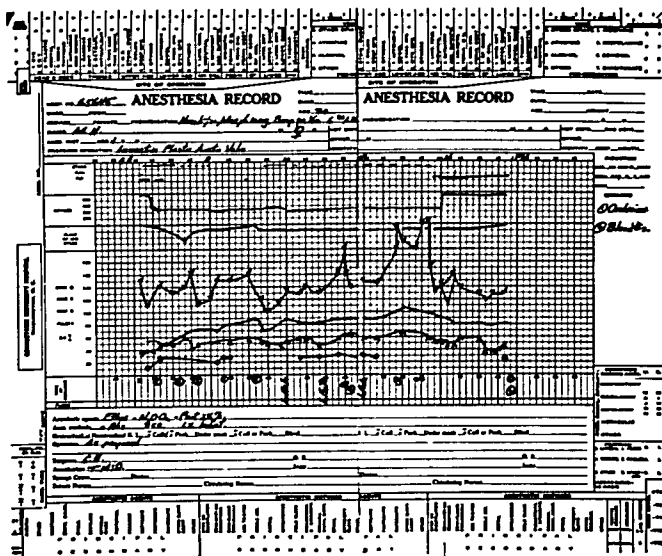


FIG. 3. Representative anesthesia record during insertion of prosthetic aortic valve (M.H.)

One case which suddenly developed ventricular tachycardia during the closure of the chest wall was treated with 1 Gm. of procaine amide in divided doses intravenously and reverted to a sinus rhythm, as illustrated in figure 4.

Another complication frequently seen is that of hypoxia, seemingly of a stagnant type, with arterial saturation clinically adequate, accompanied by extreme venous reduction. This occurs in the extremely critical patient, such as those with active rheumatic fever in irreversible heart failure. Assisted respiration with 100 per cent oxygen does not seem to relieve this situation. However, there is marked improvement associated with insertion of the valve. This clinical impression is confirmed by oxygen-saturation studies and cardiac-output estimations measured before and after the surgical procedure (8).

A summary is herewith appended of the items we think advisable in the conduction of these cases:

1. Continuous electrocardiographic tracing together with the visual use of the cathode-ray oscilloscope for these tracings. A cardiologist,

familiar with the routine changes accompanying general anesthesia, should be available to monitor these constantly.

2. Two intravenous infusions of 5 per cent glucose in water, using 15 gauge needles. Cut-downs are done, if necessary, to accomplish this.

3. A surgically exposed radial artery, isolated with ligatures around it. This serves 2 purposes: first, to withdraw blood in the event of extreme hypertension during occlusion of the aorta (this has been done only once), and, secondly, to give intra-arterial transfusion, if necessary, in case of catastrophic hemorrhage.

4. Blood transfusion adequate to replace blood loss. These patients receive an average of 800 cc. of blood plus another 500 cc. postoperatively on the day of operation.

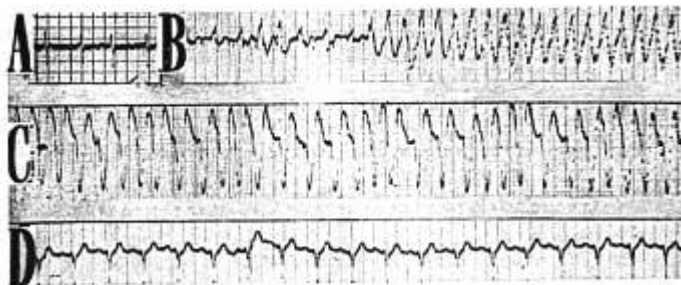


FIG. 4. Ventricular tachycardia treated with procaine amide during operation for insertion of prosthetic aortic valve. (A) Preoperative auricular fibrillation. (B) Onset of ventricular tachycardia. (C) Atypical ventricular foci. (D) Reversion to sinus rhythm after 1 Gm. of procaine amide intravenously.

5. Drugs: In general, we feel that as few drugs as possible should be used in these patients; however, some of the drugs which have proved important adjuncts are: neo-synephrine, prostigmine,[®] morphine, and cedilanid.[®] Other drugs less often used but none the less important are: quinidine, atropine, calcium, chloride, epinephrine, and procaine amide.

6. An electro-defibrillating machine is always available, although the essentials of cardiac resuscitation are adequate ventilation and cardiac massage. Cases where the electro-defibrillator has been effective in these massive hearts are not common.

The details of the postoperative care of these patients are covered adequately by Harvey *et al.* (9).

ANESTHETIC RESULTS

There were 11 deaths recorded in our series of 43 anesthetics; 1 patient was anesthetized twice. Three deaths occurred in the operating room, 2 deaths in the first 3 postoperative days, in which anesthesia may have been a factor, 4 sudden deaths apparently unrelated to anesthesia in the first 10 days postoperatively, and 2 deaths in patients discharged from the hospital but readmitted because of complications. Long-term results are beyond the scope of this presentation, but they are summarized by Harvey *et al.* (9).

In analyzing these deaths, it must be remembered that many of these patients will die suddenly without any such stress as that of anesthesia and surgery. During the 18-months period of this series, there were 5 patients who died while awaiting operation. Their circumstances varied; some were in the hospital undergoing investigation, one had been discharged to decide whether or not he would risk the procedure, and one died en route to the hospital by air. If the mortality of this series seems high, one should recall the incidence of sudden demise in these patients who were not subjected to either anesthesia or surgical intervention.

A. Deaths in the Operating Room:

These deaths occurred in patients in the terminal phase of their disease, their life expectancy being counted in days. All had uncontrollable congestive heart failure, decubitus ulcers from prolonged invalidism, and chronic hypoxia. These cases were really not feasible for operation because of their extreme critical condition, and their deaths are attributable to the underlying disease rather than the anesthesia and the surgery which were the precipitating factors.

1. The first case, occurring early in the series, was a 38 year old white male with a diagnosis of rheumatic aortic insufficiency, mitral stenosis, and insufficiency who had been in congestive heart failure. He had also angina and 50 per cent reduced vital capacity. Premedication of seconal[®], demerol[®], and scopolamine was judged to be satisfactory on his arrival in the operating room. Blood pressure was 150/60. The patient was induced with nitrous oxide, oxygen, and ether sequence. Induction was uneventful for 20 minutes, when the blood pressure dropped precipitously and ventricular standstill occurred. Cardiac resuscitation consisted of controlled ventilation with 100 per cent oxygen, cardiac massage, levophed[®] intravenously, and defibrillation. All were ineffective, though carried out for 2 hours.

2. The second case, also early in this series, was a 43 year old white male with a history of rheumatic aortic insufficiency with congestive heart failure for the past 2 years and with a progressively downward course as evidenced by dyspnea progressing to orthopnea, hydrothorax, and hepatomegaly. At the time of operation, his vital capacity

was at 1½ liters. He had pulsus alternans and decubitus ulcers. Premedication of nembutal® and demerol was judged to be satisfactory. The patient was intubated with transtracheal topical anesthesia, induced with pentothal and carried in a very light plane on nitrous oxide-oxygen with traces of ether intermittently. He was given 2 intravenous doses of 25 mg. of demerol. Blood pressure, which was initially 150/50, varied between 110 mm. systolic and 4 mm. diastolic and 130 mm. systolic and 40 mm. diastolic with a pulse of from 110 to 140. Anesthesia and operation proceeded satisfactorily for two and a half hours, prior to insertion of the valve. At this time, the patient was given a second dose of demerol to assure quiet conditions at the vital point of the operation. When the aorta was clamped, cardiac arrest occurred. Immediate cardiac massage was ineffective.

3. The third case, which occurred late in the series, was a 41 year old white male with rheumatic aortic insufficiency, mitral stenosis, and coarctation of the aorta. All three were scheduled for surgical correction. Premedication of nembutal and scopolamine was satisfactory. The pharynx was sprayed with 10 per cent cocaine and just enough pentothal given for loss of consciousness; then the patient was deepened by nitrous oxide and ether. Intubation 25 minutes later with oxygen and ether was uneventful. Blood pressure was 160 mm. systolic and 60 mm. diastolic and remained fairly stable at this level. Ventricular arrhythmias were noted on turning the patient to the lateral side. Transient tachycardia of 120 occurred as the pleura was opened. The condition of the patient was satisfactory for 3½ hours, while the coarctation was resected and replaced with a homologous graft. The pulse then suddenly increased to 180 per minute. Electrocardiographic diagnosis was paroxysmal auricular tachycardia. Prostigmine and cedilanid were ineffective. This tachycardia persisted for 20 minutes before responding to carotid pressure and the pulse rate became 80 per minute. The aorta was then clamped off for 4 minutes while the valve was inserted; 20 minutes later, ventricular fibrillation occurred. Cardiac resuscitation was ineffective.

B. There were 2 other cases in which anesthesia may have been a factor:

1. The first was a 56 year old white male with syphilitic aortic insufficiency in a hopelessly terminal phase as evidenced by decubitus ulcers, orthopnea, and hypoxia. He was intubated with topical anesthesia and carried on nitrous oxide and oxygen with traces of ether. Blood pressure was maintained at 120 mm. systolic and 40 diastolic to 140 systolic and 40 diastolic. Although he moved his extremities on stimulation, the patient never regained consciousness and died in 24 hours. It is remarkable that this patient did not die during the operation. Autopsy revealed cerebral thrombosis.

2. The second patient was a 43 year old colored female with rheumatic aortic insufficiency and extreme hepatomegaly. Her heart failure could not be controlled by any measure. Intubation was with topical anesthesia. Then she was maintained on oxygen and ether with small doses of demerol. Anesthesia was unsatisfactory because of repeated episodes of hypotension and hypoxia during the 4 hour procedure. She regained consciousness but hypotension persisted despite levophed drip and she died on the second postoperative day.

C. There were 4 cases of sudden death occurring on the fifth, the sixth, the seventh, and the ninth days postoperatively. All patients were out of oxygen tents and doing well. Autopsy revealed no positive cause of death. It is believed that death was due to sudden ventricular arrhythmia.

1. One of these deaths occurred in a 26 year old white female who was intubated with topical anesthesia, induced with pentothal, and maintained on light nitrous oxide-ether anesthesia. Just prior to opening the pleura, she developed hypotension which responded to neo-synephrine drip. One hour after the pleura had been opened, large amounts of vasopressors were required to maintain a systolic blood pressure of 100. Just prior to the insertion of the valve, it was decided to abandon the procedure because of hypoxia and persistent hypotension, despite adequate ventilation with oxygen and vasopressors. The patient was awake with skin suturing and made an uneventful recovery from the procedure.

This patient was anesthetized 12 days later with pentothal, nitrous oxide, and intravenous morphine. The 4-hour operation was completed successfully. Although hypotension was a problem, it was not so severe as in the previous operation. Vasopressors did not have to be used.

The patient developed pulmonary edema on the third postoperative day which responded to treatment. On the sixth day postoperatively she was given a transfusion because her hematocrit had dropped to 32. Following the blood transfusion, at a time when she appeared to be doing very well, she suddenly died. Autopsy could not reveal the cause of death.

D. Two later deaths that occurred in this series were:

1. Mesenteric thrombosis after discharge of the patient and
2. Death occurring after complications following amputation of the lower extremity due to arterial thrombotic occlusion.

E. An unusual death was the case of a 26 year old colored male who had experienced good results from this valve operation and returned to work. About 6 months after the operation, he was admitted to another hospital with a diagnosis of acute appendicitis. His cardiac status was known to all concerned as this prosthetic valve makes a

very audible clicking with each heart beat. This patient was given a spinal anesthesia and died immediately in the operating room despite cardiac massage. Autopsy revealed an intact plastic valve and regional ileitis.

DISCUSSION

We hold no brief for the mode of conduction of the anesthesia in these particular cases. Our thinking has gone through stages of evolution, and we expect further evolution in our methods until complete satisfaction has been attained; however, we have attempted to outline the pitfalls which have beset us in these first 42 patients. We are presenting this information so that others may avoid these difficulties and speed the conduction of the anesthetic management of this procedure in the direction of more perfect safety.

SUMMARY

1. The surgical procedure involved in the insertion of a prosthetic aortic valve for amelioration of aortic insufficiency is described.

2. The pathological physiology of this disease is outlined briefly with a summary of what is considered to be adequate preoperative preparation.

3. We have summarized our conduction of the anesthesia by means of topical endotracheal intubation with maintenance on light nitrous oxide and oxygen anesthesia supplemented by small amounts of ether or intravenous opiates. The difficulties encountered during these anesthetics are delineated.

4. Our results in 43 anesthetics administered to 42 patients with 5 deaths involving the anesthetic management are appended in detail.

REFERENCES

1. Levine, S.: *Clinical Heart Disease*, ed. 4, Philadelphia, W. B. Saunders Co., 1945, pp. 46-49, 167-168.
2. White, P. D.: *Heart Disease*, ed. 3, New York, Macmillan Co., 1944, pp. 621-627.
3. Hufnagel, C.: Aortic Plastic Valvular Prosthesis, *Bulletin, Georgetown Univ. Med. Center* 4: 128 (March) 1951.
4. Hufnagel, C., and Harvey, P.: Surgical Correction of Aortic Regurgitation: Preliminary Report, *Bulletin, Georgetown Univ. Med. Center* 6: 60 (Jan.) 1953.
5. Hufnagel, C., Harvey, P., Rabil, P., and McDermott, T. F.: Surgical Correction of Aortic Insufficiency, *Surgery* 35: 673 (May) 1954.
6. Rabil, P., and Garneau, G.: *Chirurgie des thromboses coronariennes*, *Union med. Canada* 81: 394 (April) 1952.
7. Pender, J. W.: Anesthesia for Mitral Commissurotomy, *Anesthesiology* 14: 77 (Jan.) 1953.
8. Rose, J., Hufnagel, C., Fries, E., Harvey, P., and Partenope, E.: Hemodynamic Alterations Produced by Plastic Valvular Prosthesis for Severe Aortic Insufficiency in Man, *J. Clin. Invest.* 33: 891 (June) 1954.
9. Hufnagel, C., Harvey, P., Segal, J., Ari, R., and Rabil, P.: Clinical Evaluation of First Forty-Two Patients with Severe Aortic Insufficiency Treated with Plastic Aortic Valve. To be published.