

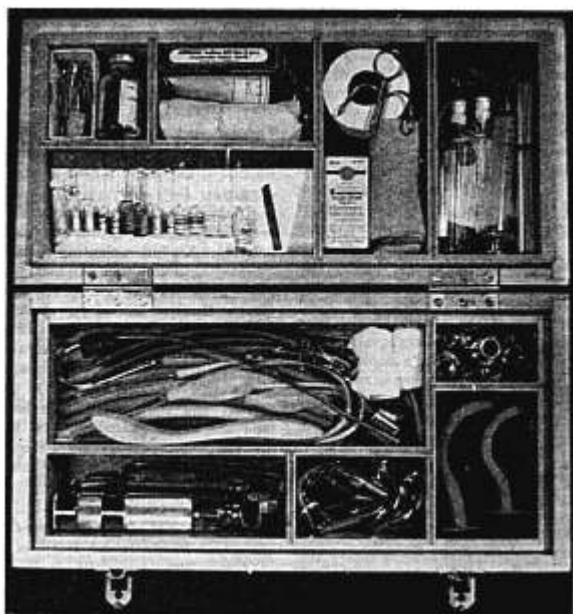FIG. 3. Kit open, ready for use.

- 1 MacIntosh laryngoscope blade
- 2 Saunderson's cuffs, 1 large, 1 medium
- 2 Aspirating catheters
- 2 Nasopharyngeal tubes
- 1 Stilette with rubber stopper

Lower Compartment

Masks: Large, medium and small
Sphygmomanometer and Stethoscope

These units have been in use for the past two years and have proved satisfactory. Each of our residents is provided with one

of these kits. A recent improvement has been the substitution of a drawer in the bottom of the chest for the top tray.

REFERENCE

1. Sanford, C. H.: Visible Ampules, *Anesthesiology* 5: 303 (May) 1944.

BERNARD D. BRIGGS, M.D.,
*Anesthesia Laboratory of the
Harvard Medical School
(Massachusetts General Hospital),
Boston 14, Massachusetts*

A NEW NASOPHARYNGEAL AIRWAY

Upper or supraglottic respiratory obstruction may occur as the result of anesthesia, foreign body or disease. In the absence of a foreign body or tumor, the

obstruction is usually the result of relaxed pharyngeal musculature, associated with decreased tonus of the muscles supporting the jaw. The base of the tongue ap-

proaches and makes contact with the posterior pharyngeal wall, interfering with the passage of air to the trachea.

The oropharyngeal airway is often employed to overcome this latter form of respiratory obstruction. It is passed over the dorsum of the tongue to the posterior pharynx, allowing air to enter and leave the trachea freely. The presence of the oropharyngeal airway guarantees separation of the tongue from the posterior pharyngeal wall and, by pressure along the base of the tongue because of its presence, the epiglottis is pulled slightly forward.

Another instrument which may overcome pharyngeal obstruction by the same mechanisms is the nasopharyngeal airway. It is unfortunate that the nasopharyngeal airway is not employed more often, for it has some advantages over the oropharyngeal airway. Utilization of the nasopharyngeal airway does not require full surgical anesthesia. It may be employed in the semiconscious patient, and may be passed in patients who suffer from acute hypoxia in whom trismus of the jaw may be present. It is better tolerated than the oropharyngeal airway by the semiconscious patient or the patient recovering from

anesthesia. It thus lends itself admirably for use in the patient recovering from general anesthesia.

Heretofore the nasopharyngeal airway has had two serious disadvantages. Its sharply beveled tip often caused epistaxis. On occasion, its open end has become lodged against the lateral pharyngeal wall so that it no longer served as an adequate airway.

To obviate these disadvantages, a tube was designed so that not only is the end blunted (A), but a slanting shelf is incorporated into the tube so that a catheter may be passed through it for suction purposes (B, C). In order that it may still serve as an airway even if the tube should become lodged against the lateral pharyngeal wall, a contralateral opening was incorporated into the tube (D).

Left and right tubes have been made, and are so designated, so that the larger of the two openings faces the midline. They are made of plastic and can be boiled.

MEYER SAKLAD, M.D.,
Chief, Dept. of Anesthesiology,
Rhode Island Hospital,
Providence, Rhode Island

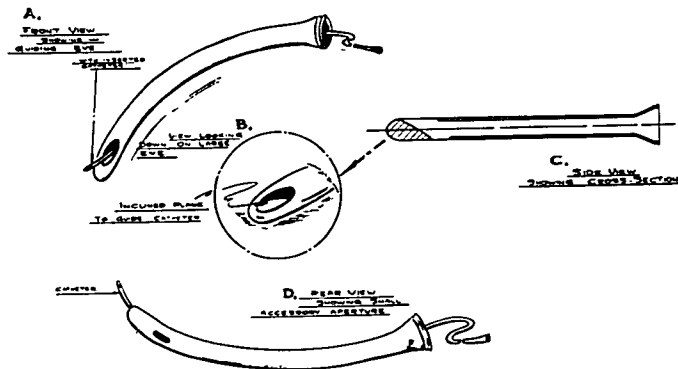


FIG. 1.