

E-cigarette and Vaping-associated Lung Injury

What's Lurking Inside!

Elizabeth M. Elliott, M.D., Ari Y. Weintraub, M.D., Catherine R. Francis, B.S.N., R.N., C.C.R.N., Robert B. Lindell, M.D.

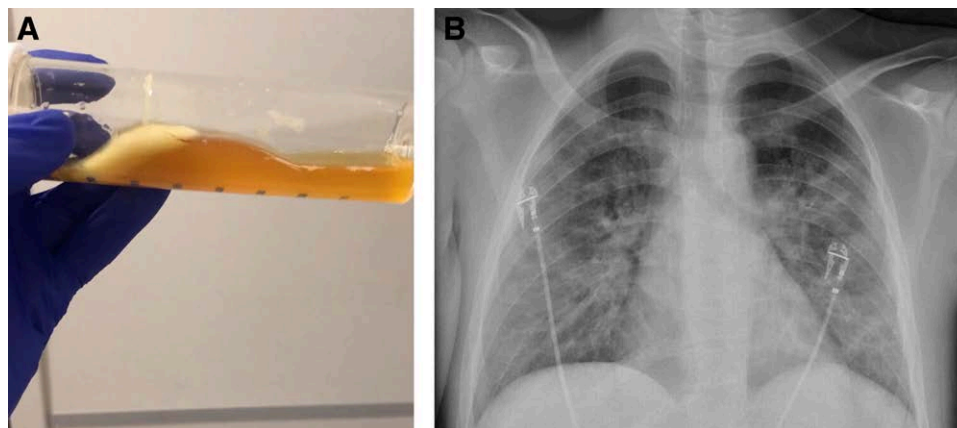


Image *A* shows bronchoalveolar lavage fluid from an intubated patient with severe lung injury due to electronic cigarette and vaping-associated lung injury which required extracorporeal support. Note the congealed mass, which based on color and viscosity likely represents bronchial deposits of vitamin E acetate.

Vitamin E acetate in bronchoalveolar lavage fluid has been identified by investigators at the Centers for Disease Control and Prevention as a potential cause of the acute lung injury in critically ill patients with electronic cigarette and vaping-associated lung injury.¹ Vitamin E acetate is a known diluent in nonregulated and illicit tetrahydrocannabinol, the psychotropic agent in marijuana-vape cartridges. Vitamin E acetate has gained popularity as an additive since late 2018 because of its color and viscosity, which mimic that of tetrahydrocannabinol. In contrast, vitamin E acetate has not been found in nicotine vape cartridges.²

Respiratory complaints are the most common presenting symptoms, and nearly half of all patients with electronic cigarette and vaping-associated lung injury require critical care for respiratory failure. The chest x-ray in image *B* demonstrates basilar consolidation and ground glass opacity in a patient with electronic cigarette and vaping-associated lung injury.¹ Research into the optimal clinical care of patients with electronic cigarette and vaping-associated lung injury is ongoing, but current clinical management guidelines for these high-risk patients have been published recently by Dodick and Greenberg for the Anesthesia Patient Safety Foundation.³

Competing Interests

The authors declare no competing interests.

Correspondence

Address correspondence to Dr. Elliott: Elliott1@email.chop.edu

References

1. Blount BC, Karwowski MP, Shields PG, Morel-Espinosa M, Valentin-Blasini L, Gardner M, Braselton M, Brosius CR, Caron KT, Chambers D, Corstvet J, Cowan E, De Jesús VR, Espinosa P, Fernandez C, Holder C, Kuklenyik Z, Kusovschi JD, Newman C, Reis GB, Rees J, Reese C, Silva L, Seyler T, Song MA, Sosnoff C, Spitzer CR, Tevis D, Wang L, Watson C, Wewers MD, Xia B, Heitkemper DT, Ghinai I, Layden J, Briss P, King BA, Delaney LJ, Jones CM, Baldwin GT, Patel A, Meaney-Delman D, Rose D, Krishnasamy V, Barr JR, Thomas J, Pirkle JL; Lung Injury Response Laboratory Working Group: Vitamin E acetate in bronchoalveolar-lavage fluid associated with EVALI. *N Engl J Med* 2020; 382:697–705
2. Ellington S, Salvatore PP, Ko J, Danielson M, Kim L, Cyrus A, Wallace M, Board A, Krishnasamy V, King BA, Rose D, Jones CM, Pollack LA; Lung Injury Response Epidemiology/Surveillance Task Force: Update: Product, substance-use, and demographic

Published online first on June 3, 2020. From the Children's Hospital of Philadelphia, Department of Anesthesiology and Critical Care Medicine, Perelman School of Medicine (E.M.E., A.Y.W., R.B.L.), and Heart and Vascular Intensive Care Unit, Penn-Presbyterian Medical Center (C.R.F.), University of Pennsylvania, Philadelphia, Pennsylvania.

Copyright © 2020, the American Society of Anesthesiologists, Inc. All Rights Reserved. *Anesthesiology* 2020; 133:427–8. DOI: 10.1097/ALN.0000000000003397

characteristics of hospitalized patients in a nationwide outbreak of E-cigarette, or vaping, product use-associated lung injury - United States, August 2019-January 2020. *MMWR Morb Mortal Wkly Rep* 2020; 69:44-9

3. Dodick T, Greenberg S: A patient with e-cigarette vaping associated lung injury (EVALI): Coming to an operating room near you! *Anesthesia Patient Safety Foundation* 2020; 35: 1-4