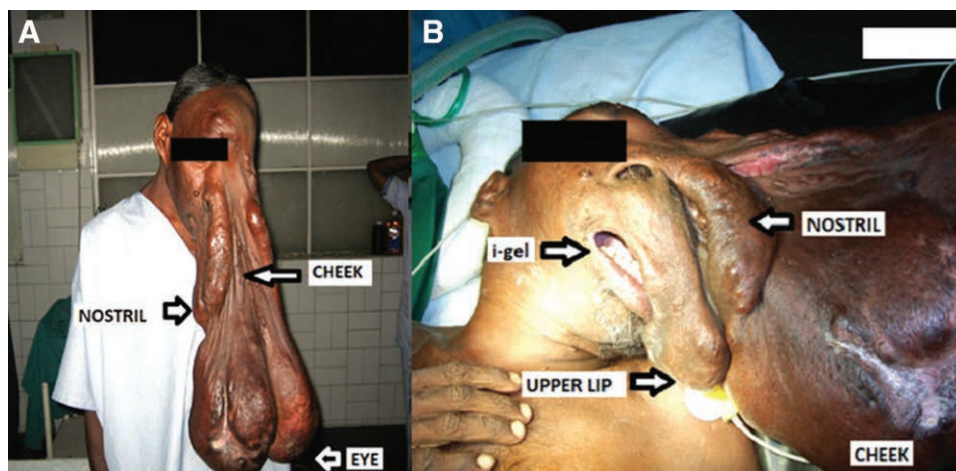


Massive Facial Plexiform Neurofibromatosis

Anesthetic Concerns

Rupam Sinha, M.D., Nishant Sahay, D.N.B.



Neurofibromas that involve more than a quarter of the face are called massive facial neurofibromas.¹ These can mechanically interfere with airway management and, coupled with a threat of massive intraoperative blood loss, can create a great challenge for anesthesia care.² We encountered such a case with a 40-yr-old, 66-kg man (A) scheduled for elective excision of plexiform neurofibromatosis. This patient's mouth and nose were involved with the mass, but he was able to breathe through either nose or mouth in sitting position. His mouth was visible, although mouth opening and neck movements were limited. General anesthesia after awake fiberoptic intubation was planned due to potentially difficult intubation and apparently impossible mask ventilation. Awake fiberoptic intubation attempts, however, had to be abandoned because the patient was unable to tolerate it and developed a panic attack. Preoxygenation was performed in the supine position. Induction started with incremental intravenous administration of fentanyl and propofol to ensure spontaneous breathing. Tracheal intubation with direct laryngoscopy was attempted twice, but unsuccessful. A supraglottic device, i-Gel (Intersurgical Ltd., United Kingdom) was inserted from the right side (B), by displacing the mass to the left.³ Subsequently, fiberoptic intubation through the i-Gel was successful. Management of such cases need well thought out planning. Awake fiberoptic intubation should be done with the emergency tracheostomy team on standby. It is important to maintain spontaneous breathing and minimize bleeding during intubation attempts. Insertion of a

supraglottic device is the key to ensure effective ventilation and serves as a conduit for fiberoptic intubation.

Competing Interests

The authors declare no competing interests.

Correspondence

Address correspondence to Dr. Sahay: nishantsahay@gmail.com

References

1. Bogdasarian RN, Fientisch AM, Langer PD, Datiashvili RO: Massive facial neurofibromas: Review of the literature, new classification system and case presentations. *Ann Surg Perioper Care* 2016; 1:1007
2. Latham K, Buchanan EP, Suver D, Gruss JS: Neurofibromatosis of the head and neck: Classification and surgical management. *Plast Reconstr Surg* 2015; 135:845–55
3. Lorenz G, Theiler M, Kleine-Kleue D, Brueggemann D, Kaiser N, Natalie Urwyler, Cedric Luyet, Andreas Vogt, Robert Greif, M. M. E. Unibe: Crossover comparison of the laryngeal mask supreme and the i-gel in simulated difficult airway scenario in anesthetized patients. *ANESTHESIOLOGY* 2009; 111:55–62

Published online first on January 16, 2020. From the Rangadore Memorial Hospital, Bengaluru, India (R.S.) and All India Institute of Medical Sciences Patna, Patna, India (N.S.).

Copyright © 2020, the American Society of Anesthesiologists, Inc. All Rights Reserved. *Anesthesiology* 2020; 132:1235. DOI: 10.1097/ALN.0000000000003137