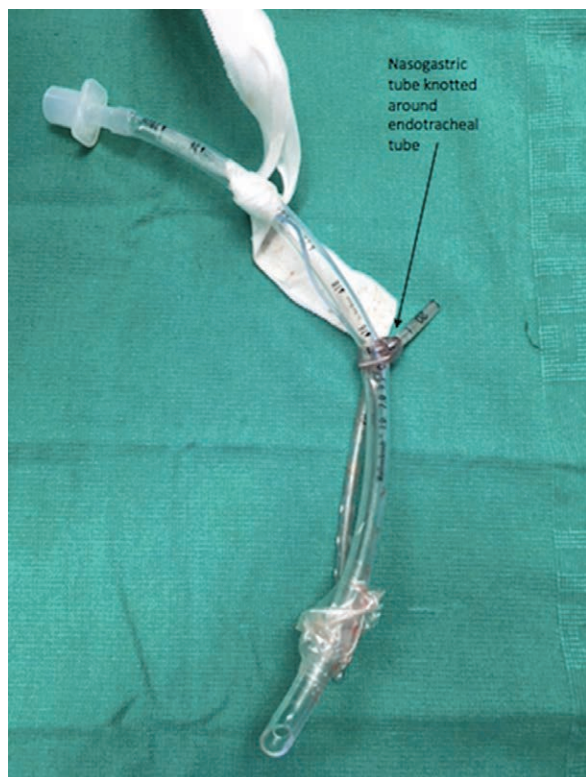


Ventilatory Collapse

Endotracheal Tube Strangulation from a Nasogastric Tube Knot

Sarah A. Dunn, M.D., M.P.H., Behrouz Ashrafi, M.D., Keith Candiotti, M.D., Yiliam F. Rodriguez-Blanco, M.D.



Complications of nasogastric tubes and orogastric tubes in anesthetized patients have been extensively documented.¹ The photograph represents an nasogastric tube that coiled around an endotracheal tube during insertion in an anesthetized patient and formed a tight knot around the endotracheal tube when removal was attempted. The knot around the endotracheal tube obstructed ventilation. When removal of the nasogastric tube was attempted, there was loss of end-tidal carbon dioxide with elevated peak airway pressures noted from the ventilator. Confirmation of the endotracheal tube obstruction was made *via* direct laryngoscopy. The patient was extubated, and the nasogastric tube was cut at the nares. The image is a photo taken after extubation. The literature describes nasogastric tubes and orogastric tubes that are placed in the tracheobronchial tree resulting in complications such as pneumothorax,

enteral feeding hydrothorax, and inadequate ventilation due to tracheobronchial suctioning under mechanical ventilation.^{1,2} Nasogastric tubes and orogastric tubes knotting around an endotracheal tube preventing ventilation is a rare occurrence.³ Anesthesiologists can diagnose this problem in the presence of inadequate ventilation with a loss of end-tidal carbon dioxide accompanied by high-pressure ventilator alarms despite no suction being applied to the nasogastric tube and orogastric tube. If there is resistance in attempting to remove an nasogastric tube and orogastric tube, there should be high suspicion of nasogastric tube and orogastric tube knotting and there should be no further attempts of gastric tube removal.² Nasogastric tube and orogastric tube knots in the oropharynx around an endotracheal tube can be removed to restore ventilation *via* direct laryngoscopy.^{2,3} Anesthesiologists need to recognize ventilatory obstruction, considering nasogastric tube and orogastric tube as an etiology and restoring ventilation as soon as possible, even if it requires emergency extubation with reintubation.

Competing Interests

The authors declare no competing interests.

Correspondence

Address correspondence to Dr. Dunn: sarah.dunn@jhsmiami.org

References

1. Pillai JB, Vegas A, Brister S: Thoracic complications of nasogastric tube: Review of safe practice. *Interact Cardiovasc Thorac Surg* 2005; 4:429–33
2. Chavda, V, Alhammali T, Farrant J, Naidu L, El-Rabaa S: Nasogastric tube knotting: A rare and potentially overlooked complication among healthcare professionals. *BMJ Case Rep* 2017; 2017:bcr2017220287
3. Pousman RM, Koch SM: Endotracheal tube obstruction after orogastric tube placement. *ANESTHESIOLOGY* 1997; 87:1247–8

From the University of Miami, Miami, Florida (B.A., K.C., Y.F.R.-B.); and Jackson Memorial Hospital, Miami, Florida (S.A.D., B.A., K.C., Y.F.R.-B.).

Copyright © 2019, the American Society of Anesthesiologists, Inc. All Rights Reserved. *Anesthesiology* 2019; 131:148. DOI: 10.1097/ALN.0000000000002670