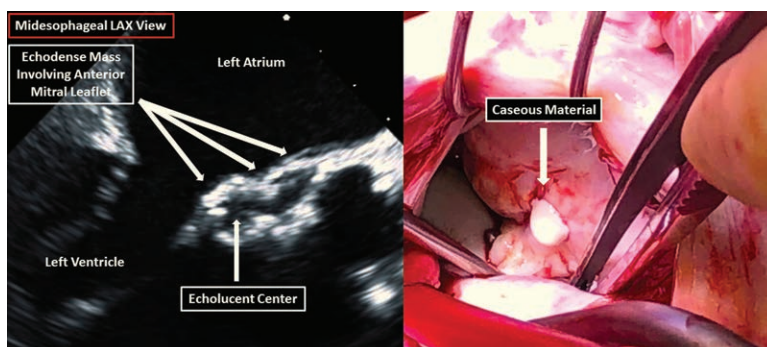


Caseous Calcification of the Mitral Annulus

Mimic and Malady

Alexander D. Shapeton, M.D., Abirami Kumaresan, M.D., David C. Liu, M.D., Megan L. Krajewski, M.D.



A 67-yr-old man presented for coronary artery bypass grafting and mitral valve replacement. Intraoperative transesophageal echocardiography unexpectedly demonstrated a mass involving the anterior mitral annulus and abnormality of the aortomitral curtain, prompting concern for an abscess. The mass's well-delineated, echodense borders and central echolucency were unusual, and absence of infectious sequelae or a history of endocarditis presented a diagnostic dilemma for the anesthesiologist (fig.; video, Supplemental Digital Content, <http://links.lww.com/ALN/B786>). The mass was best visualized in the midesophageal long axis view (LAX). Surgical inspection revealed extensive involvement of the mitral and aortic valves requiring replacement. Dissection of the mitral annulus liberated a thick paste-like substance, consistent with caseous calcification of the mitral annulus.

Typically, mitral annular calcification appears on transesophageal echocardiography as a dense band of tissue with significant acoustic shadowing. Caseous calcification of the mitral annulus is an uncommon variant of mitral annular calcification and is characterized by a rounded, echodense mass with central echolucency.^{1,2} Often, caseous calcification of the mitral annulus involves the posterior mitral annulus, but the location in this case was atypical. Although the cause of caseous calcification of the mitral annulus is unknown, the name “caseous” comes from the cheese-like consistency of the mass, which is sterile and composed of fatty acids, cholesterol, and calcium.³ Due to the rarity of caseous calcification of the mitral annulus, even experienced echocardiographers may mistake this finding for more pernicious conditions, such as intracardiac tumor, thrombus, or abscess.^{1–3} This lack of familiarity may lead to unwarranted surgical interventions.

Anesthesiologists performing intraoperative transesophageal echocardiography should be aware that, although caseous calcification of the mitral annulus often mimics pathologic conditions, its presence alone does not necessitate intervention. It is only when complications, such as valvular dysfunction, embolism, or conduction abnormalities, arise that caseous calcification of the mitral annulus becomes a malady requiring surgical treatment.

Competing Interests

The authors declare no competing interests.

Research Support

Support was provided solely from institutional and/or departmental sources.

Correspondence

Address correspondence to Dr. Shapeton: Shapeton88@yahoo.com

References

1. Iida R, Furuya T, Suzuki T: Giant caseous calcification of the mitral annulus identified by three-dimensional transesophageal echocardiography. *Anesth Analg* 2015; 121:62–4
2. Harpaz D, Auerbach I, Vered Z, Motro M, Tobar A, Rosenblatt S: Caseous calcification of the mitral annulus: A neglected, unrecognized diagnosis. *J Am Soc Echocardiogr* 2001; 14:825–31
3. Deluca G, Correale M, Ieva R, Del Salvatore B, Gramenzi S, Di Biase M: The incidence and clinical course of caseous calcification of the mitral annulus: A prospective echocardiographic study. *J Am Soc Echocardiogr* 2008; 21:828–33

Supplemental Digital Content is available for this article. Direct URL citations appear in the printed text and are available in both the HTML and PDF versions of this article. Links to the digital files are provided in the HTML text of this article on the Journal's Web site (www.anesthesiology.org).

From the Department of Anesthesia, Critical Care and Pain Medicine (A.D.S., A.K., M.L.K.) and Division of Cardiothoracic Surgery (D.C.L.), Beth Israel Deaconess Medical Center, Boston, Massachusetts.

Copyright © 2018, the American Society of Anesthesiologists, Inc. Wolters Kluwer Health, Inc. All Rights Reserved. *Anesthesiology* 2019; 130:311