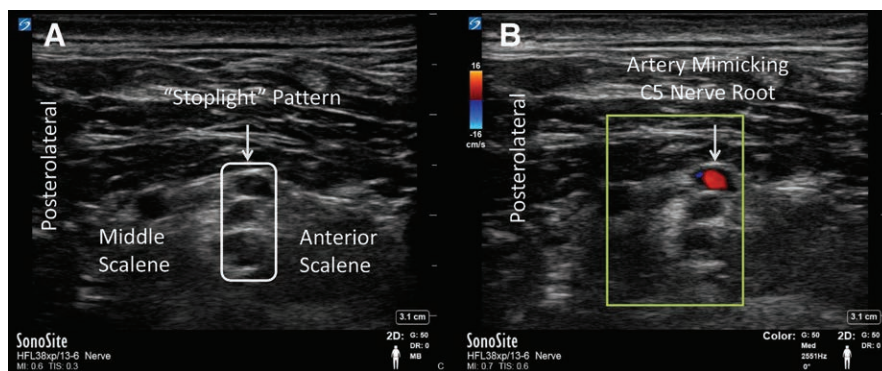


Interscalene Brachial Plexus Block

“Stoplight” That Lit Up Red

Adam W. Amundson, M.D., Hugh M. Smith, M.D., Ph.D.



oriented hypoechoic structures denoting C5 and C6 of the brachial plexus, lying between the anterior and middle scalene muscles.³ However, color Doppler imaging (image B) reveals blood flowing through a transverse cervical artery viewed in cross section, mimicking the sonographic appearance of the C5 nerve root (see the Supplemental Digital Content, <http://links.lww.com/ALN/B769>, a video that demonstrates color Doppler flow through the artery). Because ultrasound works by detecting differences in tissue density, anatomic structures with tissue homogeneity typically produce hypoechoic signals. In this case, blood inside an artery and solid neural tissue are both homogenous and of similar size, and misidentification may occur. Arterial and venous structures can be sonographically differentiated from neural structures through compressibility, pulsatility, and application of color Doppler. Image B highlights the importance of sonographic guidance, but underscores the need for awareness of anatomic features and their interpretation throughout interventional procedures.

Competing Interests

The authors declare no competing interests.

Correspondence

Address correspondence to Dr. Amundson: amundson.adam@mayo.edu

References

- McNaught A, Shastri U, Carmichael N, Awad IT, Columb M, Cheung J, Holtby RM, McCartney CJL: Ultrasound reduces the minimum effective local anesthetic volume compared with peripheral nerve stimulation for interscalene block. *Br J Anaesthesia* 2010; 106:124–30
- Sites BD, Brull R, Chan VWS, Spence BC, Gallagher J, Beach ML, Sites VR, Abbas S, Hartman GS: Artifacts and pitfall errors associated with ultrasound-guided regional anesthesia. Part II: A pictorial approach to understanding and avoidance. *Reg Anesth Pain Med* 2007; 32:419–33
- Franco CD, Williams JM: Ultrasound-guided interscalene block: Reevaluation of the “stoplight” sign and clinical implications. *Reg Anesth Pain Med* 2016; 41:452–9

Supplemental Digital Content is available for this article. Direct URL citations appear in the printed text and are available in both the HTML and PDF versions of this article. Links to the digital files are provided in the HTML text of this article on the Journal's Web site (www.anesthesiology.org).

From the Department of Anesthesiology and Perioperative Medicine, Mayo Clinic College of Medicine and Science, Rochester, Minnesota.

Copyright © 2018, the American Society of Anesthesiologists, Inc. Wolters Kluwer Health, Inc. All Rights Reserved. *Anesthesiology* 2018; 129:1166