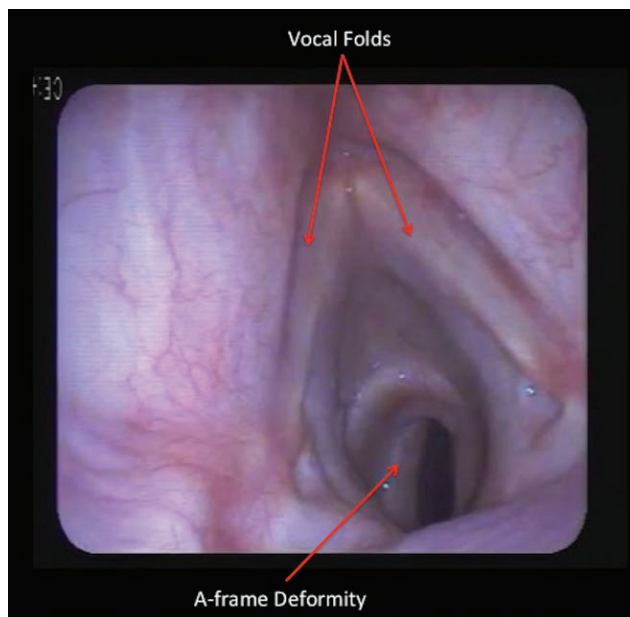


# Tracheal A-frame Deformity: A Challenging Variant of Tracheal Stenosis

Rohesh J. Fernando, M.D., Lyndsay L. Madden, D.O.



**T**RACHEAL stenosis after tracheostomy has a reported incidence of 6 to 21% and most commonly occurs secondary to granulation tissue around the stoma or cuff site or circumferential scarring ensuing due to pressure necrosis.<sup>1,2</sup> Alternatively, a variant known as a tracheal “A-frame” deformity (see image) can develop, which results from loss of anterior support from tracheal rings.<sup>3</sup> Consequently, there is inward collapse of the lateral tracheal walls, which gives the trachea the characteristic “A” shape at the previous stoma site.

These patients can be difficult to intubate. Preoperatively, concerning symptoms include dyspnea on exertion, cough, and inability to clear secretions. Stridor indicates significant stenosis and necessitates emergent intervention.<sup>3</sup> History and physical exam alone cannot differentiate between tracheal stenosis variants. Bronchoscopy or imaging such as computed tomography is necessary for specific diagnosis. Unlike typical circumferential subglottic stenosis, tracheal balloon dilations are of limited utility. Tracheal resection represents definitive management.<sup>3</sup> Given these

treatment options, strategies such as awakening asymptomatic patients<sup>1</sup> or case cancellation with referral for treatment may not result in further optimization of airway anatomy.

Avoidance or use of short-acting or immediately reversible neuromuscular blockers may be preferable in case of failed intubation. Knowledge of the anatomy should guide intubation strategies. As with circumferential subglottic narrowing, smaller endotracheal tubes (ETTs) should be available given the decreased lateral tracheal dimensions. In addition, the ETT may require rotation to ensure tip advancement is unobstructed by the lateral tracheal walls. A fiber-optic bronchoscope may be helpful in providing direct visualization for correct ETT positioning while avoiding traumatic intubation.

## Competing Interests

The authors declare no competing interests.

## Correspondence

Address correspondence to Dr. Fernando: rfernan@wakehealth.edu

## References

1. Nimmagadda UR, Salem MR, Friedman M, Lenz RF: Acute management of unsuspected subglottic stenosis by tracheal dilation. *Anesth Analg* 1995; 80:841–3
2. Sarper A, Ayten A, Eser I, Ozbudak O, Demircan A: Tracheal stenosis after tracheostomy or intubation: Review with special regard to cause and management. *Tex Heart Inst J* 2005; 32:154–8
3. Plojoux J, Laroumagne S, Vandemoortele T, Astoul PJ, Thomas PA, Dutau H: Management of benign dynamic “A-shape” tracheal stenosis: A retrospective study of 60 patients. *Ann Thorac Surg* 2015; 99:447–53

Charles D. Collard, M.D., served as Handling Editor for this article. The work presented in this article has been presented at the American Society of Anesthesiologists Annual Meeting in Boston, Massachusetts, on October 21, 2017.

From the Cardiothoracic Section, Department of Anesthesiology (R.J.F.), and the Department of Otolaryngology (L.L.M.), Wake Forest School of Medicine, Winston-Salem, North Carolina.

Copyright © 2018, the American Society of Anesthesiologists, Inc. Wolters Kluwer Health, Inc. All Rights Reserved. *Anesthesiology* 2018; 128:1240