

References

1. Sadeghi N, Kumar A, Kim J, Dooley J: Ultrasound-guided intraarticular knee injection. *ANESTHESIOLOGY* 2017; 127:565
2. Martino F, Angelelli G, Ettorre GC, Macarini L, Patella V, Moretti B, Pesce V, Nardella M: The normal aspect of the suprapatellar bursa in echography of the knee [article in Italian]. *Radiol Med* 1992; 83:43–8

(Accepted for publication February 8, 2018.)

Method for Intraarticular Knee Injection

To the Editor:

With regard to the article, “Ultrasound-guided Intraarticular Knee Injection,” by Sadeghi *et al.*,¹ we applaud the authors on their search for a superior technique for ultrasound-guided intraarticular knee injections. These injections often appear simple but can be quite challenging. However, we believe that the authors may be incorrect in the labeling of their images. In the authors’ diagram of the knee flexed at 90°, they appear to have labeled the trochlear cartilage as a suprapatellar bursa. Though injecting directly superficial to the cartilage may allow for an intraarticular injection, the risk of cartilage injury from the needle increases.

The suprapatellar bursa often becomes more difficult to visualize with the knee flexed at 90° because it becomes flattened, and often abuts the femoral trochlear cartilage, which

can easily be visualized as a thick hypoechoic stripe superficial to the femoral cortex. The cartilage does not narrow with manual compression with the ultrasound probe, as fluid often does. Figure 1 labels the relatively flat suprapatellar bursa superficial to the more prominent trochlear cartilage when the knee is in partial flexion. As flexion increases, the suprapatellar bursa often disappears. A needle that is successfully placed in this thin potential space will be recognized upon injection, as there will not be local pooling of injectate due to it dissipating into the larger joint capsule, in addition to minimal resistance to flow of injectate.

Additionally, we propose an additional method of identifying the suprapatellar bursa by asking patients with a supine, extended knee to contract their quadriceps muscle, which often creates a pooling of joint fluid in the superolateral joint recess. This becomes a ready target for ultrasound-guided intraarticular knee injection.

Competing Interests

The authors declare no competing interests.

Daniel M. Cushman, M.D., Justin C. Bosley, M.D.
University of Utah, Salt Lake City, Utah (D.M.C.). dan.cushman.work@gmail.com

References

1. Sadeghi N, Kumar A, Kim J, Dooley J: Ultrasound-guided intraarticular knee injection. *ANESTHESIOLOGY* 2017; 127:565

(Accepted for publication February 8, 2018.)

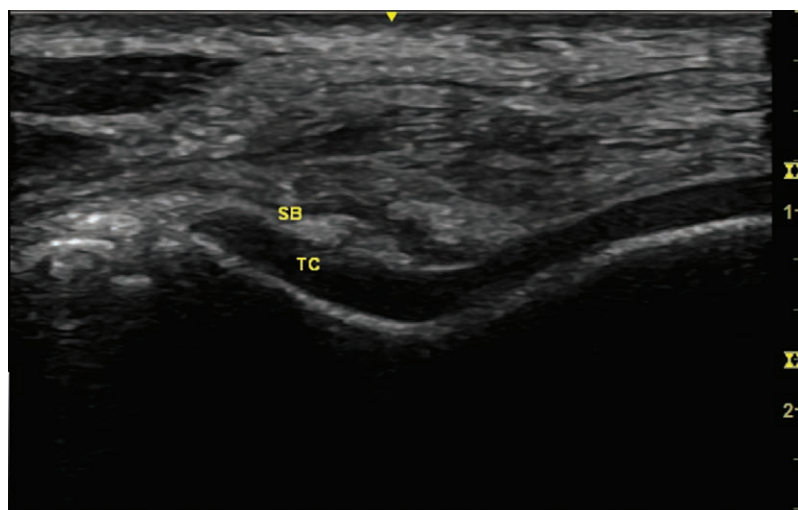


Fig. 1. Axial plane ultrasonographic view at the level of the femoral trochlea in the knee. The knee is flexed to about 60°, and light pressure is applied to the probe. Suprapatellar bursa (SB), the thin hypoechoic stripe, is approximately 1 mm superficial to the trochlear cartilage (TC), the thick hypoechoic stripe.

This letter was sent to the authors of the original article referenced above, who declined to respond.—Evan D. Kharasch, M.D., Ph.D., Editor-in-Chief.