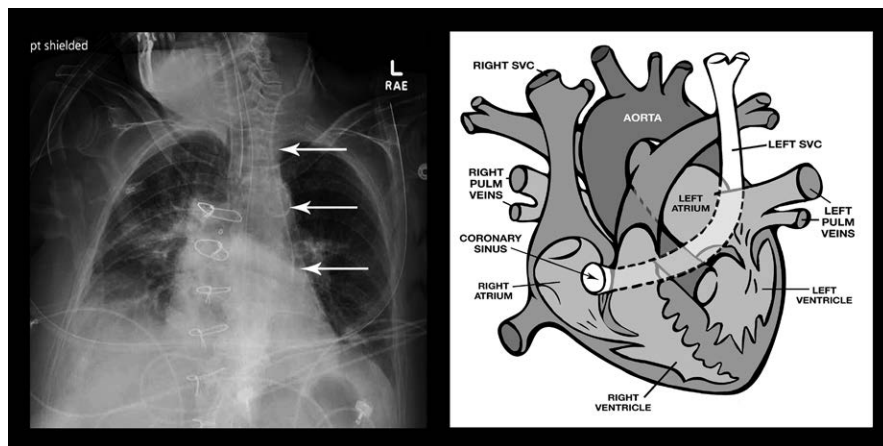


Persistent Left Superior Vena Cava

Unusual Catheter Position on Chest X-ray Film

Ranjit Deshpande, M.D., Matthew Band, P.A., Viji Kurup, M.D.



CONGENITAL anomalies of the great veins of the neck are relatively infrequent. Persistent left superior vena cava (PLSVC) is an embryologic remnant of the left superior cardinal vein seen in 0.1 to 0.3% of healthy adults.¹ PLSVC runs between the left pulmonary veins and the left atrial appendage enlarging the coronary sinus as it enters the atrium. When present, it can affect placement of central catheters, pacemakers, and cardiopulmonary bypass. It is

important to be aware of this variation and to recognize it in imaging studies.

Patients with PLSVC are usually asymptomatic but can have associated cardiac anomalies such as atrial septal defect, cor triatriatum, and mitral atresia.² Diagnosis is by chest x-ray showing widening above the aortic knob or a dilated coronary sinus on echocardiography. It is confirmed by injecting agitated saline in the left arm vein and observing bubbles in the coronary sinus.

The accompanying image shows the central venous catheter (*arrows*) placed in a patient who needed central access for pressor support (in the illustration on the *right*, SVC = superior vena cava). A catheter is seen on the left of the mediastinum entering the coronary sinus. In patients with known anomaly of the great veins, the recommendation is for preoperative imaging and guidance for safe placement of catheters. In 10% of patients, the PLSVC drains into the left atrium with a potential for embolic complications.¹ PLSVC is a relative contraindication to retrograde cardioplegia as the coronary sinus may not be adequately occluded with the catheter balloon.³

Acknowledgments

The authors thank Garrett Sendlewski, B.F.A., Department of Anesthesiology, Yale University, New Haven, Connecticut, for his help with editing the images in this article.

Competing Interests

The authors declare no competing interests.

Correspondence

Address correspondence to Dr. Deshpande: ranjit.deshpande@yale.edu

References

1. Rossi UG, Rigamonti P, Torcia P, Mauri G, Brunini F, Rossi M, Gallieni M, Cariati M: Congenital anomalies of superior vena cava and their implications in central venous catheterization. *J Vasc Access* 2015; 16:265–8
2. Higgs AG, Paris S, Potter F: Discovery of left-sided superior vena cava during central venous catheterization. *Br J Anaesth* 1998; 81:260–1
3. Roberts WA, Risher WH, Schwarz KQ: Transesophageal echocardiographic identification of persistent left superior vena cava: Retrograde administration of cardioplegia during cardiac surgery. *ANESTHESIOLOGY* 1994; 81:760–2

From the Department of Anesthesiology, Yale University School of Medicine, New Haven, Connecticut (R.D., V.K.); and the Surgical Intensive Care Unit, Yale New Haven Hospital, New Haven, Connecticut (M.B.).

Copyright © 2017, the American Society of Anesthesiologists, Inc. Wolters Kluwer Health, Inc. All Rights Reserved. *Anesthesiology* 2017; 127:165