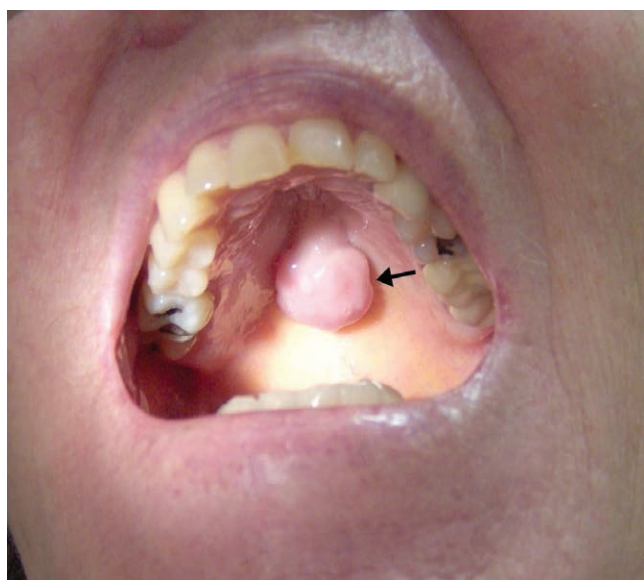


Images in Anesthesiology: Torus Palatinus and Airway Management

Jesse Aron, M.D., Stephen J. Raithel, B.A., Andrew J. Mannes, M.D.



TORUS palatinus is a bony exostosis of the maxilla that affects 20 to 30% of people in the United States.¹ Tori can be unilobular or multilobulated and pedunculated or flat. Large tori that protrude more than 5 mm from the maxilla comprise less than 5% of tori.² The accompanying image is of a pedunculated torus palatinus measuring 2 cm in diameter, found during the preoperative evaluation of a patient. There is no definitive explanation as to why torus palatinus occurs, although genetic factors, superficial injuries, and palate stress from mastication are thought to play a role.¹

These bony growths are covered by a thin mucosa that is susceptible to lacerations,¹ which could cause perioperative bleeding and swelling if traumatized. Large tori can develop sites that trap food,² shown in the photograph with a potential cavity between the base of the lesion and the hard palate (arrow), thus posing an aspiration risk if any trapped food material is dislodged while establishing an airway. A modified technique for insertion of a laryngeal mask airway in patients with a large palatal torus has been described, involving folding and guiding the cuff flaps around the mass.³ Injury to the

torus with other items frequently placed in the oropharynx should also be avoided, such as when placing orogastric tubes, esophageal temperature probes, oral airways, or transesophageal ultrasound transducers. With proper preoperative evaluation and care to avoid trauma to the mucosa, the risks of aspiration, perioperative bleeding, and postoperative pain for the patient can be minimized.

Research Support

Supported by intramural funding from the National Institutes of Health Clinical Center, Bethesda, Maryland.

Competing Interests

The authors declare no competing interests.

Correspondence

Address correspondence to Dr. Mannes: mannese@nih.gov

References

1. Loukas M, Hulsberg P, Tubbs RS, Kapos T, Wartmann CT, Shaffer K, Moxham BJ: The tori of the mouth and ear: A review. *Clin Anat* 2013; 26:953–60
2. García-García AS, Martínez-González JM, Gómez-Font R, Soto-Rivadeneira A, Oviedo-Roldán L: Current status of the torus palatinus and torus mandibularis. *Med Oral Patol Oral Cir Bucal* 2010; 15:e353–60
3. Schwartz AJ: Insertion of a folded laryngeal mask airway around a palatal torus. *AANA J* 2005; 73:211–6

From the Overlook Medical Center, Summit, New Jersey (J.A.); Cleveland Clinic Lerner College of Medicine of Case Western Reserve University, Cleveland, Ohio (S.J.R.); and Department of Perioperative Medicine, Clinical Center, National Institutes of Health, Bethesda, Maryland (A.J.M.).

Copyright © 2017, the American Society of Anesthesiologists, Inc. Wolters Kluwer Health, Inc. All Rights Reserved. *Anesthesiology* 2017; 127:164