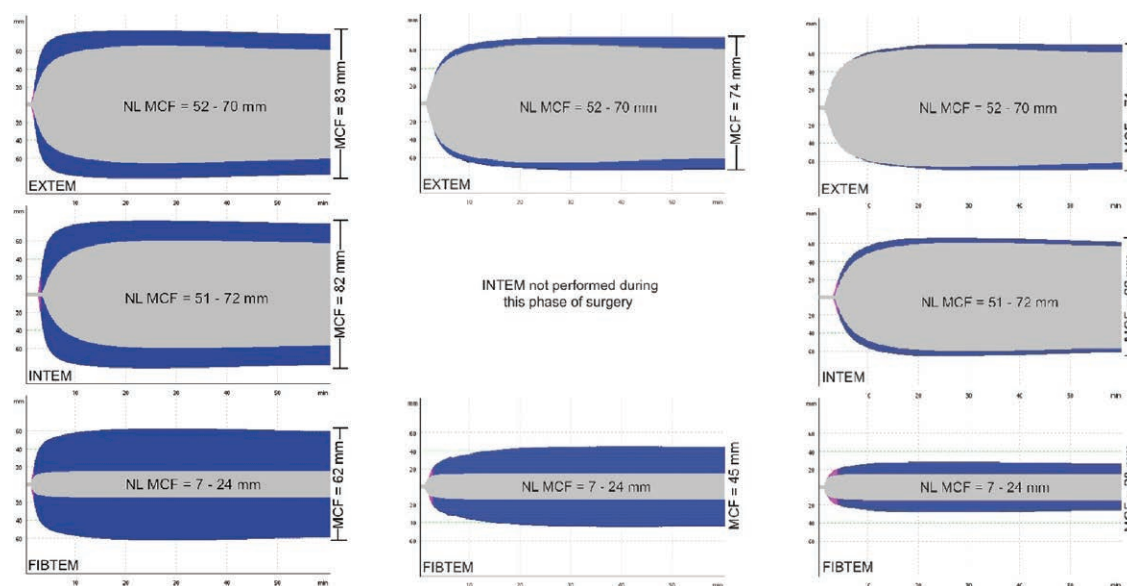


Images in Anesthesiology: Hypercoagulability during Resternotomy for Prosthetic Valve Endocarditis

Andrew L. Wilkey, M.D., Judah A. Askew, M.D., Robert S. Farivar, M.D., Tjorvi E. Perry, M.D.



APPROPRIATE management of coagulopathy during resternotomy for prosthetic valve endocarditis can reduce associated postoperative morbidity and mortality.¹ While published literature suggests that endocarditis may be associated with overt hypercoagulability,² sepsis is also associated with consumptive coagulopathy followed by pathologic bleeding.³ We present a series of intraoperative thromboelastograms from a patient undergoing replacement of an infected prosthetic aortic valve.

The thromboelastogram is a reaction curve representing changes in clot viscoelasticity over time. Maximum clot firmness (MCF) represents the maximal strength of the platelet and/or fibrin clot and can be both a sensitive and specific parameter when assessing hypercoagulability. When low, MCF can signify decreased platelet number or function, decreased fibrinogen or defects of fibrin polymerization, or low factor XIII activity. In these images, *gray areas* represent normal thromboelastogram tracings with normal (NL) MCF ranges for each identified within. *Blue areas* represent patient's thromboelastogram tracings. MCF value for each assay appears horizontally to the right of each thromboelastogram. In this case, preincision thromboelastographic results demonstrate MCF in the extrinsic pathway (EXTEM), intrinsic pathway (INTEM), and fibrin clot (FIBTEM) assays outside the normal reference ranges, suggesting hypercoagulability (*left figures*). During rewarming on cardiopulmonary bypass (CPB), the thromboelastogram continues to demonstrate high MCF in the EXTEM, FIBTEM, and HEPTM (intrinsic pathway with heparinase) assays, suggesting continued hypercoagulability, albeit less so, consistent with CPB-related clotting factor consumption (*center figures*). MCF continues to normalize after separation from CPB and protamine administration (*right figures*). Based on these results, the patient received no intraoperative blood product.

Competing Interests

The authors declare no competing interests.

Correspondence

Address correspondence to Dr. Wilkey: andrewwilkey@icloud.com

References

- Rosamel P, Cervantes M, Tristan A, Thivolet-Béjui F, Bastien O, Obadia J, Lehot J: Active infectious endocarditis: Postoperative outcome. *J Cardiothorac Vasc Anesth*. 2005; 19:435–9
- Gencbay M, Turan F, Degertekin M, Eksi N, Mutlu B, Unalp A: High prevalence of hypercoagulable states in patients with recurrent thrombosis of mechanical heart valves. *J Heart Valve Dis* 1998; 7:601–9
- Thachil J: Disseminated intravascular coagulation: A practical approach. *ANESTHESIOLOGY* 2016; 125:230–6

From the Department of Anesthesia, American Anesthesiology of Minnesota (A.L.W., T.E.P.) and Minneapolis Heart Institute Cardiovascular Surgery (J.A.A., R.S.F.), Abbott Northwestern Hospital, Minneapolis, Minnesota.

Copyright © 2017, the American Society of Anesthesiologists, Inc. Wolters Kluwer Health, Inc. All Rights Reserved. *Anesthesiology* 2017; 126:978