Jerrold H. Levy, M.D., F.A.H.A., F.C.C.M., Editor

Anesthesia for Ophthalmic Artery Chemosurgery

Jacques H. Scharoun, M.D., Jung H. Han, M.D., Y. Pierre Gobin, M.D.

Downloaded from http://asa2.silverchair.com/anesthesiology/article-pdf/126/1/165/375009/20170100_0-00030.pdf by guest on 16 April 2024

Scenario

A 2-yr-old boy with retinoblastoma is undergoing intra-arterial chemotherapy with general endotracheal anesthesia. His right femoral artery was cannulated, and a microcatheter was advanced toward the internal carotid artery (ICA). As the catheter tip nears the orifice of the ophthalmic artery (OA), the tidal volume abruptly drops 75%. No wheezing is heard, but albuterol is given, with little improvement, and the patient desaturates. After 3 min of hand ventilation, his tidal volumes improve, but he then becomes bradycardic and hypotensive. He ultimately requires several doses of epinephrine and intravenous volume expansion to stabilize his vital signs. At the conclusion of the procedure, he returns to baseline, is extubated, and has an unremarkable course in the recovery room.

Overview

Retinoblastoma is a rare tumor of the eye, affecting primarily children, with an estimated global incidence of 6,000 to 8,000 annually. It accounts for 6% of all malignancies in children under 5 yr.[1] If left untreated, it leads to an almost 95% mortality rate due to metastasis in the brain.[2] Treatment goals include preservation of both life and vision. There are a variety of therapeutic options, each with its drawbacks.

Enucleation can cure retinoblastoma by removal of the eye. For the 25% of patients presenting with bilateral disease, this is a poor option. For the rest, the treated eye loses 100% of its vision with this technique.[2]

Radiation therapy (both external beam and radioactive plaque placement) has been used for more than 100 yr to cure retinoblastoma, but it can induce secondary neoplasms (with a high mortality) and leave facial bony deformities, cataracts, and glaucoma.[2,3]

Cryotherapy and laser therapy are additional modalities that are curative for small tumors, with minimal side effects. Unfortunately, 80% of patients at presentation have tumors that are too large to be treated effectively in this way. As such, these focal techniques are mostly useful as an adjunct to other treatments.[2]

Systemic chemotherapy, including carboplatin, is used to treat patients with large or multiple tumors.[2] Intravenous chemotherapy can reduce tumor bulk, making it amenable to focal destruction using laser or cryotherapy.[4] Side effects of systemic chemotherapy include neutropenia, deafness, infections, and secondary leukemia.[2]

In an effort to reduce the systemic side effects and maximize the effectiveness of chemotherapeutic agents against retinoblastoma, direct intraarterial chemotherapy for retinoblastoma (also known as OA chemosurgery) is being performed with increasing frequency around the world.[2,5]

Relevant Anatomy of Carotid and OA

The ICA arises from the common carotid artery and courses through the cavernous sinus, giving rise to the OA before terminating as the anterior and middle cerebral arteries.[6] The external carotid artery (ECA) arises from the common carotid artery and supplies the maxillary artery. Two branches of the maxillary artery of importance for OA chemosurgery are the middle meningeal artery (MMA) and the sphenopalatine artery (fig. 1).[6]

The OA gives off multiple branches. The central retinal artery supplying the retina and the ciliary arteries supplying the choroid are the target vessels to deliver chemotherapy to the retinoblastoma tumor, but they are not directly cannulated. Other branches include the anterior and posterior ethmoidal arteries, lacrimal artery, and supraorbital and dorsal nasal arteries.[6]

Although the OA arises from the ICA, there are several potential sites of anastomosis with the ECA circulation that can affect the success of OA chemosurgery. The OA can anastomose with, and sometimes directly arise from, the MMA.[6,7] The anterior ethmoid artery can anastomose with the sphenopalatine artery in the nose.[6]

This article is featured in "This Month in Anesthesiology," page 1A. Figures 1 and 4 were enhanced by Annemarie B. Johnson, C.M.I., Medical Illustrator, Vivo Visuals, Winston-Salem, North Carolina.

Submitted for publication April 15, 2016. Accepted for publication September 1, 2016. From the Department of Anesthesiology (J.H.S., J.H.H.) and Department of Interventional Neuroradiology (Y.P.G.), New York Presbyterian Hospital, Weill Cornell Medicine, New York, New York.

Copyright © 2016, the American Society of Anesthesiologists, Inc. Wolters Kluwer Health, Inc. All Rights Reserved. Anesthesiology 2017; 126:165–72

Copyright © 2016, the American Society of Anesthesiologists, Inc. Wolters Kluwer Health, Inc. Unauthorized reproduction of this article is prohibited.
<zdoi;10.1097/ALN.0000000000001381>

History of Intraarterial Chemotherapy

Intraarterial chemotherapy for retinoblastoma began in 1955 with drug delivery into the ICA ipsilateral to the tumor by direct carotid puncture.[5]

In the 1980s, Japanese researchers accessed the carotid circulation *via* a femoral artery puncture, directing a balloon-tipped catheter into the ICA. The balloon was inflated distal to the OA orifice, and the chemotherapy agent (melphalan) was injected proximal to the balloon in a rapid manner.[8,9] This technique is called selective ophthalmic artery infusion (SOAI). There are two potential disadvantages to this technique. The first is temporary occlusion of blood supply to the anterior and middle cerebral arteries during the injection. However, Suzuki *et al.*[8] reported zero instances of cerebral infarction in a series of 343 patients. The second disadvantage is possible unintended drug administration to other proximal branches of the ICA.[9]

Twenty years later, technologic improvements allowed American researchers to safely advance a microcatheter directly into the OA under fluoroscopic guidance. Known as super-SOAI or OA chemosurgery, this allows precise targeting of the drug into the tumor.[2,5] Currently, this is the method used at our institution.

Technique of OA Chemosurgery at Weill Cornell Medicine (New York, New York)

All patients receive general endotracheal anesthesia and are mechanically ventilated with pressure control.[1] The exhaled tidal volume is closely monitored throughout the procedure. Anesthesia is maintained with volatile anesthetics and neuromuscular blockade to ensure absolute immobility during the catheter manipulations (table 1). After intubation, the patient's head is elevated temporarily, and a topical vasoconstrictor (oxymetazoline 0.05%) is sprayed upright into the nares ipsilateral to the tumor.[5] Albuterol and diphenhydramine were once routinely given prophylactically; this practice has been discontinued as it did not reliably prevent

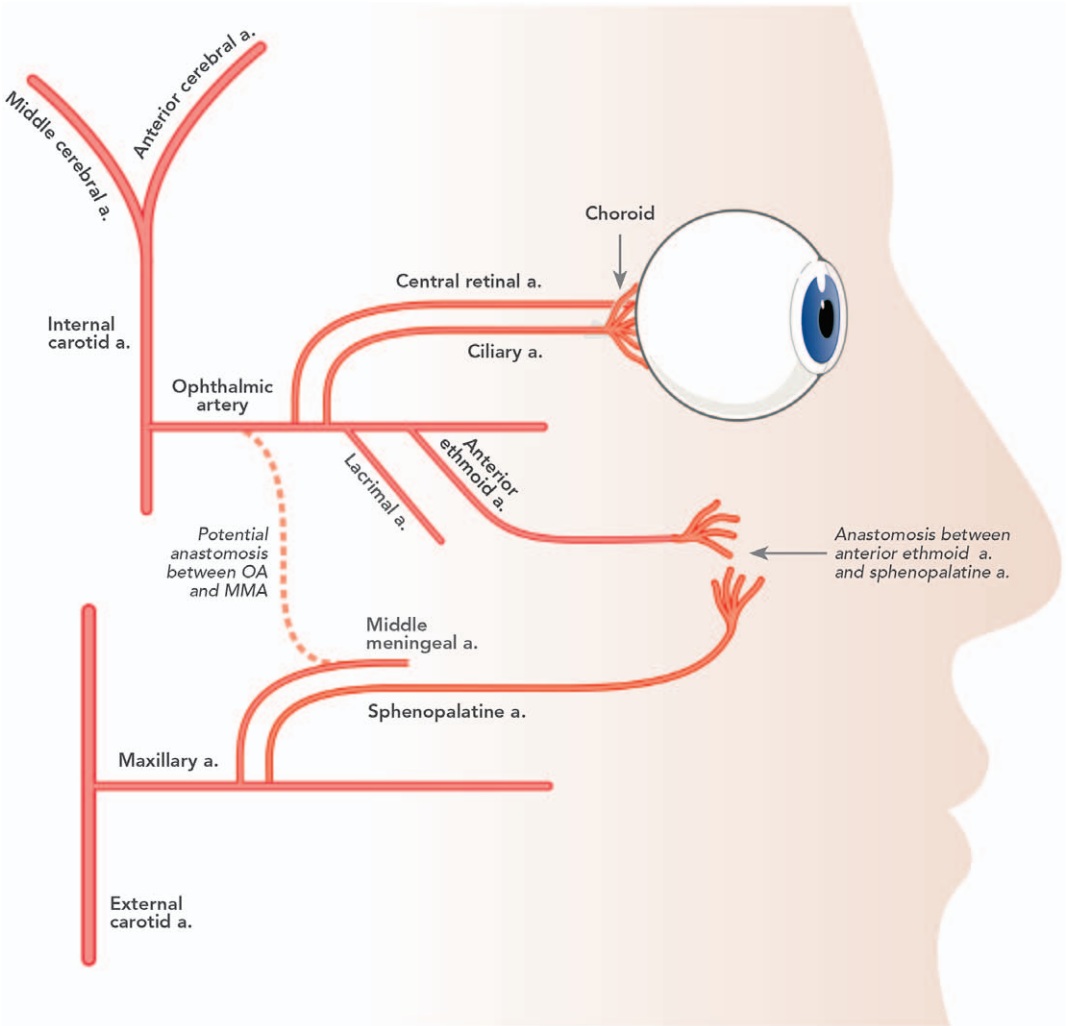

Fig. 1. Relevant ophthalmic artery (OA) anatomy in schematic form. Drug injected into the ophthalmic artery can reach the external carotid circulation in various ways, including *via* anastomosis in the nose and occasionally *via* an anomalous connection to the middle meningeal artery (MMA).

Copyright © 2016, the American Society of Anesthesiologists, Inc. Wolters Kluwer Health, Inc. Unauthorized reproduction of this article is prohibited.

Downloaded from http://asa2.silverchair.com/anesthesiology/article-pdf/126/1/165/375009/20170100_0-00030.pdf by guest on 16 April 2024

intraoperative complications (see Discussion of Complications, paragraph 2).[1] Dexamethasone is used to prevent periorbital edema if more than two chemotherapy drugs are to be administered.[1] A syringe of epinephrine is always prepared.

The femoral artery is cannulated with a 3-French sheath, and intravenous heparin is given. A microcatheter is advanced into the orifice of the OA.[5] After confirmation of correct catheter position, between 1 and 3 chemotherapeutic agents are infused slowly (fig. 2). Typically, melphalan, topotecan, and carboplatin are injected sequentially over 20 to 30 min.[5] A postinjection cerebral angiogram is performed. Once the activated clotting time is conducive to hemostasis, the femoral catheter is removed and groin pressure is maintained for 15 to 20 min.[5]

The patient is then awakened and extubated in a manner that will minimize coughing. If the child is at least 1 yr old, a deep extubation is performed. If the child is an infant, intravenous fentanyl is given throughout the case to facilitate a smooth emergence. An antiemetic is always given. The patient is brought to the recovery area where he/she must remain flat for 5 h to prevent rebleeding from the puncture site. Dexmedetomidine is given during emergence to facilitate bed rest.

Neuroradiologic Complications of OA Chemosurgery

Drugs injected into the OA may bypass the central retinal artery (and the target tumor) by draining into the ECA *via* the anastomosis between the anterior ethmoid artery and the sphenopalatine artery in the nares.[10] This will reduce the net drug delivery into the tumor. Spraying a topical vasoconstrictor (oxymetazoline or phenylephrine) into the ipsilateral nares can reduce this problem.[5,10] Occasionally, the OA cannot be cannulated *via* the ICA. This may be due to the previous injury to the OA ostia, small size (especially if the age is less than 3 months), or anatomic variation.[2] In this situation, it may be possible to access the OA from the ECA *via* the MMA.[7] If this too is not feasible, then balloon-assisted SOAI can be utilized.[7] Spasm of the OA can be treated with intraarterial verapamil.[10] This has not been found to cause clinically significant hypotension.[10] Postoperatively, orbital edema, retinal ischemia, retinopathy, femoral artery occlusion, and neutropenia have all been observed.[5]

Preanesthesia Considerations

The patient with retinoblastoma will typically undergo three to four rounds of OA chemosurgery.[5] Reviewing previous anesthetic records can be helpful in revealing past adverse reactions. Previous intravenous chemotherapy, if administered through peripheral veins, may have caused difficult intravenous access. Systemic chemotherapy can also cause neutropenia.[4] OA chemosurgery is deferred until cell counts have recovered. Older children may benefit from premedication.

Respiratory Complications during OA Chemosurgery

A patient undergoing OA chemosurgery may experience a sudden, profound decrease in lung compliance when the microcatheter is in the ICA or OA. This occurs in 29% of cases[1] and occurs even when the patient is deeply anesthetized and paralyzed. This event can occur before anything has been injected, including saline, contrast, or chemotherapeutic agent.[1,3] The tidal volume may drop precipitously within seconds, and desaturation is not uncommon. The onset is abrupt and always temporally related to initial positioning of the catheter in the ICA or OA.[3] Ventilation with higher airway pressures and 100% oxygen may be required. When this happens, the neuroradiologist is notified, and catheter manipulations are paused until the problem has been resolved.[1,5] Pressure-control ventilation is very useful in these cases because it allows early detection of an impending respiratory event from a small decrease in exhaled tidal volume (as little as 10 ml). In addition, using pressure-control ventilation will prevent a steep rise in intrathoracic pressure that might cause hemodynamic instability by limiting venous return to the heart. This occurrence is not restricted to our institution alone but has been reported in multiple centers doing chemosurgery.[3,5,11] It was initially suspected that this acute lung compliance change only occurred during the second or third chemosurgery procedure.[1,3,5,11] However, it has been observed to

Table 1. List of Medications Used for Ophthalmic Artery Chemosurgery

Medication	Comment
Sevoflurane	At least 1 minimum alveolar concentration throughout case
Rocuronium 0.6 mg/kg	Given at induction, not redosed
Oxygen	100% given from skin puncture to the first chemotherapy injection
Dexamethasone 0.5 mg/kg	Given if more than two chemotherapy drugs used
Oxymetazoline 0.05% one spray	Given after intubation to nares ipsilateral to tumor with bottle held upright
Heparin 80 U/kg	Given after femoral catheter placed
Epinephrine 0.5–1 μg/kg	Given as needed for decreased lung compliance
Ondansetron 0.1 mg/kg	Given to all patients regardless of age
Dexmedetomidine 0.5–1 μg/kg	Given after femoral catheter removed
Neostigmine 0.05 mg/kg, glycopyrrolate 0.01 mg/kg for reversal	Dose of glycopyrrolate may need to be increased if using dexmedetomidine

Downloaded from http://asa2.silverchair.com/anesthesiology/article-pdf/126/1/165/375009/20170100_0-00030.pdf by guest on 16 April 2024

Copyright © 2016, the American Society of Anesthesiologists, Inc. Wolters Kluwer Health, Inc. Unauthorized reproduction of this article is prohibited.

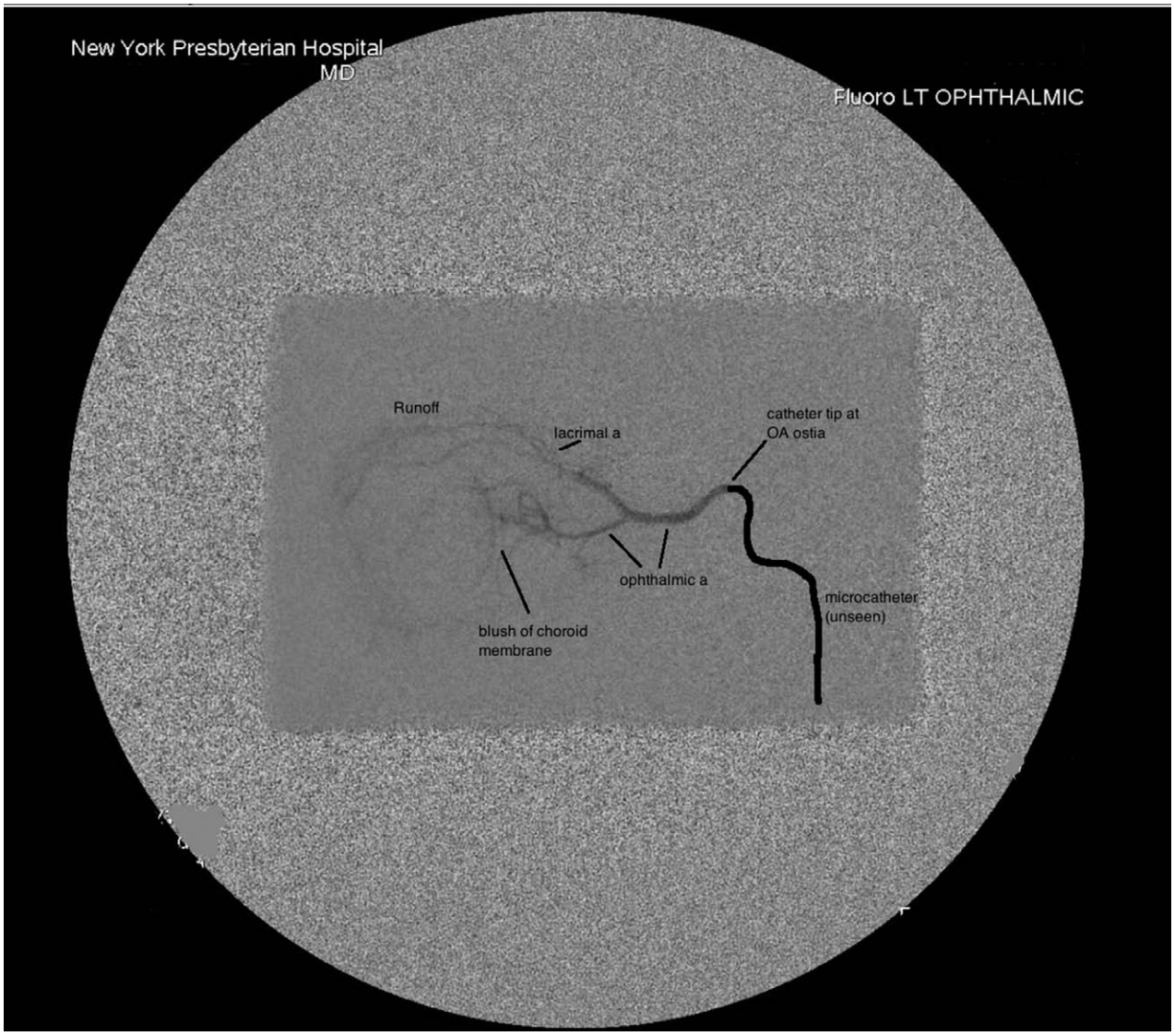

Fig. 2. The injection process. The microcatheter has been drawn in for clarity. The microcatheter is in the internal carotid artery (ICA) with its tip at the ostia of the ophthalmic artery (OA), and contrast has been injected. There is no reflux of contrast into the ICA from the OA. The central retinal artery cannot actually be seen during injection because of its small size. There is a characteristic "blush" of contrast seen in the choroid delivered *via* the ciliary artery; this indicates proper catheter position in the OA ostia. There is no excessive contrast runoff past the retina, which would indicate a need to increase the chemotherapy drug dose.

occur during the first procedure as well, albeit with a lower frequency (18% *vs.* 32%).[1]

Epinephrine is highly effective in combating this compliance change, especially when given at the onset.[1,5] Intermittent boluses of 0.5 to 1 μg/kg are more effective than lower doses.

Once resolved, the respiratory event generally does not recur during the same procedure, even if the catheter is repositioned into the contralateral OA.[12] The capnogram may show a mild drop in end-tidal exhaled carbon dioxide in parallel with decreased tidal volume but rarely shows a characteristic obstructive pattern (fig. 3, A and B). Wheezing is generally not heard.[3] It is not reliably prevented with steroids or albuterol.[1] This respiratory event occurs in otherwise healthy children with no previous history of reactive airway disease or recent upper respiratory illness. Pink frothy sputum has not been reported in the literature nor ever seen at our institution. Postoperatively, there are generally no respiratory issues in the recovery area.[1] The proposed pathophysiology of this respiratory complication will be discussed further (see Discussion of Complications, paragraph 1).

Cardiovascular Complications

Hemodynamic instability can also occur during OA chemosurgery, with both bradycardia and hypotension seen.[3,5,12] Bradycardia can occur despite pretreatment with intravenous atropine.[3] Hypokinesis of the heart has been observed during thoracic fluoroscopy.[3] Hypotension can be prolonged (13 to 37 min)[12] and severe (as much as a 40-mmHg decrease in systolic blood

Copyright © 2016, the American Society of Anesthesiologists, Inc. Wolters Kluwer Health, Inc. Unauthorized reproduction of this article is prohibited.

Downloaded from http://asa2.silverchair.com/anesthesiology/article-pdf/126/1/165/375009/20170100_0-00030.pdf by guest on 16 April 2024

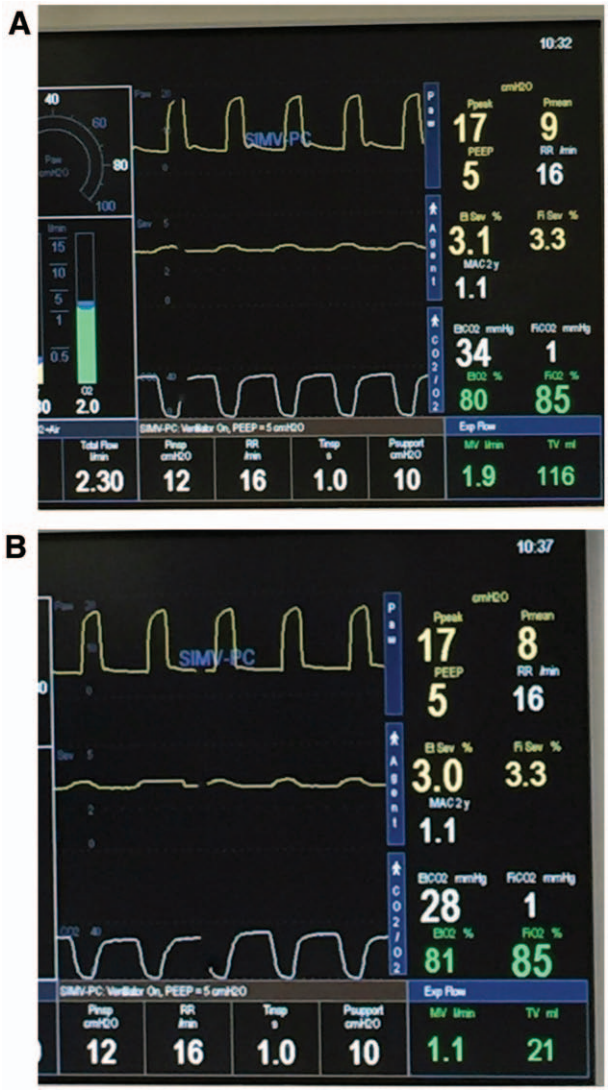

Fig. 3. (*A*) The ventilator status immediately before microcatheter advancement into the ophthalmic artery. (*B*) Figure, taken 1 min later during catheter manipulation, shows a dramatic decrease in tidal volume to 21 ml. The contour of the capnograph is unchanged despite sharply reduced lung compliance. F_{IO_2} = fractional inspired oxygen tension; PEEP = positive end-expiratory pressure; RR = respiratory rate; TV = tidal volume.

pressure), especially if not treated with epinephrine.[3] Bradycardia is less frequently reported and does not always occur.[12] There are no reported cases of sustained bradycardia requiring temporary pacing; pacemaker pads are not prophylactically placed at our institution. Hemodynamic instability, when it occurs, often happens after the onset of respiratory changes[3] but may not be seen if the patient has received intravenous epinephrine. At our institution, epinephrine is used as a first-line treatment for both respiratory and hemodynamic instability during these procedures. The proposed cause of this hemodynamic instability will be discussed later (see Discussion of Complications, paragraph 4).

Balloon-assisted SOAI frequently causes transient bradycardia when melphalan is injected. Suzuki *et al.*[8] reported profound bradycardia (heart rate less than 60), occurring 6.9% of the time.[8] Yamane *et al.*[9] reported a 100% occurrence of bradycardia during injection of both melphalan and contrast. Interestingly, Suzuki *et al.*[8] experienced a much lower incidence of adverse respiratory events with SOAI compared to OA chemosurgery, occurring in only 1 of 343 patients.[8]

Other Complications

Temporary cerebral vasospasm has been reportedly caused by an overdose of topical vasoconstrictor in a toddler.[13] The patient had received both phenylephrine eye drops and intranasal oxymetazoline. The patient developed prolonged severe systemic hypertension. Cerebral angiography showed multiple areas of spasm in the middle cerebral and anterior cerebral arteries. A follow-up angiogram taken after the blood pressure had normalized showed resolution of the vasospasm.[13] It is also possible that some component of the vasospasm was caused by either the catheter or the chemotherapy agent. Postoperative nausea and vomiting are very common after this procedure,[8] and prophylactic antiemetics are indicated for all ages.

Discussion of Complications

There are many unanswered questions regarding the cardiopulmonary instability seen with OA chemosurgery. The severely decreased lung compliance that occurs appears to be an atypical form of bronchospasm. This is supported by the rapid onset and recovery and excellent response to epinephrine. Not consistent with bronchospasm is the absence of audible wheezing and normally shaped capnogram. Lack of wheezing may reflect very poor air entry, but the completely normal capnogram is difficult to explain. Other potential causes of the acutely decreased lung compliance during these cases are chest wall rigidity and altered alveolar fluid content, *e.g.*, pulmonary edema. Chest wall rigidity is less likely due to the routine use of neuromuscular blockade in these cases. At our institution, we have observed the respiratory event despite maximal muscle relaxation. Also, intravenous epinephrine would not be expected to relieve chest wall rigidity. Acute pulmonary edema could cause decreased lung compliance and is consistent with the observed cardiac hypokinesis seen on chest fluoroscopy. Arguing against this is the lack of pink frothy sputum, rapid resolution of signs with epinephrine, and completely normal subsequent respiratory status.

Anaphylactoid reaction may be suggested by the combination of decreased lung compliance and hypotension, but this is unlikely for several reasons. Pretreatment with antihistamines and steroids has not prevented these adverse events, and the tryptase level, when sent, is usually negative.[3] The hypotension would be expected to occur simultaneously with bronchoconstriction, and in fact, it usually follows several minutes later. Finally, cutaneous erythema or urticaria is extremely uncommon. That said, occasionally, there have been cases of prolonged refractory hypotension associated with a positive tryptase level,[3] and a contrast allergy has been confirmed rarely.[5]

Copyright © 2016, the American Society of Anesthesiologists, Inc. Wolters Kluwer Health, Inc. Unauthorized reproduction of this article is prohibited.

Downloaded from http://asa2.silverchair.com/anesthesiology/article-pdf/126/1/165/375009/20170100_0-00030.pdf by guest on 16 April 2024

If the decreased lung compliance is treated by increasing the inspiratory pressure, then decreased venous return may be contributing to the observed hypotension. However, the severity of hypotension peaks as compliance improves, which makes this unlikely to be the main cause.

The fixed temporal relationship between the cardiopulmonary changes and the onset of catheter manipulation within the ICA and OA, abrupt onset of signs, and rapid resolution all suggest a neural reflex mechanism not yet fully described. While the precise mechanism is unclear, it may be related to one or more of the following reflexes.

The oculocardiac reflex, triggered by traction on the eye, causes bradycardia. The afferent limb is the ophthalmic branch of the trigeminal nerve (V1), and the efferent is the vagus nerve.[3] A case report shows asystole triggered three consecutive times in an adult undergoing catheterization of the distal OA for attempted embolization of an arteriovenous fistula supplied by the ethmoid artery. No bronchospasm, however, was reported in this case.[14]

Less well known is the oculorespiratory reflex (ORR). This is bradypnea or apnea triggered by ocular traction. It is seen during strabismus surgery in spontaneously breathing patients.[15,16] Unlike the oculocardiac reflex, the ORR is not clearly mediated by vagus nerve. Khurana *et al.*[17] triggered ORR in five of five rabbits with eye traction despite bilateral vagotomy.

The diving reflex is a reflex found in most mammals, which is triggered by immersion of the face in cold water resulting in bradycardia, apnea, and peripheral vasoconstriction.[18,19] The bradycardia occurs with immersion alone, but it is significantly enhanced by simultaneous apnea.[19] This reflex is mediated by the ophthalmic branch of the trigeminal nerve *via* the anterior ethmoid nerve (AEN).[20] Direct stimulation of the AEN in muskrats causes bradycardia, hypotension, and apnea.[20] Cutting the AEN abolishes the apnea triggered by nasal stimulation.[20] Anesthetized, spontaneously breathing dogs given intranasal capsaicin experience a decrease in dynamic lung compliance from 25.5 to 13.7 ml/cm H_2O. These same dogs also experienced a reduction in heart rate.[21]

Bronchospasm can occur when the face is cooled, as might be seen with cold-water immersion. Ice packs on the face (but not the chest or thighs) cause a significant decrease in specific airway conductance.[22] In awake volunteers spontaneously breathing *via* a snorkel, forced expiratory flow is decreased when immersed in cold water.[23] This bronchoconstriction is enhanced by apnea immediately before spirometry. The component of forced expiratory flow reduction attributed to facial cooling is *blocked by inhaled ipratropium*.[23]

What can we conclude from these different studies? Trigeminal stimulation can cause apnea, bradycardia, and bronchoconstriction.[14–18,22,23] Catheter manipulation of the ICA or OA may be stimulating trigeminal afferents in the blood vessel and causing a diving reflex-type response in the pulmonary and cardiovascular systems mediated at least in part by the vagus nerve (fig. 4).

Future Research

Many questions need to be addressed regarding the unusual cardiopulmonary events that occur during OA chemosurgery. Are the incidence and severity of the response related to the underlying balance of parasympathetic and sympathetic tone? If so, can analysis of heart rate beat-to-beat variability predict who is at higher risk? How is heart function affected? Is epinephrine the best available treatment? Is there a role for prophylactic infusion of epinephrine during these procedures? Use of epinephrine can be associated with hypertension. If the reactions are cholinergically mediated, can these reactions be prevented by inhaled ipratropium?

Conclusions

OA chemosurgery for retinoblastoma is rapidly gaining acceptance as an effective treatment modality with limited long-term morbidity. However, the procedure entails potentially dramatic acute respiratory and hemodynamic changes. The anesthesiologist must be vigilant against a severe decrease in lung compliance during the initial part of the procedure (until drug administration begins) and should deliver a high fractional inspired oxygen tension at this time. Any decrease in tidal volumes should be treated immediately by temporarily halting catheter manipulations and increasing airway pressure. If these conservative maneuvers are inadequate, early use of intravenous epinephrine (0.5 to 1 μg/kg) is rapidly effective and appears to prevent subsequent hemodynamic deterioration. Inhaled anticholinergic drugs may play a prophylactic role; this remains unclear. An intraoperative event does not necessarily require hospital admission, but sustained refractory hypotension may be a sign of an anaphylactoid reaction and should be treated accordingly. Transient bradycardia associated with balloon-assisted SOAI injection of melphalan should be expected. Postoperative nausea and vomiting can be severe, and antiemetic prophylaxis is strongly advised.

Research Support

Salary support was received from the Department of Anesthesiology and Department of Neuroradiology, Weill Cornell Medicine, New York, New York.

Competing Interests

The authors declare no competing interests.

Correspondence

Address correspondence to Dr. Scharoun: Department of Anesthesiology, New York Presbyterian Hospital, Weill Cornell Medicine, New York, 525 E 68 St (P-305), New York, New York 10065. jhs2001@med.cornell.edu. Information on purchasing reprints may be found at www.anesthesiology.org or on the masthead page at the beginning of this issue. ANESTHESIOLOGY's articles are made freely accessible to all readers, for personal use only, 6 months from the cover date of the issue.

Downloaded from http://asa2.silverchair.com/anesthesiology/article-pdf/126/1/165/375009/20170100_0-00030.pdf by guest on 16 April 2024

Copyright © 2016, the American Society of Anesthesiologists, Inc. Wolters Kluwer Health, Inc. Unauthorized reproduction of this article is prohibited.

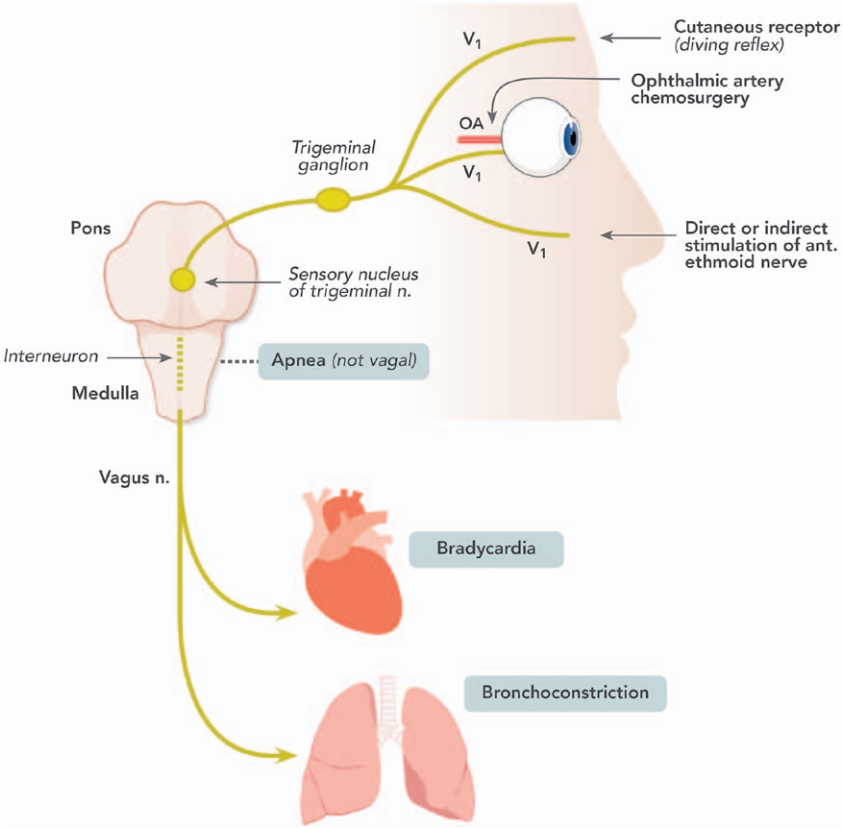

Fig. 4. Purported mechanism of cardiopulmonary changes seen in ophthalmic artery (OA) chemosurgery. Cutaneous cooling, catheter manipulation within the OA, and nasal irritation all similarly result in afferent signals *via* the trigeminal ganglion to the pons, which eventually leads to vagal activation.[19–23] In the case of intraarterial chemotherapy for retinoblastoma, this results in bronchoconstriction, bradycardia, and hypotension. The mechanism by which the ophthalmic branch of trigeminal nerve (V1) stimulation can cause apnea is not vagally mediated.[17]

References

1. Kato MA, Green N, O'Connell K, Till SD, Kramer DJ, Al-Khelaifi M, Han JH, Pryor KO, Gobin YP, Proekt A: A retrospective analysis of severe intraoperative respiratory compliance changes during ophthalmic arterial chemosurgery for retinoblastoma. Paediatr Anaesth 2015; 25:595–602
2. Abramson DH: Retinoblastoma: Saving life with vision. Annu Rev Med 2014; 65:171–84
3. Phillips TJ, McGuirk SP, Chahal HK, Kingston J, Robertson F, Brew S, Roebuck D, Hungerford JL, Herod J: Autonomic cardio-respiratory reflex reactions and superselective ophthalmic arterial chemotherapy for retinoblastoma. Paediatr Anaesth 2013; 23:940–5
4. Shields CL, Kaliki S, Rojanaporn D, Al-Dahmash S, Bianciotto CG, Shields JA: Intravenous and intra-arterial chemotherapy for retinoblastoma: What have we learned? Curr Opin Ophthalmol 2012; 23:202–9
5. Gobin YP, Dunkel IJ, Marr BP, Brodie SE, Abramson DH: Intra-arterial chemotherapy for the management of retinoblastoma: Four-year experience. Arch Ophthalmol 2011; 129:732–7
6. Michalinos A, Zogana S, Kotsiomitis E, Mazarakis A, Troupis T: Anatomy of the ophthalmic artery: A review concerning its modern surgical and clinical applications. Anat Res Int 2015; 2015:591961
7. Klufas MA, Gobin YP, Marr B, Brodie SE, Dunkel IJ, Abramson DH: Intra-arterial chemotherapy as a treatment for intraocular retinoblastoma: Alternatives to direct ophthalmic artery catheterization. AJNR Am J Neuroradiol 2012; 33:1608–14
8. Suzuki S, Yamane T, Mohri M, Kaneko A: Selective ophthalmic arterial injection therapy for intraocular retinoblastoma: The long-term prognosis. Ophthalmology 2011; 118:2081–7
9. Yamane T, Kaneko A, Mohri M: The technique of ophthalmic arterial infusion therapy for patients with intraocular retinoblastoma. Int J Clin Oncol 2004; 9:69–73
10. Abruzzo TA, Geller JI, Kimbrough DA, Michaels S, Corrêa ZM, Cornell K, Augsburger JJ: Adjunctive techniques for optimization of ocular hemodynamics in children undergoing ophthalmic artery infusion chemotherapy. J Neurointerv Surg 2015; 7:770–6
11. Muen WJ, Kingston JE, Robertson F, Brew S, Sagoo MS, Reddy MA: Efficacy and complications of super-selective intra-ophthalmic artery melphalan for the treatment of refractory retinoblastoma. Ophthalmology 2012; 119:611–6
12. Klumpp S, Jorge LM, Aziz-Sultan MA: Hemodynamic instability induced by superselective angiography of the ophthalmic artery. Case Rep Anesthesiol 2013; 2013:408670
13. Abruzzo T, Patino M, Leach J, Rahme R, Geller J: Cerebral vasoconstriction triggered by sympathomimetic drugs during intraarterial chemotherapy. Pediatr Neurol 2013; 48:139–42
14. Sakamoto M, Watanabe T, Uno T, Inagaki H: Oculocardiac reflex induced by catheterization of the distal ophthalmic artery: Case report. J Neuroendovasc Ther 2008; 2:34–7
15. Blanc VF, Jacob JL, Milot J, Cyrenne L: The oculorespiratory reflex revisited. Can J Anaesth 1988; 35:468–72
16. Allison CE, De Lange JJ, Koole FD, Zuurmond WW, Ros HH, van Schagen NT: A comparison of the incidence of the

Copyright © 2016, the American Society of Anesthesiologists, Inc. Wolters Kluwer Health, Inc. Unauthorized reproduction of this article is prohibited.

Downloaded from http://asa2.silverchair.com/anesthesiology/article-pdf/126/1/165/375009/20170100_0-00030.pdf by guest on 16 April 2024

oculocardiac and oculorespiratory reflexes during sevoflurane or halothane anesthesia for strabismus surgery in children. Anesth Analg 2000; 90:306–10

17. Khurana AK, Khurana I, Yadav RN, Singh PI, Gombar KK, Ahluwalia BK: An experimental model of oculorespiratory reflex. Br J Ophthalmol 1992; 76:76–8
18. Panneton WM: The mammalian diving response: An enigmatic reflex to preserve life? Physiology (Bethesda) 2013; 28:284–97
19. Alboni P, Alboni M, Gianfranchi L: Diving bradycardia: A mechanism of defence against hypoxic damage. J Cardiovasc Med (Hagerstown) 2011; 12:422–7
20. McCulloch PF, Faber KM, Panneton WM: Electrical stimulation of the anterior ethmoidal nerve produces the diving response. Brain Res 1999; 830:24–31
21. Kanamaru A, Mutoh T, Nishimura R, Sasaki N, Kuwahara M, Tsubone H: Respiratory and cardiovascular reflexes elicited by nasal instillation of capsaicin to anesthetized, spontaneously breathing dogs. J Vet Med Sci 2001; 63:439–43
22. Berk JL, Lenner KA, McFadden ER Jr: Cold-induced bronchoconstriction: Role of cutaneous reflexes vs. direct airway effects. J Appl Physiol (1985) 1987; 63:659–64
23. Mukhtar MR, Patrick JM: Bronchoconstriction: A component of the 'diving response' in man. Eur J Appl Physiol Occup Physiol 1984; 53:155–8

ANESTHESIOLOGY REFLECTIONS FROM THE WOOD LIBRARY-MUSEUM

Byzantine Ivory Scene of the Biblical Sleep of Adam and the Creation of Eve

In Cleveland, Ohio, just a few miles from where Charles K. Teter, D.D.S., founded the United States' second major anesthesia machine manufacturing company, stands the celebrated Cleveland Museum of Art. Housed in that museum is a wood-and-ivory box from Byzantium (later Constantinople, then Istanbul) dating back to ca.1050 CE. One of the carved-ivory scenes (*above*) on the lid of the box depicts the biblical account from the book of *Genesis* of the creation of Eve after a "deep sleep" falls upon Adam. The Byzantine lettering can be transliterated to ADAM HYPNOSAS EVA EXELTHEN EK TIS PLEURA AUTOU and can be translated to "Here Eve came from out of a flank of sleeping Adam." Generations of scholars have suggested that the *Genesis* account of Adam's heavy slumber strongly resembles the "modern" state of general anesthesia. (Copyright © the American Society of Anesthesiologists' Wood Library-Museum of Anesthesiology.)

George S. Bause, M.D., M.P.H., Honorary Curator and Laureate of the History of Anesthesia, Wood Library-Museum of Anesthesiology, Schaumburg, Illinois, and Clinical Associate Professor, Case Western Reserve University, Cleveland, Ohio. UJYC@aol.com.

Downloaded from http://asa2.silverchair.com/anesthesiology/article-pdf/126/1/165/375009/20170100_0-00030.pdf by guest on 16 April 2024

Copyright © 2016, the American Society of Anesthesiologists, Inc. Wolters Kluwer Health, Inc. Unauthorized reproduction of this article is prohibited.