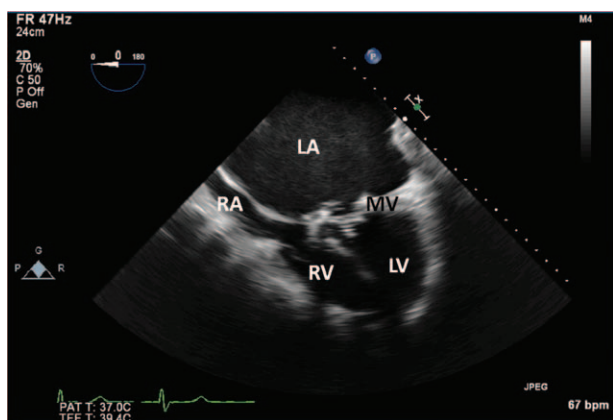


Echocardiographic Features that May Predict Acute Left Ventricular Failure after Mitral Valve Replacement in Patients with Severe Mitral Stenosis

Michael K. Essandoh, M.D.



STENOSIS of the mitral valve (MV) causes physiologic and structural changes to the cardiac chambers with the progression of time.^{1–3} These variations can be identified by echocardiography and may impact patient care during MV replacement (fig.).³ The accompanying figure is a transesophageal echocardiographic midesophageal four-chamber view of a patient with chronic severe prosthetic mitral stenosis. Structurally, there is a severe left atrial (LA) enlargement (LA dimension of 12.5 cm; normal less than or equal to 4 cm) and severe left ventricular (LV) atrophy, which stems from chronic obstruction of LA emptying. The giant LA may also cause compression of the other cardiac structures, such as the right atrium (RA) and the right ventricle (RV). Furthermore, an atrophied LV will develop systolic and diastolic dysfunction over time.¹

The structural changes associated with chronic mitral stenosis described above may have an impact on a patient's hemodynamics when weaning from cardiopulmonary bypass after MV replacement. In this setting, an atrophied LV is not accustomed to a higher preload as a result of relieving the mechanical obstruction. This increase in LV wall tension may induce systolic failure in the immediate postcardiopulmonary bypass period and potentially cause cardiovascular collapse. Thus, inotropic support may be required to maintain hemodynamic stability and should be readily available. Anesthesiologists should be aware of this phenomenon and plan appropriately.

Competing Interests

The author declares no competing interests.

Correspondence

Address correspondence to Dr. Essandoh: michael.essandoh@osumc.edu

References

1. Feigenbaum H, Campbell RW, Wunsch CM, Steinmetz EF: Evaluation of the left ventricle in patients with mitral stenosis. *Circulation* 1966; 34:462–72
2. Meyer M: Left ventricular atrophy in pulmonary arterial hypertension: A sinister dexter conundrum. *J Am Coll Cardiol* 2014; 64:38–40
3. Baumgartner H, Hung J, Bermejo J, Chambers JB, Evangelista A, Griffin BP, Iung B, Otto CM, Pellikka PA, Quiñones M; American Society of Echocardiography; European Association of Echocardiography: Echocardiographic assessment of valve stenosis: EAE/ASE recommendations for clinical practice. *J Am Soc Echocardiogr* 2009; 22:1–23; quiz 101–102

From the Department of Anesthesiology, Division of Cardiothoracic and Vascular Anesthesiology, The Ohio State University, Wexner Medical Center, Columbus, Ohio.

Copyright © 2016, the American Society of Anesthesiologists, Inc. Wolters Kluwer Health, Inc. All Rights Reserved. *Anesthesiology* 2016; 125:808