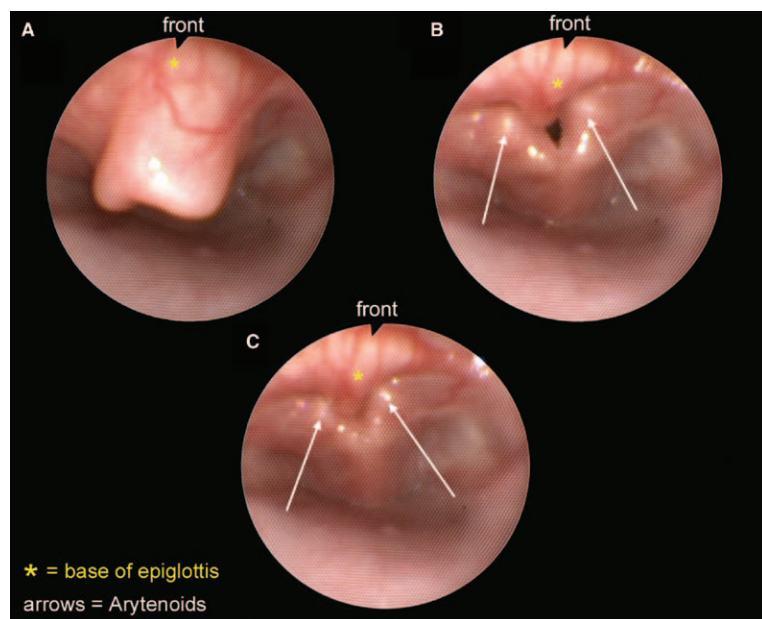


# Laryngomalacia with Epiglottic Prolapse Obscuring the Laryngeal Inlet

Michael Laschat, M.D., Jost Kaufmann, M.D., Frank Wappler, Ph.D.



**A**N 8-week-old girl with congenital inspiratory stridor was listed for diagnostic laryngotracheoscopy. Flexible laryngoscopy was performed with intravenous propofol and sufentanil sedation. Spontaneous ventilation was assisted *via* face mask. Laryngomalacia with a retroflexed epiglottis (fig. A), epiglottic prolapse (fig. B), and a completely obstructed larynx in full inspiration (fig. C) was seen (see Supplemental Digital Content 1, <http://links.lww.com/ALN/B253>, which is the video from which the figure was taken).

Laryngomalacia is defined as the collapse of supraglottic structures during inspiration with resulting upper airway obstruction.<sup>1</sup> It is the most common cause of stridor in neonates and children. Most cases of laryngomalacia are self-limiting, rarely persist after 24 months, and do not require therapeutic intervention. Only a small number of chil-

dren with severe symptomatic disease, *e.g.*, hypoxemia, apnea, or failure to thrive, require surgical treatment.<sup>2</sup>

Definitive diagnosis of laryngomalacia can be confirmed with flexible fiberoptic laryngoscopy. Obstruction may result from collapse of redundant arytenoid mucosa, shortened aryepiglottic folds, a retroflexed floppy epiglottis, or a combined collapse.<sup>2</sup>

Airway management includes chin lift, jaw thrust, and continuous positive airway pressure, but difficulties with forced mask ventilation<sup>1</sup> are reported due to a worsening obstruction with increased pharyngeal pressures. Therefore, gentle mask ventilation avoiding high inspiratory pressure is advisable. An oropharyngeal airway may further displace the prolapsing epiglottis and is not recommended.<sup>1</sup> Intubation may be extremely difficult as the epiglottis might be pushed against the glottis with the tip of the laryngoscope obscuring almost completely the larynx.<sup>3</sup> The use of a rigid bronchoscope in these cases should be considered.<sup>3</sup>

## Competing Interests

The authors declare no competing interests.

## Correspondence

Address correspondence to Dr. Laschat: [laschatm@kliniken-koeln.de](mailto:laschatm@kliniken-koeln.de)

## References

1. De Beer D, Chambers N: Double trouble: Prolapsing epiglottis and unexpected dual pathology in an infant. *Paediatr Anaesth* 2003; 13:448–52
2. Thorne MC, Garetz SL: Laryngomalacia: Review and summary of current clinical practice in 2015. *Paediatr Respir Rev* 2015; pii:S1526-0542(15)00009-3
3. Vaz FM, Neumann AM, Albert D: Severe epiglottic prolapse and the obscured larynx at intubation. *Paediatr Anaesth* 2002; 12:537–40

Supplemental Digital Content is available for this article. Direct URL citations appear in the printed text and are available in both the HTML and PDF versions of this article. Links to the digital files are provided in the HTML text of this article on the Journal's Web site ([www.anesthesiology.org](http://www.anesthesiology.org)).

From the Department of Pediatric Anesthesiology, Children's Hospital of Cologne, Clinics of Cologne, University Witten/Herdecke, Cologne, Germany.

Copyright © 2016, the American Society of Anesthesiologists, Inc. Wolters Kluwer Health, Inc. All Rights Reserved. *Anesthesiology* 2016; 125:398