

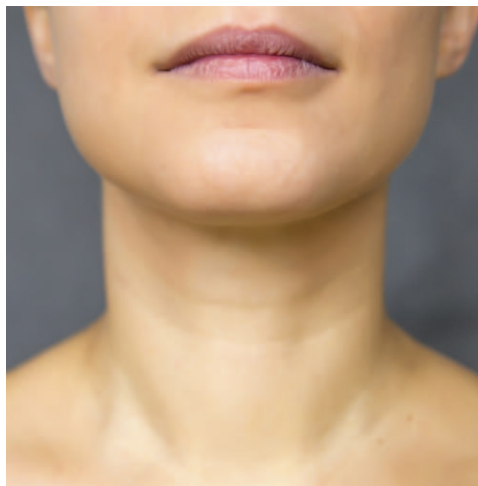# Surgical Cricothyrotomy, Rather than Percutaneous Cricothyrotomy, in “Cannot Intubate, Cannot Oxygenate” Situation

Takashi Asai, M.D., Ph.D.

**C**RICOTHYROTOMY (except for surgical tracheostomy) is regarded as the last resort in a situation of “cannot intubate, cannot oxygenate” after induction of general anesthesia,<sup>1–3</sup> and thus, we should always be prepared to perform this task reliably in such a dire situation. Cricothyrotomy can be performed either surgically or percutaneously, and percutaneous cricothyrotomy can be performed either by the utilization of an intravenous cannula or by the use of a cricothyrotomy kit (a guidewire Seldinger type or a Trocar type). One major problem with emergency cricothyrotomy is that, because it is difficult to carry out randomized controlled studies in patients, we still do not know which method is the most reliable.<sup>4</sup> Another problem is that, because the incidence of “cannot intubate, cannot oxygenate” situation is low, we generally would not have expertise in performing this task. In this issue of *ANESTHESIOLOGY*, Heymans *et al.*<sup>5</sup> have reported that the success rate of percutaneous cricothyrotomy was much lower than that for surgical cricothyrotomy when performed by medical students.<sup>5</sup>

## Key Findings

In the study by Heymans *et al.*,<sup>5</sup> 20 students with no experience in cricothyrotomy received a 2-h training and performed cricothyrotomy by 3 methods (surgical, percutaneously with Seldinger method [Melker, USA], or with Trocar method [QuickTrach II, Germany]), in a random crossover order, in 60 cadavers. The success rate of cricothyrotomy (within 3 min) was much greater (95%) for surgical cricothyrotomy than that for percutaneous cricothyrotomy (50% for the Seldinger method and 55% for the Trocar method). The main reason for the failure was incorrect placement of a



*“...how can we become able to decide upon and carry out rescue airway management swiftly and reliably...?”*

tube, and the insertion time took longer for the Seldinger method.

## Which Method to Use?

So, what can we learn from Heymans *et al.*'s<sup>5</sup> study (in addition to previous studies), and which method of emergency cricothyrotomy should we use? First, there is growing evidence that percutaneous cricothyrotomy using a narrow-bore cannula—once advocated for use for its simplicity—may frequently be ineffective.<sup>6</sup> In addition, oxygenation through a narrow-bore cannula may be achieved only by high-pressure ventilation (such as jet ventilation), which may cause other life-threatening complications, such as tension pneumothorax and pneumomediastinum.

Regarding the use of a percutaneous cricothyrotomy kit, Heymans *et al.*<sup>5</sup> and others have shown that a Trocar method takes shorter time than a Seldinger method, and thus, the use of a Trocar-type percutaneous cricothyrotomy kit is theoretically more suitable when the patient is being hypoxic in a “cannot intubate, cannot oxygenate” situation. Nevertheless, Heymans *et al.*<sup>5</sup> have also shown that even a Trocar-type percutaneous cricothyrotomy is less effective than surgical cricothyrotomy in establishing a clear airway. In addition, emergency Trocar-type cricothyrotomy may frequently produce another life-threatening complication (posterior tracheal wall tear, which may lead to tension pneumothorax, pneumomediastinum, and mediastinitis).<sup>7</sup>

Would percutaneous cricothyrotomy be truly less effective than surgical cricothyrotomy? A clear answer cannot be obtained due to the lack of randomized controlled studies, but cohort studies indicate that it is likely to be so. For example, a recent nationwide prospective survey (the fourth National Audit Project) in the United Kingdom has

Image: Thinkstock.

Corresponding article on page 295.

Accepted for publication April 27, 2016. From the Department of Anesthesiology, Dokkyo Medical University Koshigaya Hospital, Minamikoshigaya, Koshigaya City, Saitama, Japan.

Copyright © 2016, the American Society of Anesthesiologists, Inc. Wolters Kluwer Health, Inc. All Rights Reserved. *Anesthesiology* 2016; 125:269-71

shown that, during 1-yr period, emergency cricothyrotomy or tracheostomy was required in 58 patients undergoing anesthesia. Oxygenation could not be achieved in 12 of the 19 patients (63%) in whom a narrow-bore needle was used and in 3 of the 7 patients (43%) with a wide-bore needle. In contrast, oxygenation could not be achieved in only 7 of 58 patients (12%) in whom surgical cricothyrotomy or tracheostomy was performed.

In this issue of *ANESTHESIOLOGY*, Heymans *et al.*<sup>5</sup> have found that percutaneous cricothyrotomy may fail mainly because it was impossible to place a tube into the infraglottic airway. A previous study also has shown that the procedure is more likely to fail when the tissues overlying the larynx are thick and it is difficult to locate the cricothyroid ligament.<sup>7</sup> Therefore, the main reason for choosing surgical cricothyrotomy in an emergency situation is to identify the cricothyroid ligament correctly and quickly. A single stab incision is simple, but may not be effective, particularly when there is a thick tissue over the larynx. The use of a relatively large scalpel blade (such as No. 10) with its large, curved cutting edge is suitable for incision into the skin and subcutaneous tissues.

Traditional surgical cricothyrotomy includes incision of the skin and the cricothyroid ligament, widening the incision of the ligament, and insertion of a cuffed tracheal tube. A placeholder may frequently be required to keep the incision open and for insertion of a tube-exchange catheter into the trachea to guide a tracheal tube.<sup>2</sup> An alternative method is to use a Trocar-type “percutaneous” cricothyrotomy kit once the cricothyroid ligament has been identified by surgical incision. Although there have been no studies to assess the efficacy of this alternative method, this method may be easier and quicker than conventional surgical cricothyrotomy, because there is no need to incise the cricothyroid ligament and to use a tube-exchange catheter.

## What Is Our Next Task?

With wide availability of guidelines about difficult airway management, several different preoperative tests to predict difficult airways, and new reliable airway devices, we now know how to prevent serious adverse outcomes associated with difficult airway management. Nevertheless, preoperative tests frequently fail to detect difficult airways, and thus, we would encounter failed tracheal intubation and failed oxygenation rather unexpectedly after induction of anesthesia and may fail to rescue, because of the following reasons: insufficient knowledge (not understanding how each rescue equipment works), system failures (rescue equipment not being available), delay in decision-making (delay in progression to cricothyrotomy), and technical failures (failure to insert a tube into the airway).<sup>6</sup>

So, how can we become able to decide upon and carry out rescue airway management swiftly and reliably in a situation of “cannot intubate, cannot oxygenate”? Competence in appropriate rescue management of a rare event cannot

be gained only by experience but by training. Nevertheless, it has repeatedly been pointed out that the training system for the management of difficult airways is less than ideal worldwide.<sup>8</sup> In the aviation or marine industry, a crisis management system is firmly established, and all the crews are required to undergo regular training. There is also an established training system for cardiopulmonary resuscitation. Therefore, we also should establish a standardized airway management training system (including cognitive, psychomotor, and behavioral areas). The effective training system should include not only lectures based on guidelines, but also simulation training and evaluation of the effectiveness of the training. The problem that we are facing now is that we do not know which model is effective for simulation training for emergency cricothyrotomy. Currently, the use of cadavers with lifelike conditions (Thiel embalming technique), which were used in the study by Heymans *et al.*,<sup>5</sup> would be the best, but such cadavers are usually not available for training. We urgently need to find out whether or not other models (such as porcine larynx, a manikin model, or a computer model) can also be effective.

By undergoing training on a regular basis, we will acquire full knowledge of updated guidelines about difficult airway management,<sup>1–3</sup> will be familiar with rescue techniques and equipment, and will become technically competent to perform cricothyrotomy even under stress conditions. For example, reluctance to use a scalpel for emergency cricothyrotomy may delay decision-making, but appropriate training would prevent such a delay, as shown by Heymans *et al.*<sup>5</sup>: the success rate of surgical airway was high (95%) even when performed by novices.

## Conclusions

Evidence is still insufficient to conclude which method of cricothyrotomy is more reliable than another. Nevertheless, the current state of knowledge indicates that surgical cricothyrotomy is more reliable than percutaneous cricothyrotomy as a rescue method in “cannot intubate, cannot oxygenate” situation. It is now time for us to establish a standardized airway crisis management system and to undergo training on a regular basis to rescue our patients from hypoxic damage.

## Competing Interests

The author is not supported by, nor maintains any financial interest in, any commercial activity that may be associated with the topic of this article.

## Correspondence

Address correspondence to Dr. Asai: [asaita@dokkyomed.ac.jp](mailto:asaita@dokkyomed.ac.jp)

## References

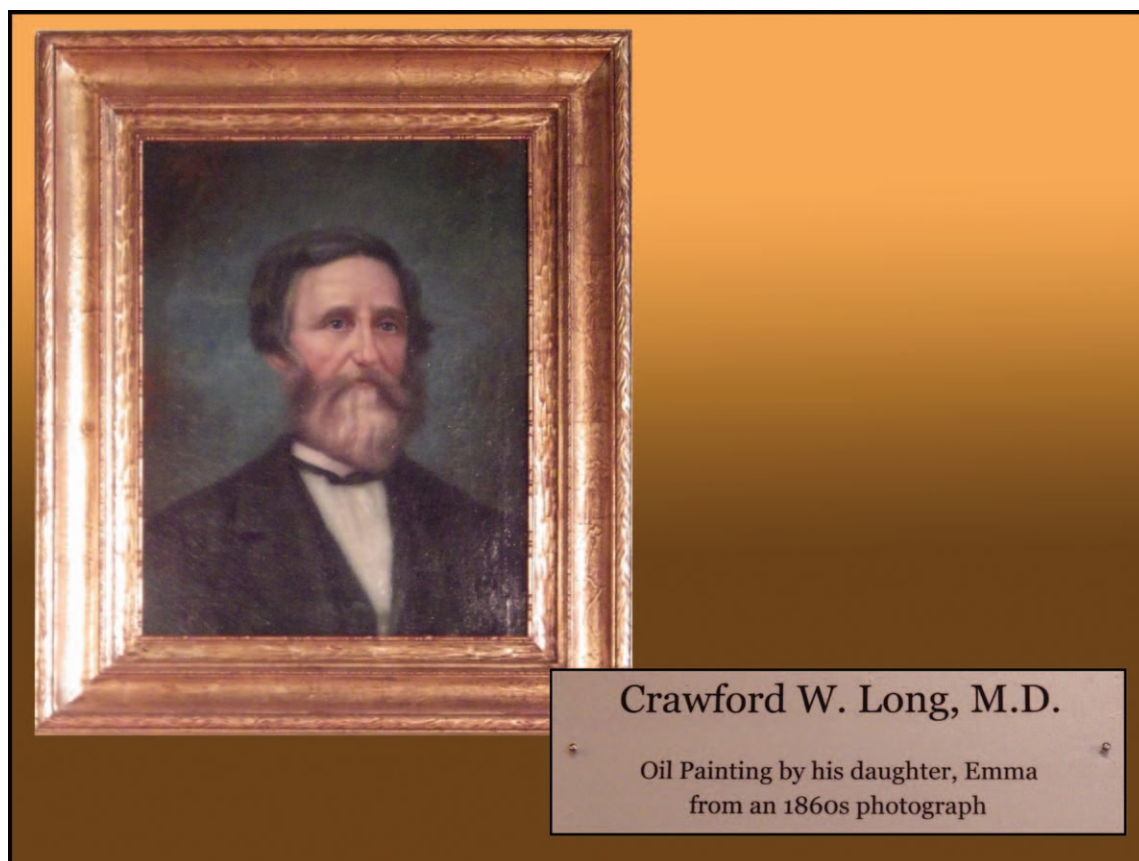
1. Apfelbaum JL, Hagberg CA, Caplan RA, Blitt CD, Connis RT, Nickinovich DG, Hagberg CA, Caplan RA, Benumof JL, Berry FA, Blitt CD, Bode RH, Cheney FW, Connis RT, Guidry OF, Nickinovich DG, Ovassapian A; American Society of

Anesthesiologists Task Force on Management of the Difficult Airway: Practice guidelines for management of the difficult airway: An updated report by the American Society of Anesthesiologists Task Force on Management of the Difficult Airway. *ANESTHESIOLOGY* 2013; 118:251–70

2. Frerk C, Mitchell VS, McNarry AF, Mendonca C, Bhagrath R, Patel A, O'Sullivan EP, Woodall NM, Ahmad I; Difficult Airway Society Intubation Guidelines Working Group: Difficult Airway Society 2015 guidelines for management of unanticipated difficult intubation in adults. *Br J Anaesth* 2015; 115:827–48
3. Japanese Society of Anesthesiologists: JSA airway management guideline 2014: To improve the safety of induction of anesthesia. *J Anesth* 2014; 28:482–93
4. Asai T: Emergency cricothyrotomy: Toward a safer and more reliable rescue method in “cannot intubate, cannot oxygenate” situation. *ANESTHESIOLOGY* 2015; 123:995–6
5. Heymans F, Feigle G, Graber S, Courvoisier DS, Weber KM, Dulguerov P: Emergent cricothyrotomy performed by surgical airway naïve medical personnel: A randomized cross over study in cadavers comparing three commonly used techniques. *ANESTHESIOLOGY* 2016; 125:295–303
6. Cook TM, Woodall N, Frerk C; Fourth National Audit Project: Major complications of airway management in the UK: Results of the Fourth National Audit Project of the Royal College of Anaesthetists and the Difficult Airway Society. Part 1: Anaesthesia. *Br J Anaesth* 2011; 106:617–31
7. Siddiqui N, Arzola C, Friedman Z, Guerina L, You-Ten KE: Ultrasound improves cricothyrotomy success in cadavers with poorly defined neck anatomy: A randomized control trial. *ANESTHESIOLOGY* 2015; 123:1033–41
8. Asai T: Strategies for difficult airway management—The current state is not ideal. *J Anesth* 2013; 27:157–60

## ANESTHESIOLOGY REFLECTIONS FROM THE WOOD LIBRARY-MUSEUM

### Painter, Poet, and Penultimate Daughter of Etherist Crawford Long: Emma Mitchell Long



The sixth of seven daughters among the dozen children fathered by ether pioneer Crawford W. Long, M.D., Emma Mitchell Long (1859 to 1935) was among the lucky seven Long children to survive childhood. Following Dr. Crawford Long's death, Emma fearlessly and poetically advocated on behalf of her father's claims as the world's first surgical etherist: "Father, thy tender voice will never cheer / Our home again, / No more its tones will soothe our fear / Or chase away our pain.... Though known to few, thy unrewarded fame / Was truly won. / Some day thy Nation's heart shall proudly claim / Her gifted son." An artist as well as a poet, Emma Long painted an oil portrait (*left*) of her father that is proudly displayed at his namesake museum in Jefferson, Georgia. Represented on the WLM's Liaison Committee, the Crawford W. Long Museum is only a 70-minute drive from Atlanta's Hartsfield-Jackson International Airport. (Copyright © the American Society of Anesthesiologists' Wood Library-Museum of Anesthesiology)

George S. Bause, M.D., M.P.H., Honorary Curator, ASA's Wood Library-Museum of Anesthesiology, Schaumburg, Illinois, and Clinical Associate Professor, Case Western Reserve University, Cleveland, Ohio. [UJYC@aol.com](mailto:UJYC@aol.com).