

# Auscultation *versus* Point-of-care Ultrasound to Determine Endotracheal *versus* Bronchial Intubation

## A Diagnostic Accuracy Study

Davinder Ramsingh, M.D., Ethan Frank, B.S., Robert Haughton, B.S., John Schilling, B.S., Kimberly M. Gimenez, M.D., Esther Banh, B.S., Joseph Rinehart, M.D., Maxime Cannesson, M.D., Ph.D.

### ABSTRACT

**Background:** Unrecognized malposition of the endotracheal tube (ETT) can lead to severe complications in patients under general anesthesia. The focus of this double-blinded randomized study was to assess the accuracy of point-of-care ultrasound in verifying the correct position of the ETT and to compare it with the accuracy of auscultation.

**Methods:** Forty-two adult patients requiring general anesthesia with ETT were consented. Patients were randomized to right main bronchus, left main bronchus, or tracheal intubation. After randomization, the ETT was placed *via* fiber-optic visualization. Next, the location of the ETT was assessed using auscultation by a separate blinded anesthesiologist, followed by an ultrasound performed by a third blinded anesthesiologist. Ultrasound examination included assessment of tracheal dilation *via* cuff inflation with air and evaluation of pleural lung sliding. Statistical analysis included sensitivity, specificity, positive predictive value, negative predictive value, and interobserver agreement for the ultrasound examination (95% CI).

**Results:** In differentiating tracheal *versus* bronchial intubations, auscultation showed a sensitivity of 66% (0.39 to 0.87) and a specificity of 59% (0.39 to 0.77), whereas ultrasound showed a sensitivity of 93% (0.66 to 0.99) and specificity of 96% (0.79 to 1). Identification of tracheal *versus* bronchial intubation was 62% (26 of 42) in the auscultation group and 95% (40 of 42) in the ultrasound group ( $P = 0.0005$ ) (CI for difference, 0.15 to 0.52), and the McNemar comparison showed statistically significant improvement with ultrasound ( $P < 0.0001$ ). Interobserver agreement of ultrasound findings was 100%.

**Conclusion:** Assessment of trachea and pleura *via* point-of-care ultrasound is superior to auscultation in determining the location of ETT. (ANESTHESIOLOGY 2016; 124:1012-20)

ENDOTRACHEAL intubation is a lifesaving procedure that is routinely performed by anesthesiologists, emergency medicine physicians, and critical care physicians. Numerous techniques exist for discriminating between endotracheal and esophageal placement.<sup>1,2</sup> However, while it is now straightforward to discriminate tracheal intubation from esophageal intubation, identifying correct location of the endotracheal tube (ETT) within the trachea remains challenging. Endobronchial intubation is the most common malposition encountered,<sup>3</sup> and it carries potential serious complications such as hypoxemia, atelectasis, hyperinflation, and barotrauma and can lead to pulmonary infection if not diagnosed early.<sup>4</sup> The American Society of Anesthesiologists Closed Claims Project showed that bronchial intubation accounts for 2% of adverse respiratory claims in adults and 4% in children.<sup>5,6</sup> Within the hospital, the frequency of inappropriate ETT location (less than 2 cm from carina) has been reported to be as high as 20%,<sup>7</sup> and bronchial intubation has been shown to be at a rate of 5 to 8% of all intubations.<sup>7,8</sup>

#### What We Already Know about This Topic

- Auscultation of breath sounds is unreliable to differentiate tracheal and bronchial intubation
- Use of point-of-care ultrasound can distinguish esophageal intubation from tracheal intubation with high sensitivity and specificity

#### What This Article Tells Us That Is New

- This prospective, randomized, double-blinded, crossover trial compared the accuracy of detecting bronchial intubation between point-of-care ultrasound and auscultation in 42 adult subjects
- The point-of-care ultrasound was a reliable technique to detect bronchial intubation by demonstrating absent contralateral pleural lung sliding on the unintubated side

Auscultation has been the standard for determining ETT location and is recommended by institutions such as the American Heart Association,<sup>9</sup> as well as major Anesthesiology and Perioperative Care text books.<sup>10</sup> However, the use of auscultation to distinguish between tracheal and bronchial

This article is featured in "This Month in Anesthesiology," page 1A. Corresponding article on page 989. Supplemental Digital Content is available for this article. Direct URL citations appear in the printed text and are available in both the HTML and PDF versions of this article. Links to the digital files are provided in the HTML text of this article on the Journal's Web site ([www.anesthesiology.org](http://www.anesthesiology.org)).

Submitted for publication February 24, 2015. Accepted for publication February 4, 2016. From the Department of Anesthesiology and Perioperative Care, University of California, Irvine, Irvine, California (D.R., E.F., R.H., J.S., K.M.G., E.B., J.R.); and Department of Anesthesiology and Perioperative Medicine, David Geffen School of Medicine, University of California, Irvine, Los Angeles, California (M.C.).

Copyright © 2016, the American Society of Anesthesiologists, Inc. Wolters Kluwer Health, Inc. All Rights Reserved. Anesthesiology 2016; 124:1012-20

intubation has been shown to be unreliable, with a reported sensitivity of only 60 to 65%.<sup>11–13</sup>

Point-of-care ultrasound is defined as ultrasonography brought to the patient and both performed and interpreted “real-time” by the provider.<sup>14</sup> It is quick and inexpensive, and with the recent development of handheld ultrasound device, it is already readily available in the clinical areas where endotracheal intubation occurs. Recent evidence has supported the use of point-of-care ultrasound for the detection of esophageal *versus* tracheal intubations with reported sensitivity/specificity of 100% for adult patients in the operating room<sup>15</sup> and 100%/86%, respectively, in patients undergoing cardiopulmonary resuscitation.<sup>16</sup> In fact, the 2015 American Heart Association Guidelines Update for Cardiopulmonary Resuscitation and Emergency Cardiovascular Care recommend the use of ultrasound as an adjunct tool to confirm correct tube position when carbon dioxide monitoring is not available.<sup>17</sup> Evidence of the use of point-of-care ultrasound to determine the location of the ETT within the trachea, however, is limited. One common sonographic sign of normal lung ventilation is a back and forth sliding of the parietal and visceral lung pleura, which is referred to as the lung sliding sign. Recent studies suggest the ability to use point-of-care ultrasound to verify bilateral ventilation by examining for lung sliding and a lung pulse,<sup>13,18</sup> with an ability to discriminate between esophageal and tracheal position to a high level of accuracy (89%).<sup>18</sup> However, while this examination may be able to detect bilateral ventilation, it does not indicate if the ETT is at risk for bronchial intubation (within 2 cm of the carina). Given that patient movement has been shown to cause significant positioning changes of the ETT,<sup>19</sup> verifying its location within the trachea is important. A recent study has suggested the usefulness of point-of-care ultrasound to distinguish between tracheal *versus* bronchial intubations in cadavers by examining for tracheal dilation from ETT cuff expansion.<sup>20</sup> This examination needs to be validated in living adult patients.

We conducted a double-blinded randomized study, testing the ability of a new point-of-care ultrasound examination (the Pulmonary tree and Lung expansion Ultrasound Study [PLUS]) to accurately discriminate between tracheal and bronchial intubation and determine appropriate location of the ETT. The currently published literature shows a 65% sensitivity to detect tube position with stethoscope auscultation<sup>12</sup>; our hypothesis is that this could be improved to 90% with point-of-care ultrasound.

## Materials and Methods

This article is presented following the STAndards for the Reporting of Diagnostic (STARD) checklist methodology for the reporting of studies of diagnostic accuracy.

### Participants

The study was performed at University of California, Irvine, after institutional review board (2013-9787) approval.

Written informed consent and information release were obtained for this double-blinded randomized study from all patients prior to their participation in the study. After consent was obtained and before transfer to the operating room, patients were assigned one of the three possible ETT locations (trachea, right main stem bronchus, or left main stem bronchus). Assignment was provided from a generated list created with an online random number generator (<http://www.randomizer.org>, last accessed March 2014). This list was created for a maximum enrollment size of 60 patients. Forty-seven patients were ultimately recruited based on inclusion criteria: at least 18 yr of age, surgery requiring an ETT, and willingness for the primary anesthesia team and patient to participate. Exclusion criteria included Mallampati score more than or equal to 3, thyromental distance less than 6 cm, and neck circumference more than 40 cm or history of difficult airway, pregnancy, and significant lung pathology in which the primary anesthesiology care team believed that the subject would not tolerate no more than 5 min of single lung ventilation. Patients of all the anesthesiologists within the department were evaluated for possible study inclusion.

### Study Protocol

**Overview.** There were a total of four anesthesiologists involved in the study. One was the primary anesthesiologist, who was one of the attending departmental faculty and was responsible for patient care throughout the study and was able to view all of the patients' vital signs and cancel the study protocol if the patient showed any signs of instability (no such events reported). The second (fiber-optic expert) was the anesthesiologist in charge of ETT positioning. The third (auscultator) was the anesthesiologist who performed the auscultation examination, and the fourth (ultrasonographer) was the anesthesiologist who performed the ultrasound examination. The second and fourth anesthesiologists were always one of the principal investigators of the study (Davinder Ramsingh [D.R.], Kimberly Gimenez [K.G.], and Maxime Cannesson [M.C.]) and, to prevent bias, this team was never allowed to be the auscultator. Both the auscultator and the ultrasonographer anesthesiologists were blinded to the ETT position. Briefly, the primary anesthesiologist (anesthesiologist 1) would place the ETT in routine fashion after induction for general anesthesia administration. Then, the ETT location (trachea, right main bronchus, or left main bronchus) was determined randomly, and the second anesthesiologist, who was one of the three study principal investigators, performed the fiber-optic examination and placed the ETT in the study position. Once this was confirmed, the third anesthesiologist, who was blinded to ETT location, performed an auscultation examination. These anesthesiologists consisted of all departmental faculty except for the three principal investigators who were either the fiber-optic expert or the ultrasonographer. Finally, the fourth anesthesiologist, who was one of the three study principal investigators, would

then perform the PLUS examination. Once both examinations were complete, the second anesthesiologist would reconfirm that the ETT was in the correct tracheal position.

**Positioning of the ETT.** After written consent was obtained in the preoperative holding area and before transfer to the operating room, patients were assigned an ETT location (trachea, right main bronchus, or left main bronchus). ETT location was randomized with an online random number generator ([www.random.org](http://www.random.org), last accessed May 26, 2015), sealed in an opaque envelope before initiation of the study, and opened in the operating room after induction of general anesthesia. After standard preoperative preparation, the study protocol was initiated with intravenous induction of general anesthesia (propofol 2 to 3 mg/kg, fentanyl 100 to 150 µg, and rocuronium or cisatracurium at the discretion of the primary anesthesia team) and tracheal intubation by the primary attending anesthesiologist. The primary anesthesiologists remained in the room for the entirety of the study and managed the patient throughout the duration of the study. After induction, the second anesthesiologist (fiber-optic expert) placed the cuffed 7.0 or 7.5 ETT (Covidien Mallinckrodt, USA) in its randomly assigned location under fiber-optic visualization. The same team of anesthesiologists (D.R., K.G., and M.C.) that performed the ultrasound examination also performed the fiber-optic examination. However, the person who performed the fiber-optic examination was never the same as the one who performed the ultrasound examination. For the tracheal group, the cuff of the ETT was placed approximately 2 to 3 cm below the vocal cords. For right main bronchus location, the tip of the ETT was placed approximately 2 to 4 cm past the carina in the right main bronchus, such that at least part of the ETT cuff was over the right main stem bronchus. Careful positioning of Murphy's eye of the ETT was performed to ensure ventilation of the right upper lobe. Patients in whom the ETT was not able to be positioned such that the cuff obstructed the right main stem and the right upper lobe remained ventilated were excluded from the study. For left main bronchus location, the tip of the ETT was placed approximately 3 to 4 cm past the carina in the left main bronchus. For both right and left bronchial locations, the investigator placing the ETT made sure Murphy's eye was past the carina to avoid ventilation in the opposite lung.

**Auscultation.** After positioning the ETT, the patient's face was covered with a towel to conceal the depth of the ETT. The screens of the anesthesia machine and general monitor were partially covered to conceal the peak and mean airway pressure readings, capnography waveform, as well as the pulse oximetry ( $\text{SpO}_2$ ) values. The audio for the  $\text{SpO}_2$  remained audible for patient safety. The primary anesthesiologist was always in charge of assuring patient safety during the study protocol as was able to visualize all the patient's vital signs. Then, the third anesthesiologist, who was blinded to the position of the ETT, was brought to the operating room and attempted to identify the location of the ETT based on auscultation of breath sounds. Since auscultation

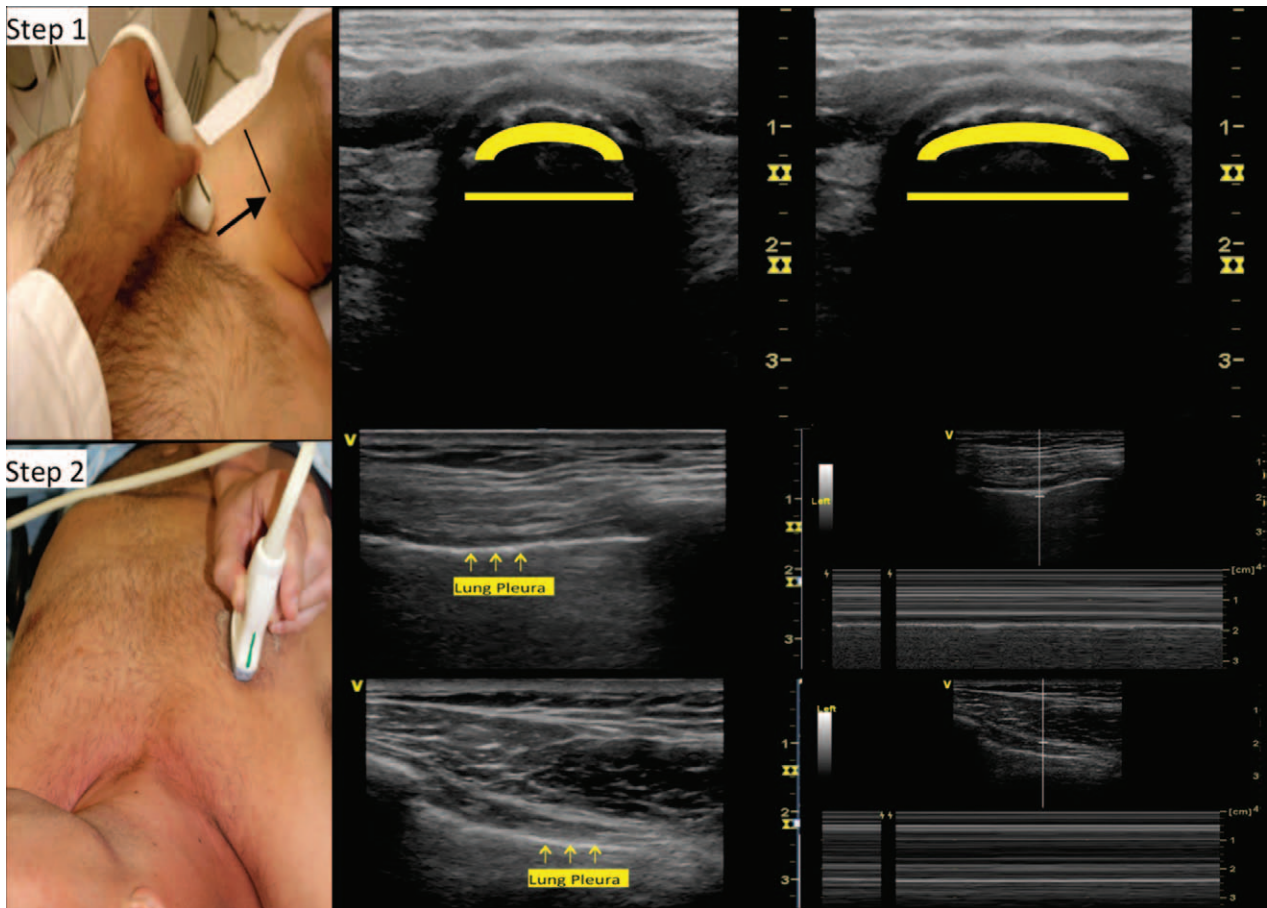
for breath sounds is regarded as a basic skill, all attending anesthesiologists, with more than 4 yr post-training, were allowed to perform the auscultation examination.

**Point-of-care Ultrasound: Pulmonary Tree and Lung Expansion Ultrasound Study.** After completion of the auscultation by the first blinded anesthesiologist, a second blinded anesthesiologist entered the room and attempted to determine ETT location by means of the PLUS examination. Only trained anesthesiologists (D.R., K.G., and M.C.) performed the examination using the General Electric LOGIQ E ultrasound machine (General Electric, USA) with a 12-MHz linear probe. Training for the PLUS examination was included in a comprehensive whole body point-of-care ultrasound curriculum, which required a minimum of 50 examinations for training completion.<sup>21</sup> In addition, the anesthesiologists who performed the PLUS examination for this study also performed an additional 25 PLUS examinations before the study start, resulting in a total of 75 examinations. Previous studies suggest that a minimum of 25 to 50 examinations are needed for training in other topics of point-of-care ultrasound in both the emergency department<sup>22</sup> and the intensive care unit.<sup>23</sup> Finally, the referenced cadaver study, highlighting the utility of ultrasound assessment of tracheal dilation, reported that after a 20-min training course using 32 novices performing 64 assessments in 8 cadavers, these novices were able to detect bronchial *versus* tracheal ETT location with a sensitivity of 91% (95% CI, 76 to 97) and specificity of 94% (95% CI, 80 to 98).<sup>20</sup>

The examination consisted of placement of the probe first on the left and right anterior chest walls, approximately at the third rib space midclavicular line, to ascertain the presence of the pleural sliding sign (Supplemental Digital Content 1, video, <http://links.lww.com/ALN/B263>) or absence of the pleural sliding sign (Supplemental Digital Content 2, video, <http://links.lww.com/ALN/B264>) *via* both two-dimensional and M-mode modalities (fig. 1). Next, the linear probe was placed transversely on the anterior neck approximately 2 cm superior to the suprasternal notch and scanned (cranially/caudally) to the cricothyroid membrane, as previously described<sup>24</sup> (fig. 1; Supplemental Digital Content 3, video, <http://links.lww.com/ALN/B265>). The presence or absence of tracheal dilation was determined *via* inflation and deflation of the ETT cuff (Supplemental Digital Content 3, video, <http://links.lww.com/ALN/B265>). All ETT cuffs were standardized to 8 ml of air inflation for the study duration and were fully deflated and reinflated during the ultrasound examination.

After completion of the ultrasound examination, the anesthesiologist (D.R., K.G., and M.C.) who initially positioned the tube under fiber-optic visualization, then repositioned the tube if necessary and ensured the recommended placement of the ETT cuff 2 to 3 cm below the vocal cords.<sup>25</sup> The three anesthesiologists (D.R., K.G., and M.C.) who were responsible for either the ultrasound or the fiber-optic placement were assigned based on their availability to one of these tasks





**Fig. 1.** Pulmonary tree and Lung expansion Ultrasound Study examination. Step 1: tracheal dilation assessment—ultrasound probe placed transversely on the anterior neck approximately 2 cm superior to the suprasternal notch and scanned cranially to the cricothyroid membrane. The marker for endotracheal cuff is tracheal dilation with balloon inflation. The image on the *left* in step 1 shows a nondilated trachea, and the one on the *right* shows a dilated trachea secondary to balloon inflation. Absence of tracheal dilation suggests that the endotracheal cuff is not in the area examined. Step 2: pleural sliding assessment—ultrasound placed vertically on the anterior chest at the third rib space midclavicular line bilaterally. Assessment of lung expansion evaluated by the detection of the horizontal movement of the two pleural linings with respiration. Use of M-mode facilitates pleural sliding assessment. The *top* image for step 2 examination shows normal pleural sliding verified with M-mode identification of pleural motion. The *bottom* image for step 2 examination shows absence of pleural sliding verified with no motion identified with M-mode.

for each patient. The person who performed the fiber-optic examination was never the same as the one who performed the ultrasound examination. All anesthesiologists involved in the study had greater than 4 yr postresidency experience, and there was no difference in the degree of average clinical training and expertise between the three principal investigators ( $10.6 \pm 7.0$  yr) and the other members of the department ( $9.8 \pm 7.5$  yr) (auscultators). Cases were captured on video and later interpreted by a separate blinded anesthesiologist, who was trained in point-of-care ultrasound but did not perform any of the study examinations, to measure the interobserver agreement in interpreting ultrasound images.

### Data Acquisition

The detection of breath sounds in each lung by the blinded auscultating anesthesiologist was recorded on a 0 to 2 scale (0: not present; 1: faintly present; 2: fully present), as well as the interpretation for the location of the tube (right main bronchus, left

main bronchus, or trachea) was recorded. The second blinded anesthesiologist, using ultrasound, assigned a numerical score ranging from 0 to 2 based on the level of lung sliding observed during respiration. Tracheal dilation was scored as a categorical “yes/no.” A final interpretation for the location of the tube (right main bronchus, left main bronchus, or trachea) was made after performing the examination (for the purposes of the primary outcome, these were reduced to tracheal/not tracheal). The subjects’ peak inspiratory pressure (PIP) and mean inspiratory pressure (MIP) were recorded at the initial ETT placement, after fiber-optic placement to randomized position, and after verification of correct return to tracheal position at the end of the protocol as well.

### Statistical Analysis

The primary outcome was the ability to detect bronchial *versus* tracheal intubation using the PLUS ultrasound examination compared to auscultation. Currently published detection

rates with stethoscope auscultation show a 65% sensitivity,<sup>12</sup> which we hoped to improve to 90% with the study-designed PLUS examination. A power analysis based on comparison of these binomial proportions to estimate sample size indicated that 42 examinations would be required, assuming an  $\alpha$  of 0.05 and a power value of 0.90. The McNemar test was used to assess for difference between the two correlated proportions of the primary marker.

Secondary outcomes included comparison of rates of correct identification of specific tube position (trachea *versus* right main bronchus *versus* left main bronchus) in each group; interobserver agreement for PLUS examination findings; sensitivity, specificity, positive predictive value (PPV), and negative predictive value (NPV) for the detection of tracheal dilation and lung sliding as a predictor of tracheal intubation; and comparison of airway pressures between the tracheal, right, and left bronchial positions.

All proportions were tested using a chi-square test without correction. Scalar data were tested with the Wilcoxon signed-rank test for repeated measures within the same patients (*e.g.*, airway pressures across study phases). Interobserver reliability was tested by simple correlation using the Spearman  $\rho$ . A value of  $P < 0.05$  was considered statistically significant, and all CIs are presented at the 95% level. Data were analyzed using SPSS 14.0 (SPSS Inc., USA) and R (www.R-project.org). Results are reported as median (25th, 75th percentiles) or as mean  $\pm$  SD as appropriate.

## Results

### Demographics

Data were collected on 47 subjects from March 2014 to August 2014, and 5 subjects were excluded from the study (4 because ETT was repositioned before ultrasound examination and 1 patient who received a laryngeal mask airway instead of ETT at the discretion of the primary anesthesiologist for the case). ETT of all four patients was repositioned secondary to inability to place the cuff over the right main stem without obstructing the right upper lobe segment. Final number of subjects per group was as follows: trachea = 15, right main stem bronchus = 18, and left main stem bronchus = 9. Patient demographic data are summarized in table 1. There was no significant difference in baseline  $\text{SpO}_2$  values and the  $\text{SpO}_2$  values during the study ( $99 \pm 1.1\%$  *versus*  $98 \pm 1.6\%$ ). Pulse oximetry values of all patients were over 96% for the entirety of the study. Similarly, there was no difference in baseline end-tidal carbon dioxide ( $\text{ETCO}_2$ ) values and the  $\text{ETCO}_2$  values during the study ( $36 \pm 6$  *versus*  $36 \pm 5.6$  mmHg). The time to complete the examination, on average, was  $162 \pm 38$  s.

### Primary Outcome: Detection of Tracheal versus Bronchial Intubation

Auscultation showed a sensitivity of 66% (95% CI, 0.39 to 0.87) and a specificity of 59% (0.39 to 0.77), while ultrasound showed a sensitivity of 93% (0.66 to 1.00)

**Table 1.** Patient Demographics

ASA class (total n = 42)	
I	0
II	18
III	22
IV	2
Age (yr)	45 $\pm$ 15
Height (inches)	68 $\pm$ 4
Weight (kg)	82 $\pm$ 18
BMI	27.7 $\pm$ 5.3
Mallampati	
1	11
2	24
3	7
4	0
Time to complete PLUS examination (s)	162 $\pm$ 38
Distance to anterior trachea (cm)	1.03 $\pm$ 0.20
Distance to lung pleura (cm)	3.07 $\pm$ 0.78

Data presented as total count or mean  $\pm$  SD.

ASA = American Society of Anesthesiologists; BMI = body mass index.

and specificity of 96% (0.79 to 0.99). Overall, the correct identification of tracheal *versus* bronchial intubation was 62% (26 of 42) in the auscultation group and 95% (40 of 42) in the PLUS group ( $P = 0.0005$ ) (CI for difference, 0.15 to 0.52). Further details of PPV and NPV are shown in tables 2, 3, and 4. The McNemar test showed a statistically significant difference between the proportion of correct ETT location identification between PLUS examination and auscultation ( $P < 0.0001$ ). Further details are shown in table 5.

### Secondary Outcomes

For the overall detection of left bronchial ETT placement, auscultation sensitivity was 71% (0.42 to 0.90) and specificity was 55% (0.22 to 0.85), while for ultrasound, sensitivity was 100% (0.73 to 1.00) and specificity was 100% (0.52 to 1.00). For the detection of right bronchial ETT placement, auscultation sensitivity was 91% (0.57 to 0.99) and specificity was 61% (0.36 to 0.82), while for ultrasound, sensitivity was 93% (0.66 to 0.99) and specificity was 94% (0.70 to 1). Further details are shown in tables 2, 3, and 4. In the absence of lung sliding, the probability of the ETT being in the contralateral main stem was 1.0. Sensitivity of this finding, however, was low at 33%. Interobserver agreement by Spearman correlation for the detection of tracheal dilation was 1.0 ( $P < 0.0001$ ). Airway pressures were captured for 37 patients. Comparison of PIP showed a statistically significant difference between the bronchial group ( $27 \pm 7$  mmHg) and the tracheal group ( $20 \pm 6$  mmHg) during the study ( $P = 0.002$ ). There was also a statistically significant decrease ( $P = 0.024$ ) in PIP in the bronchial group post-ETT repositioning to the trachea ( $27 \pm 7$  to  $22 \pm 7$  mmHg). Changes in MIP between groups and during phases of the study were not significant.

**Table 2.** Test Characteristics and Results of Chest Auscultation vs. Point-of-care Ultrasound PLUS Examination: Tracheal vs. Main Stem

Ultrasound		True Position			Auscultation		True Position		
		Main stem	Trachea	Total			Main stem	Trachea	Total
Trachea		1	14	15	Trachea		11	10	21
Main stem		26	1	27	Main stem		16	5	21
Total		27	15	42	Total		27	15	42
Chi-square Comparison (ultrasound vs. auscultation) $P = 0.0005$		Number correct					Number correct		
		40 (95%)					26 (62%)		
% (95% CI)	Sensitivity	93 (66–99)	PPV	93 (66–100)	Sensitivity		66 (39–87)	PPV	48 (26–70)
% (95% CI)	Specificity	96 (79–100)	NPV	96 (79–100)	Specificity		59 (39–77)	NPV	76 (52–90)

Chi-square comparison showed statistically significant improvement with ultrasound vs. auscultation for the detection of (1) trachea vs. main stem intubation ( $P = 0.0005$ ), (2) trachea vs. main stem left intubation ( $P = 0.0004$ ), and (3) trachea vs. right main stem intubation ( $P = 0.0371$ ).

NPV = negative predictive value; PLUS = Pulmonary tree and Lung expansion Ultrasound Study; PPV = positive predictive value.

**Table 3.** Test Characteristics and Results of Chest Auscultation vs. Point-of-care Ultrasound PLUS Examination: Tracheal vs. Left Main Stem

Ultrasound		True Position			Auscultation		True Position		
		MSL	Trachea	Total			MSL	Trachea	Total
Trachea		0	14	14	Trachea		4	10	14
MSL		9	0	9	MSL		5	4	9
Total		9	14	23	Total		9	14	23
Chi-square Comparison (ultrasound vs. auscultation) $P = 0.0004$		Number correct					Number correct		
		22 (100%)					15 (65%)		
% (95% CI)	Sensitivity	1 (73–100)	PPV	1 (73–100)	Sensitivity		71 (42–90)	PPV	71 (42–90)
% (95% CI)	Specificity	1 (52–100)	NPV	1 (52–100)	Specificity		55 (22–85)	NPV	55 (22–85)

Chi-square comparison showed statistically significant improvement with ultrasound vs. auscultation for the detection of (1) trachea vs. main stem intubation ( $P = 0.0005$ ), (2) trachea vs. main stem left intubation ( $P = 0.0004$ ), and (3) trachea vs. right main stem intubation ( $P = 0.0371$ ).

MSL = main stem left; NPV = negative predictive value; PLUS = Pulmonary tree and Lung expansion Ultrasound Study; PPV = positive predictive value.

**Table 4.** Test Characteristics and Results of Chest Auscultation vs. Point-of-care Ultrasound PLUS Examination: Tracheal vs. Right Main Stem

Ultrasound		True Position			Auscultation		True Position		
		MSR	Trachea	Total			MSR	Trachea	Total
Trachea		1	14	15	Trachea		7	10	17
MSR		17	1	18	MSR		11	1	12
Total		18	15	33	Total		18	11	29
Chi-square Comparison (ultrasound vs. auscultation) $P = 0.0371$		Number correct					Number correct		
		31 (94%)					21 (72%)		
% (95% CI)	Sensitivity	93 (66–99)	PPV	93 (66–100)	Sensitivity		91 (57–99)	PPV	58 (33–80)
% (95% CI)	Specificity	94 (70–100)	NPV	96 (69–100)	Specificity		61 (36–82)	NPV	92 (60–99)

Chi-square comparison showed statistically significant improvement with ultrasound vs. auscultation for the detection of (1) trachea vs. main stem intubation ( $P = 0.0005$ ), (2) trachea vs. main stem left intubation ( $P = 0.0004$ ), and (3) trachea vs. right main stem intubation ( $P = 0.0371$ ).

MSR = main-stem right; NPV = negative predictive value; PLUS = Pulmonary tree and Lung expansion Ultrasound Study; PPV = positive predictive value.

## Discussion

The stethoscope was invented by Laennec in 1816, two centuries ago. Since that time, it has remained the pinnacle tool for physicians to examine their patients. While other industries have significantly advanced during the past centuries, physicians still rely on this historic device as the primary tool to examine patients. This randomized, prospective, double-blinded

study shows that the use of point-of-care ultrasound is highly accurate for localization of the ETT within the trachea by examining for tracheal dilation and pleural lung sliding (PLUS examination). Our study is the first to show that an easy, quick (less than 4 min), and potentially widely available point-of-care ultrasound examination is significantly more accurate than auscultation to discriminate between tracheal

**Table 5.** Correlated Proportion Comparison of Auscultation to Ultrasound for Correct Endotracheal Tube Identification

		Ultrasound	
		Correct ET Identification	
		Yes	No
Auscultation	Yes	26	0
Correct ET identification	No	14	2

The McNemar test result (two-tailed)  $P < 0.0001$ .

ET = endotracheal tube.

*versus* bronchial intubation in adult patients under general anesthesia. This examination (PLUS) can be performed with a high degree of sensitivity and specificity after completing 75 examinations, and it appears to be easily interpretable after this level of training (interobserver agreement 1.0).

Other common strategies used to confirm correct location of the ETT within trachea have various limitations. The use of standardized sizing for tube depth based on height and weight is prone to error,<sup>4</sup> and assessment of PIP has also proven to be unreliable.<sup>26</sup> More importantly, the use of auscultation, PIP or MIP, and tube depth does not detect ETT locations that are at risk for bronchial transition (less than 2 cm from carina<sup>7</sup>). The point-of-care ultrasound examination performed in this study (PLUS) can identify appropriate placement of ETT at the midtracheal level. Similarly, capnography can be useful for identifying if the ETT is in the airway or the esophagus, but it cannot reliably detect wherein the airway the tube has been placed.<sup>26</sup> Chest x-rays expose patients to harmful radiation and also require time to capture and develop the image during which a patient could be improperly ventilated. Lastly, arterial blood gasses can detect issues with oxygenation in the blood but cannot specifically identify problems in ETT placement.

This study demonstrates a statistically significant improvement with the detection of bronchial intubation with the use of point-of-care ultrasound compared with auscultation using a stethoscope. With regard to the PLUS examination, the use of tracheal dilation proved to be the most useful to the ultrasonographer to determine whether or not the tracheal cuff was in the main trachea. Once this was determined, the assessment of pleural sliding aided with suggesting the possible bronchial location. However, this was more challenging for the ultrasonographer to interpret. This is likely secondary to the fact that it remains difficult to completely isolate a lung field with a standard single-lumen ETT such that no pressure is delivered and thus prevent pleural sliding. This point emphasizes the importance of looking at both components of the PLUS examination to determine ETT location, as lack of lung sliding may be secondary to other pathology besides bronchial intubation (pneumothorax, mucous plug, pleural fibrosis, *etc.*), which is a common limitation with auscultation. Despite this, however, the PLUS examination showed an improved ability to detect

both right and left bronchial intubation over auscultation. Even with a high artificial incidence of bronchial intubation, the data show an NPV of 96% (CI, 0.79 to 1) with ultrasound compared with 76% (CI, 0.52 to 0.90) when auscultating. This observed 20% improvement in the detection of improper ETT placement comes with the application of a noninvasive ultrasound examination. We emphasize, as well, that the significantly improved sensitivity and specificity is not affected by the prevalence.

However, despite the technology being available, the use of point-of-care ultrasound is not widespread. This is probably secondary to the challenge of training perioperative physicians on point-of-care ultrasound.<sup>27</sup> This study highlights the utility of point-of-care ultrasound to help with ETT location assessment and suggests the importance of education and training on this emerging diagnostic tool. Recent research also supports point-of-care ultrasound education to anesthesiologists and highlights the potential clinical utility of point-of-care ultrasound training.<sup>21,27,28</sup> With further research in this area, perhaps ultrasound can be suggested for airway management in future guidelines.

### Limitations

One limitation is that the ultrasound examination performed and interpreted in this study was done by anesthesiologists that had received significant training in this area. As with most diagnostic tools, both the components allow for the possibility of error. This study utilized only three attending anesthesiologists to perform the ultrasound examinations. Support exists for training anesthesiologists on point-of-care ultrasound,<sup>29</sup> but further studies are needed to evaluate the ability to train and apply this study among a larger group of anesthesiologists. Second, because of randomization of tube location, this study does not indicate any significant change in the incidence of endotracheal intubation or a change in postoperative complications. Further studies are required to evaluate the use of ultrasound within a population of patients to evaluate if the use of ultrasound can actually decrease postoperative complications. Along with this, it is important to note the limitation of the fact that the rate of main stem intubation was dramatically higher (64%) than what is expected in actual clinical occurrence. This would contribute to a potentially higher than expected PPV. Third, given the likely concern for the primary anesthesiologists to avoid ETT manipulation on patients with a difficult airway, this study excluded patients who had a history of physical examination findings that would suggest a challenging airway. Similarly, this study also excluded patients with known pulmonary pathology. Additional studies will have to evaluate the utility of the PLUS examination in these patients. Fourth, we did not allow both the auscultator and the ultrasonographer to use the other modalities used to position ETT (ETCO<sub>2</sub>, SpO<sub>2</sub>, and PIP) as this study was designed to directly compare auscultation to ultrasound. Further studies should evaluate the utility of ultrasound when all routine parameters are incorporated. Similarly, the audible sound of



the pulse oximetry was not muted for patient safety. While it is possible that this may bias the blinded examiners, our results showed that no patient had a pulse oximetry value less than 96% during the study, and these examiners were not present during the single lung ventilation and so would not be able to notice the slight pulse oximetry audible change. Regarding main stem intubations, the ability to place a single-lumen ETT in either the left or the right main bronchus is challenging, with issues of obstruction of right upper quadrant and herniation after cuff inflation. Finally, the incidence of bronchial intubation with our study design is higher than what would be expected in real-life setting. As the incidence of an event impacts the PPV and NPV of test aiming at the detection of such events, these values reported in our study should be interpreted accordingly. However, it would require several hundreds of patients to obtain meaningful information on the accuracy of point-of-care ultrasound to detect bronchial intubation in the general population.

## Conclusions

While requiring proper training, this study demonstrates that point-of-care ultrasound is a highly accurate tool to determine the appropriate ETT position and adds to the growing body of evidence supporting further development of point-of-care ultrasound for perioperative medicine.

## Acknowledgments

The education of the ultrasound examination that was performed in this study was supported by a Research in Education Grant from the Foundation for Anesthesia Education and Research, Schaumburg, Illinois (fund no. = 40875). Departmental support was also provided for this study's clinical application.

## Competing Interests

Drs. Ramsingh and Cannesson are recipients of a Research in Education Grant from the Foundation for Anesthesia Education and Research, Schaumburg, Illinois. Dr. Cannesson has received departmental funding from Edwards Lifesciences, Irvine, California, Masimo, Irvine, California, and Medtronic-Covidien, Boulder, Colorado. The other authors declare no competing interests.

## Reproducible Science

Full protocol available from Khanhvan Le (Research Supervisor, Department of Anesthesiology and Perioperative Care, University of California Irvine, Orange, California): [khanhval@uci.edu](mailto:khanhval@uci.edu). Raw data available from Khanhvan Le: [khanhval@uci.edu](mailto:khanhval@uci.edu).

## Correspondence

Address correspondence to Dr. Ramsingh: Department of Anesthesiology and Perioperative Care, University of California, Irvine, 333 City Boulevard West Side, Orange, California 92868. [dramsing@uci.edu](mailto:dramsing@uci.edu). This article may be accessed for personal use at no charge through the Journal Web site, [www.anesthesiology.org](http://www.anesthesiology.org).

## References

1. Grmec S: Comparison of three different methods to confirm tracheal tube placement in emergency intubation. *Intensive Care Med* 2002; 28:701–4
2. Knapp S, Kofler J, Stoiser B, Thalhammer F, Burgmann H, Posch M, Hofbauer R, Stanzel M, Frass M: The assessment of four different methods to verify tracheal tube placement in the critical care setting. *Anesth Analg* 1999; 88:766–70
3. Szekely SM, Webb RK, Williamson JA, Russell WJ: The Australian Incident Monitoring Study. Problems related to the endotracheal tube: An analysis of 2000 incident reports. *Anaesth Intensive Care* 1993; 21:611–6
4. Owen RL, Cheney FW: Endobronchial intubation: A preventable complication. *ANESTHESIOLOGY* 1987; 67:255–7
5. Caplan RA, Posner KL, Ward RJ, Cheney FW: Adverse respiratory events in anesthesia: A closed claims analysis. *ANESTHESIOLOGY* 1990; 72:828–33
6. Morray JP, Geiduschek JM, Caplan RA, Posner KL, Gild WM, Cheney FW: A comparison of pediatric and adult anesthesia closed malpractice claims. *ANESTHESIOLOGY* 1993; 78:461–7
7. Geisser W, Maybauer DM, Wolff H, Pfenninger E, Maybauer MO: Radiological validation of tracheal tube insertion depth in out-of-hospital and in-hospital emergency patients. *Anaesthesia* 2009; 64:973–7
8. Bissinger U, Lenz G, Kuhn W: Unrecognized endobronchial intubation of emergency patients. *Ann Emerg Med* 1989; 18:853–5
9. Guidelines for cardiopulmonary resuscitation and emergency cardiac care. Emergency Cardiac Care Committee and Subcommittees, American Heart Association. Part I. Introduction. *JAMA* 1992; 268:2171–83
10. Stone D, Gal T: *Anesthesia, Airway Management*, 5th edition. Edited by Miller RD. Philadelphia, Churchill Livingstone, 2000
11. Brunel W, Coleman DL, Schwartz DE, Peper E, Cohen NH: Assessment of routine chest roentgenograms and the physical examination to confirm endotracheal tube position. *Chest* 1989; 96:1043–5
12. Sitzwohl C, Langheinrich A, Schober A, Krafft P, Sessler DI, Herkner H, Gonano C, Weinstabl C, Kettner SC: Endobronchial intubation detected by insertion depth of endotracheal tube, bilateral auscultation, or observation of chest movements: Randomised trial. *BMJ* 2010; 341:c5943
13. Vezzani A, Manca T, Brusasco C, Santori G, Valentino M, Nicolini F, Molardi A, Gherli T, Corradi F: Diagnostic value of chest ultrasound after cardiac surgery: A comparison with chest X-ray and auscultation. *J Cardiothorac Vasc Anesth* 2014; 28:1527–32
14. Moore C CJ: Point-of-care ultrasonography. *The New England Journal of Medicine* 2011; 749–57
15. Muslu B, Sert H, Kaya A, Demircioglu RI, Gözdemir M, Usta B, Boynukalin KS: Use of sonography for rapid identification of esophageal and tracheal intubations in adult patients. *J Ultrasound Med* 2011; 30:671–6
16. Chou HC, Chong KM, Sim SS, Ma MH, Liu SH, Chen NC, Wu MC, Fu CM, Wang CH, Lee CC, Lien WC, Chen SC: Real-time tracheal ultrasonography for confirmation of endotracheal tube placement during cardiopulmonary resuscitation. *Resuscitation* 2013; 84:1708–12
17. Neumar RW, Shuster M, Callaway CW, Gent LM, Atkins DL, Bhanji F, Brooks SC, de Caen AR, Donnino MW, Ferrer JM, Kleinman ME, Kronick SL, Lavonas EJ, Link MS, Mancini ME, Morrison LJ, O'Connor RE, Samson RA, Schexnayder SM, Singletary EM, Sinz EH, Travers AH, Wyckoff MH, Hazinski MF: Part 1: Executive Summary: 2015 American Heart Association Guidelines Update for Cardiopulmonary Resuscitation and Emergency Cardiovascular Care. *Circulation* 2015; 132(18 suppl 2):S315–67
18. Sim SS, Lien WC, Chou HC, Chong KM, Liu SH, Wang CH, Chen SY, Hsu CY, Yen ZS, Chang WT, Huang CH, Ma MH,



- Chen SC: Ultrasonographic lung sliding sign in confirming proper endotracheal intubation during emergency intubation. *Resuscitation* 2012; 83:307–12
19. Heinonen J, Takki S, Tammisto T: Effect of the Trendelenburg tilt and other procedures on the position of endotracheal tubes. *Lancet* 1969; 1:850–3
20. Kerforne T, Petitpas F, Scepi M, Loupec T, Dufour J, Nanadoumgar H, Richer JP, Cornu-Skurnik A, Bendahou M, Riou B, Debaene B, Mimoz O: Accurate and easy to learn ultrasound sign to confirm correct tracheal intubation in cadaver model. *Br J Anaesth* 2013; 111:510–1
21. Ramsingh D, Rinehart J, Kain Z, Strom S, Canales C, Alexander B, Capatina A, Ma M, Le KV, Cannesson M: Impact assessment of perioperative point-of-care ultrasound training on anesthesiology residents. *ANESTHESIOLOGY* 2015; 123:670–82
22. American College of Emergency P: Emergency ultrasound guidelines. *Ann Emerg Med* 2009; 53: 550–70
23. Killu K, Coba V, Mendez M, Reddy S, Adrzejewski T, Huang Y, Ede J, Horst M: Model point-of-care ultrasound curriculum in an intensive care unit fellowship program and its impact on patient management. *Crit Care Res Pract* 2014; 2014:934796
24. Uya A, Spear D, Patel K, Okada P, Sheeran P, McCreight A: Can novice sonographers accurately locate an endotracheal tube with a saline-filled cuff in a cadaver model? A pilot study. *Acad Emerg Med* 2012; 19:361–4
25. Salem MR: Verification of endotracheal tube position. *Anesthesiol Clin North America* 2001; 19:813–39
26. Ezri T, Khazin V, Szmuk P, Medalion B, Shechter P, Priel I, Loberboim M, Weinbroum AA: Use of the Rapiscope *vs* chest auscultation for detection of accidental bronchial intubation in non-obese patients undergoing laparoscopic cholecystectomy. *J Clin Anesth* 2006; 18:118–23
27. Johnson DW, Oren-Grinberg A: Perioperative point-of-care ultrasonography: The past and the future are in anesthesiologists' hands. *ANESTHESIOLOGY* 2011; 115:460–2
28. Ramsingh D, Fox JC, Wilson WC: Perioperative point-of-care ultrasonography: An emerging technology to be embraced by anesthesiologists. *Anesth Analg* 2015; 120:990–2
29. Ramsingh D, Alexander B, Le K, Williams W, Canales C, Cannesson M: Comparison of the didactic lecture with the simulation/model approach for the teaching of a novel perioperative ultrasound curriculum to anesthesiology residents. *J Clin Anesth* 2014; 26:443–54