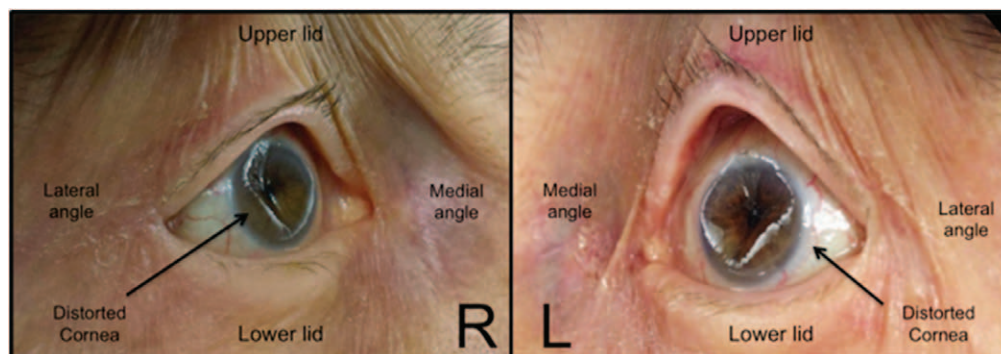


# Severe Bilateral Ocular Hypotony after Emergent Coronary Artery Bypass Graft Surgery Complicated with Cardiogenic Shock

Gustavo Munoz, M.D., Shvetank Agarwal, M.D., Manuel R. Castresana, M.D.



**I**NTRAOCULAR hypotony (IH), defined as a decrease in intraocular pressure (IOP) below 5 mmHg, is sometimes seen after ocular surgeries, but it is rarely clinically significant unless IOP decreases to the 0 to 4 mmHg range.<sup>1</sup> Severe IH after cardiac surgery

is exceedingly rare.<sup>2</sup> The figure shows a marked bilateral distortion of the corneas with an almost “sucked-in effect” in an elderly patient who underwent an emergent coronary artery bypass grafting with hypothermic cardiopulmonary bypass complicated by cardiogenic and vasoplegic shock with severe lactic acidosis.

Acute decrease in IOP after hypothermic cardiopulmonary bypass may occur due to alterations in aqueous humor fluid dynamics, either by decreasing production of aqueous humor fluid due to a decrease in ophthalmic and ciliary artery blood flow or by increasing drainage because of either an increase in plasma oncotic pressure or a decrease in central venous pressure.<sup>2,3</sup> Other factors that may play a role are decreases in the choroidal blood and vitreous volume as well as in extraocular muscle tone.<sup>2,3</sup> All of these mechanisms can easily be influenced by anesthetic drugs and exacerbated by prolonged hypothermia, systemic hypertonicity, persistent hypotension, aggressive diuresis, and severe acid–base disturbances, which may warrant frequent corneal examination during and after surgery in high-risk patients.

Intraocular hypotony may cause acute loss of vision because of corneal edema and formation of Descemet’s folds, cataracts, anterior rotation of the lens–iris diaphragm, maculopathy characterized by horizontal choroidal folds, engorged tortuous vessels, and optic nerve edema, finally leading to phthisis bulbi or atrophic bulbi with complete intraocular disorganization in chronic cases.<sup>1</sup> Ocular movements are rarely affected.

Management of IH depends on the cause and may involve steroids or surgery for postinflammatory and postsurgical IH, respectively<sup>1,4</sup>; however, acute IH after cardiac surgery may be reversed simply by correction of systemic hyperosmolality and acid–base disturbances. It is unknown whether patients with chronic IH are more susceptible to these changes in IOP during cardiac surgery and whether this condition can be significant enough to cause long-term complications. Our patient required no treatment other than hemodynamic stability and correction of the acid–base disturbance and was discharged without any visual or motor alterations. Further studies are required to clarify the physiological mechanisms of IOP changes and the relation between IOP changes and cardiac surgery.

## Competing Interests

The authors declare no competing interests.

## Correspondence

Address correspondence to Dr. Agarwal: [sagarwal@gru.edu](mailto:sagarwal@gru.edu)

## References

1. Fine HF, Biscette O, Chang S, Schiff WM: Ocular hypotony: A review. *Compr Ophthalmol Update* 2007; 8:29–37
2. Kubo N, Sakuragi T, Mayama T, Shinokuma T, Horie T, Dan K: Collapsed anterior chamber during hypothermic cardiopulmonary bypass. *Anesth Analg* 1998; 86:919–20
3. Hayashi H, Kawaguchi M, Hasuwa K, Inoue S, Okamoto M, Matsuura T, Taniguchi S, Furuya H: Changes in intraocular pressure during cardiac surgery with and without cardiopulmonary bypass. *J Anesth* 2010; 24:663–8
4. Pederson JE: Ocular hypotony. *Trans Ophthalmol Soc U K* 1986; 105 (Pt 2):220–6

From the Department of Anesthesiology and Perioperative Medicine, Medical College of Georgia, Georgia Regents University, Augusta, Georgia.  
Copyright © 2015, the American Society of Anesthesiologists, Inc. Wolters Kluwer Health, Inc. All Rights Reserved. *Anesthesiology* 2016; 124:722