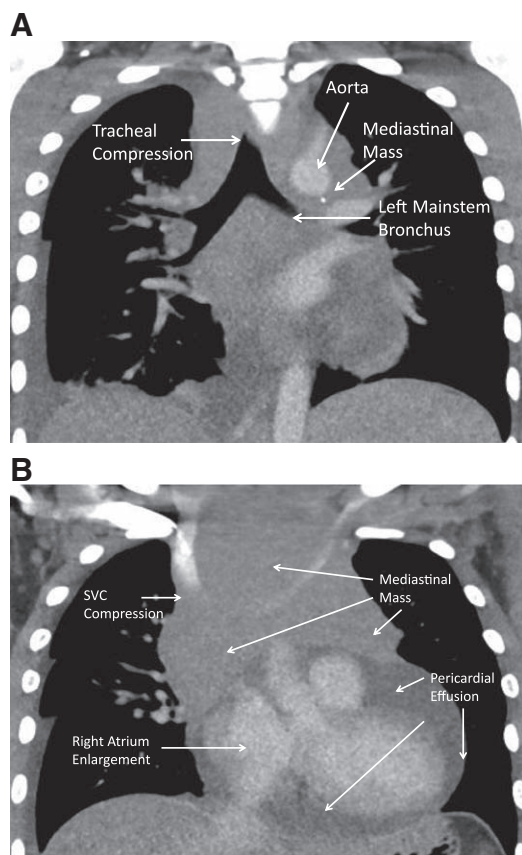


Charles D. Collard, M.D., Editor
 Alan Jay Schwartz, M.D., M.S. Ed., Associate Editor

Compressive Mediastinal Mass and Large Pericardial Effusion in a Child

Adam C. Adler, M.D., M.S., Alan Jay Schwartz, M.D., M.S. Ed., Aruna T. Nathan, M.B.B.S.



COMPUTED tomography (CT) provides a multitude of information for the anesthesiologist tasked with providing safe care to patients with mediastinal masses and pericardial effusions. CT may suggest the extent of disease providing clues as to how it interplays with the cardiopulmonary systems during induction of anesthesia. An 11-yr-old with facial swelling and lymphadenopathy provides an excellent example of these circumstances.

Figure A identifies a mediastinal mass with significant aortic encasement and trachea-bronchial compression. Aortic compression drastically increases afterload and combined with decreased preload from a pericardial effusion causes decrements in cardiac output. The tracheal and bronchial narrowing is of significant concern as induction of anesthesia results in relaxation of extrinsic muscle compressing both the airway and intrapulmonary vasculature.

Figure B identifies a mediastinal mass with superior vena cava (SVC) compression, pericardial effusion, and right atrial enlargement. Pericardial effusion decreases right ventricular distensibility, right and left systolic ventricular function, and cardiac output.¹ Increase in pulmonary vascular resistance from vascular compression by extrinsic muscles or directly *via* hypoventilation and hypercarbia results in increased right ventricular afterload, which decreases left ventricular preload. SVC compression leads to engorgement of the head and neck, predisposes the patient to thrombosis, and reduces cardiac preload. Patients with SVC compression should have vascular access placed in the lower extremities to ensure delivery of medications and fluids.² Right atrial enlargement suggests increased right ventricular pressure and should alert the anesthesiologist to the level of cardiac compensatory exhaustion (fig. B).

As such, before induction, anesthesiologists should review a recent CT for all patients with mediastinal masses.³ CT findings may indicate the need for rescue cardiopulmonary bypass or rigid bronchoscopy for control of hemodynamic or airway collapse. Avoidance of depressant anesthetics and providing incrementally titrated sedation might offer a safer approach. Use of local anesthetic may be sufficient for percutaneous drainage of the pericardial effusion.

Competing Interests

The authors declare no competing interests.

Correspondence

Address correspondence to Dr. Adler: adlera@email.chop.edu

References

1. Fernández JA, Robles R, Acosta F, Sansano T, Parrilla P: Cardiovascular changes during drainage of pericardial effusion by thoracoscopy. *Br J Anaesth* 2004; 92:89–92
2. Erdős G, Tzanova I: Perioperative anaesthetic management of mediastinal mass in adults. *Eur J Anaesthesiol* 2009; 26:627–32
3. Slinger P, Karsli C: Management of the patient with a large anterior mediastinal mass: Recurring myths. *Curr Opin Anaesthesiol* 2007; 20:1–3

From the Department of Anesthesiology and Critical Care Medicine (A.C.A., A.J.S., A.T.N.) and Division of Cardiothoracic Anesthesiology (A.T.N.), The Children's Hospital of Philadelphia, Perelman School of Medicine of The University of Pennsylvania, Philadelphia, Pennsylvania. Copyright © 2015, the American Society of Anesthesiologists, Inc. Wolters Kluwer Health, Inc. All Rights Reserved. *Anesthesiology* 2015; 123:928