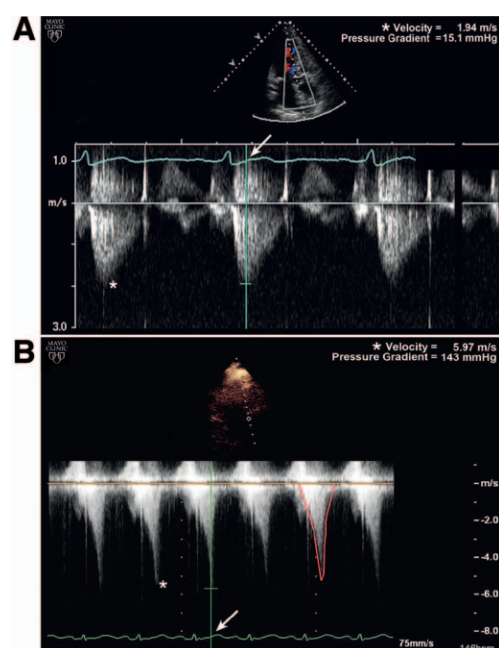


Charles D. Collard, M.D., Editor
 Alan Jay Schwartz, M.D., M.S. Ed., Associate Editor

Images in Anesthesiology: Dobutamine-induced Intraventricular Obstruction

A “Dagger” to the Anesthetized Heart?

Maria D. Fritock, M.D., Megan N. Manento, M.D., Leal G. Segura, M.D.



DURING dobutamine stress echocardiography, Doppler recordings across the left ventricular outflow tract are obtained both at rest and with stress if the sonographer notes hyperdynamic function or systolic anterior motion of the anterior mitral valve leaflet. Figure A demonstrates a normal continuous-wave Doppler recording through the left ventricular outflow tract at rest. The velocity begins to rise after aortic valve opening and peaks at 1.9 m/s in early systole. In both parts of the figure, an asterisk marks the peak velocity, and an arrow identifies the point in the electrocardiogram waveform that temporally coincides with the peak velocity. The pressure gradient (ΔP) is calculated using the modified Bernoulli equation where $\Delta P = 4 \times (\text{peak velocity})^2$. In figure B, continuous-wave Doppler interrogation during dobutamine stress reveals significant dynamic left ventricular outflow tract obstruction with the characteristic “dagger-shaped” Doppler spectrum traced in red. This velocity peaks at 5.9 m/s in mid-to-late systole, as drag forces and the Venturi effect culminate in mitral leaflet-septal contact.

Dynamic obstruction related to dobutamine stress, defined as a late-peaking Doppler signal that exceeds the velocity at rest by at least 1 m/s or an absolute velocity of greater than 2.5 m/sec, can occur in both hypertrophied and normal thickness ventricles.^{1,2} Intraventricular obstruction may be related to mitral systolic anterior motion or to obliteration of the intracavitary space from hyperdynamic wall motion. Clinical manifestations in

an anesthetized patient could include refractory hypotension, mitral valve regurgitation, pulmonary edema, or cardiac arrest.³

Whether intraventricular obstruction on preoperative dobutamine stress echocardiography is predictive of hemodynamic instability during anesthesia deserves further study. The vasodilatory effects of general or neuraxial anesthesia, in conjunction with perioperative volume depletion and increased adrenergic tone, may mimic the dobutamine effect and lead to obstruction in these patients. The risk of dynamic obstruction may be reduced by β -adrenergic blockade, maintenance of normal sinus rhythm and systemic vascular resistance, fluid resuscitation, and avoidance of inotropes.³

Acknowledgments

Support was provided solely from institutional and/or departmental sources.

Competing Interests

The authors declare no competing interests.

Correspondence

Address correspondence to Dr. Fritock: fritock.maria@mayo.edu

References

1. Pellikka PA, Oh JK, Bailey KR, Nichols BA, Monahan KH, Tajik AJ: Dynamic intraventricular obstruction during dobutamine stress echocardiography: A new observation. *Circulation* 1992; 86:1429–32
2. Roldan FJ, Vargas-Barron J, Espinola-Zavaleta N, Keirns C, Romero-Cardenas A: Severe dynamic obstruction of the left ventricular outflow tract induced by dobutamine. *Echocardiography* 2000; 17:37–40
3. Gajewski M, Hillel Z: Anesthesia management of patients with hypertrophic obstructive cardiomyopathy. *Prog Cardiovasc Dis* 2012; 54:503–11

From the Department of Anesthesiology, Mayo Clinic College of Medicine, Rochester, Minnesota (M.D.F.).

Copyright © 2014, the American Society of Anesthesiologists, Inc. Wolters Kluwer Health, Inc. All Rights Reserved. *Anesthesiology* 2015; 122:1414