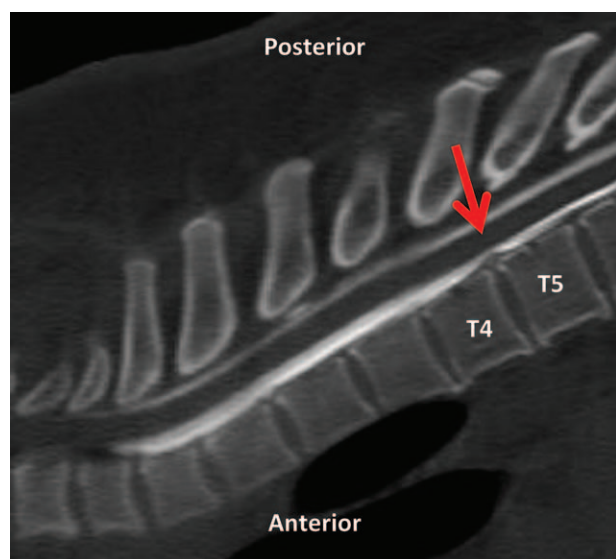


Charles D. Collard, M.D., Editor  
 Alan Jay Schwartz, M.D., M.S. Ed., Associate Editor

## Localization of Cerebrospinal Fluid Leak in a Case of Spontaneous Intracranial Hypotension Using Dynamic Computed Tomography Myelography

Brian E. Harrington, M.D.



**E**PIDURAL blood patch is the mainstay of treatment for persistent symptoms secondary to spontaneous intracranial hypotension.<sup>1</sup> Determining the level of cerebrospinal fluid leak is thought to be an important consideration for optimal siting of the epidural blood patch injection.<sup>2</sup> However, it is often difficult to determine the level of cerebrospinal fluid leak in spontaneous intracranial hypotension. “Dynamic” (as opposed to conventional) computed tomography myelography has recently emerged as a preferred diagnostic test for high-flow (“fast”) cerebrospinal fluid leaks, suspected by extra-arachnoid fluid on spinal magnetic resonance imaging.<sup>3</sup> With dynamic computed tomography myelography, myelographic contrast is injected with the patient in the computed tomography scanner (tilted Trendelenburg using a wedge), followed by immediate and multiple computed tomography acquisitions.

A 33-yr-old male patient presented to the emergency department with severe occipital headache. Computed tomography of the head demonstrated a chronic subdural hematoma. Head contrast magnetic resonance imaging showed diffuse dural gadolinium enhancement and a “sagging” brain. Spine magnetic resonance imaging revealed circumferential extradural fluid (“scattered” in cervical and “diffuse” in thoracic and lumbar regions). Surgical drainage of the subdural hematoma was performed. On postoperative day 1, headache symptoms were improved with no residual hematoma on repeated computed tomography of the head.

However, persistent postural headaches prompted consultation of the acute pain service for evaluation and management of spontaneous intracranial hypotension. Despite lumbar epidural blood patch followed by 2 days of bed rest, headache symptoms returned on upright positioning. Dynamic computed tomography myelography performed on postoperative day 6 showed a high-flow cerebrospinal fluid leak between T4 and T5 (arrow in fig.), secondary to a midline spiculated osteophyte (arrow). Using fluoroscopic guidance, an epidural blood patch was performed between T3 and T4 (14 ml). Headache symptoms resolved and had not recurred at 12-month follow-up.

### Competing Interests

The author declares no competing interests.

### Correspondence

Address correspondence to Dr. Harrington: bhhbillings@aol.com

### References

1. Rahman M, Bidari SS, Quisling RG, Friedman WA: Spontaneous intracranial hypotension: Dilemmas in diagnosis. *Neurosurgery* 2011; 69:4–14; discussion 14
2. Warwick WI, Neal JM: Beyond spinal headache: Prophylaxis and treatment of low-pressure headache syndromes. *Reg Anesth Pain Med* 2007; 32:455–61
3. Luetmer PH, Schwartz KM, Eckel LJ, Hunt CH, Carter RE, Diehn FE: When should I do dynamic CT myelography? Predicting fast spinal CSF leaks in patients with spontaneous intracranial hypotension. *Am J Neuroradiol* 2012; 33:690–4

From the Department of Anesthesiology, Billings Clinic Hospital, Billings, Montana.

Copyright © 2013, the American Society of Anesthesiologists, Inc. Lippincott Williams & Wilkins. *Anesthesiology* 2014; 121:388