

# Case Scenario: Postoperative Brachial Plexopathy Associated with Infraclavicular Brachial Plexus Blockade

## *Localizing Postoperative Nerve Injury*

Michael J. Barrington, Ph.D., M.B.B.S., F.A.N.Z.C.A., Wayne Morrison, A.M., M.D., B.S., F.R.A.C.S., Tom Sutherland, M.B.B.S., M.Med., F.R.A.N.Z.C.R., Valerie S. Tay, M.B.B.S., F.R.A.C.P., James C. Watson, M.D.

**P**OSTOPERATIVE nerve injuries (PNIs) have anesthetic, patient, and surgical contributions and determining the etiology may be challenging when peripheral nerve blockade is used. Evaluating PNI relies on clinical assessment, electrodiagnostic testing, and magnetic resonance imaging (MRI). MRI of peripheral nerves can diagnose external compression or loss of nerve continuity and is increasingly used for evaluation of peripheral nerve disease.<sup>1</sup> Determining the etiology of PNI requires an injury to be definitively localized and whether it is concordant with the peripheral nerve blockade site or distinct from it. We present a case of postoperative brachial plexopathy after microvascular toe segment transfer surgery where continuous infraclavicular blockade was used. The objective of this case scenario is to explore the challenges in precisely localizing PNI and the roles and limitations of electrodiagnostic testing and MRI.

### Case Scenario

Written consent was obtained from this patient to publish this case scenario. A 60-yr-old male patient with American Society of Anesthesiologists physical status III (height, 1.87 m and weight, 110 kg) had microvascular toe segment transfer to reconstruct his right thumb after traumatic amputation 2 yr earlier. Previous reimplantation was unsuccessful despite two surgical revisions. Preoperative comorbidities included neuropathic stump pain, chronic lumbar back pain, cervical spondylosis, Raynaud phenomenon, vitamin B12 deficiency, and depression. He had a history of neck pain and

paresthesias in the fourth and fifth fingers, cigarette smoking (40 packet-years), and long-term alcohol abuse. Preoperative medications included morphine sulphate 10 to 30 mg twice daily, amitriptyline 100 mg nightly, and methotrexate 10 mg weekly. Surgical goals were to restore thumb function by improving allodynia *via* resection of digital nerve neuromas, restoring thumb length, and facilitating the redistribution of the unsatisfied axons of the neuromas into the digital nerves of the toe.

Before induction of general anesthesia, with the patient sedated (midazolam, 2 mg and fentanyl, 50 µg), ultrasound-guided sciatic nerve blockade was performed for the toe harvest with a 20-gauge, 150-mm needle (Stimuplex®; B.Braun, Bethlehem, PA) using 15 ml of ropivacaine 0.75%. Infraclavicular brachial plexus blockade was then established with ultrasound guidance using 25 ml of ropivacaine 0.75% (with no adjuvants) through an 18-gauge, 100-mm Tuohy needle (Contiplex®, B.Braun). Perineural spread of local anesthetic was confirmed involving the lateral and posterior cords and there were no reports of pain on injection or during needle or catheter placement. A 20-gauge catheter was left *in situ* for continuous postoperative perineural blockade. The duration of surgery was 6.5 h with the arm abducted to 90 degrees. There were two periods of tourniquet compression of total duration 33 min, pressure not recorded.

In the postanesthesia care unit, there was no surgical-site pain, and a perineural infusion of ropivacaine 0.2% (8 ml/h)

This article is featured in "This Month in Anesthesiology," page 3A.

Submitted for publication October 28, 2013. Accepted for publication February 12, 2014. From the Melbourne Medical School, University of Melbourne; Department of Anaesthesia, St Vincent's Hospital, Melbourne, Australia (M.J.B.); Department of Surgery, University of Melbourne; Department of Health Sciences, Australian Catholic University, Melbourne, Australia (W.M.); Central Melbourne Medical Imaging, St Vincent's Hospital, Melbourne, Australia (T.S.); Department of Neurosciences, St Vincent's Hospital, Melbourne, Australia (V.S.T.); and Department of Neurology, Mayo Clinic, Rochester, Minnesota (J.C.W.)

Copyright © 2014, the American Society of Anesthesiologists, Inc. Lippincott Williams & Wilkins. Anesthesiology 2014; 121:383-7

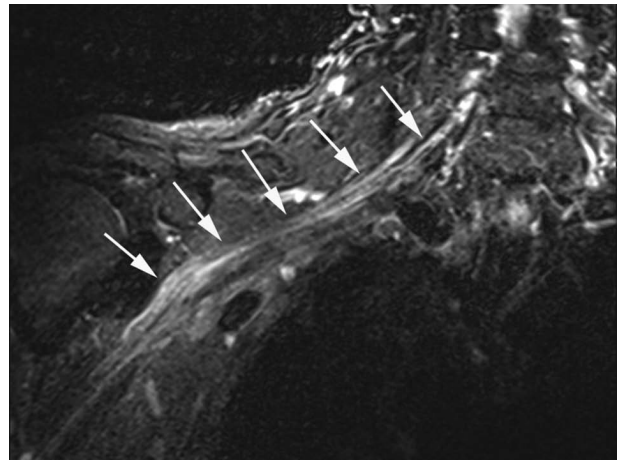
was commenced providing effective analgesia. There was an upper limb motor block on the day of surgery but not thereafter during the period of perineural blockade. On postoperative day 5, the local anesthetic infusion was discontinued and as the regional analgesia receded, the patient began to complain of severe pain originating in the operative side shoulder and radiating to the medial border of the forearm and fourth and fifth fingers. At this point, pain limited upper extremity movement and its assessment. However, by postoperative day 7, it was evident that there was operative side weakness involving elbow (flexion/extension) and wrist (extension). Objective neurological assessment was limited by severe pain. There were sensory deficits in the radial and medial antebrachial nerve territories and the lateral aspect of the entire upper extremity. There were paresthesias in fingertips bilaterally and hypersensitivity to touch in the fingers.

Two weeks postoperatively, there had been no improvement or evolution in signs or symptoms. There was persisting paresthesia and allodynia in the operative arm, forearm, and hand, and the patient described his upper extremity as “3/4 dead.” Three weeks postoperatively, electrodiagnostic tests demonstrated a recent onset brachial plexopathy interpreted as most severely affecting the upper trunk. On the operative side, there were loss of motor units in triceps, deltoid, and biceps, active denervation in deltoid and biceps, minor active denervation in the first dorsal interosseous muscle, a severe motor and sensory ulnar neuropathy that was difficult to localize, and mild carpal tunnel syndrome. There were no abnormalities involving the supraspinatus muscle. Contralateral upper extremity nerve conduction studies were normal. The severe unilateral pain prompted an investigation for cervical spine or shoulder pathology. MRI of the cervical spine, Siemens MAGNETOM® Avanto (Siemens Healthcare USA, Malvern, PA), demonstrated moderate-severity multilevel operative side spondylotic changes, but no significant root impingement or suggestion of nerve root avulsion. MRI of the shoulder revealed adhesive capsulitis and supraspinatus tendonitis. Six weeks postoperatively, an MRI of the brachial plexus revealed a high signal intensity extending diffusely from the trunks to the branches (fig. 1). There was no muscle edema, atrophy, nerve root avulsion, or extrinsic compression (fig. 2). Cervical medial branch blocks as well as subacromial bursa and glenohumeral joint injections were ineffective. Surgical exploration of the brachial plexus 4 months postoperatively revealed no overt pathological changes.

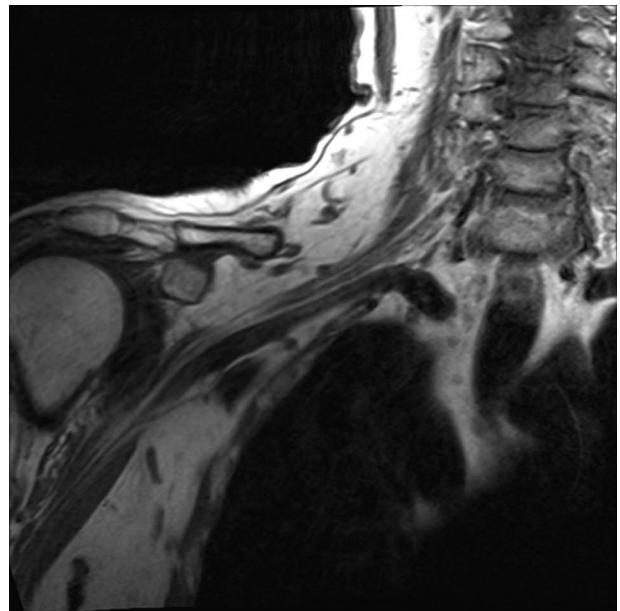
## Discussion

### *What Was the Likely Mechanism of Injury?*

Even though not definitive, a likely etiology of this patient's postoperative neurologic deficit was the infraclavicular brachial plexus block performed at the level of the cords. Preexisting neural injury was highlighted by a preoperative history of paresthesias and pain suggesting a C8 radiculopathy or ulnar neuropathy. This preexisting neurogenic process would



**Fig. 1.** Magnetic resonance imaging of the brachial plexus in coronal plane using Short Tau Inversion Recovery and fat-suppressed T2-weighted imaging demonstrating a long segment of elevated signal intensity throughout the brachial plexus (arrows) extending from the trunks to the branches. Images acquired on a 1.5-Tesla Siemens MAGNETOM® Avanto (Siemens Healthcare USA, Malvern, PA) with surface coil using times to echo and repetition of 65 and 4,820 ms, respectively.



**Fig. 2.** Magnetic resonance imaging of the brachial plexus in coronal plane using T1-weighted imaging. There is no muscle edema, atrophy, nerve root avulsion, or extrinsic compressing mass or hematoma. Images acquired on a 1.5-Tesla Siemens MAGNETOM® Avanto (Siemens Healthcare USA, Malvern, PA) with surface coil using times to echo and repetition of 11 and 495 ms, respectively.

have meant that there was limited neurogenic reserve in this region, potentially worsened by vitamin B12 deficiency and alcohol abuse and that a secondary injury would be more likely to precipitate further neurologic impairment. This scenario is often described as the double-crush theory where an

insult or pathology at one point on the nerve, even if relatively minor, may potentiate further injury elsewhere along the same nerve.<sup>2</sup> An additional preoperative differential diagnosis was Pancoast tumor involving the brachial plexus normally diagnosed on chest radiography (not present in this case). In a volunteer study, complete abolition of ulnar nerve somatosensory potentials occurred after 15 to 30 min of tourniquet application. These changes were due to nerve ischemia and were reversible with tourniquet deflation.<sup>3</sup> Therefore, neural compromise may have been aggravated by tourniquet application for 33 min.

Postoperative brachial plexopathy due to intraoperative positioning<sup>4,5</sup> was first recognized in the late 1800s.<sup>6</sup> The brachial plexus is susceptible to stretch, compression, or ischemia between the clavicle and the first rib, adjacent to the coracoid process, at the humeral head, and posterior to the scalenus anterior over the first rib.<sup>4</sup> This patient with likely preoperative neural compromise had his upper extremity abducted to 90 degrees and this is known to have a risk of a positional plexopathy. Further mechanical loading of the peripheral nervous system occurs with wrist and terminal elbow extension.<sup>7</sup> A positioning-related brachial plexopathy is more likely to involve the upper trunks; however, a panplexopathy can also occur.<sup>4,5</sup> The incidence of brachial plexus injuries due to malposition during surgery with general anesthesia has been estimated to occur with an incidence rate of 0.02%,<sup>4</sup> which is the same as the reported incidence rate of long-term neurological deficits related to peripheral nerve blockade.<sup>8</sup>

#### ***Were the Electrodiagnostic Studies Useful in Localizing the Nerve Injury and Determining Etiology?***

The findings on electromyography were indicative of a diffuse but multifocal process. Electromyography changes involving deltoid, biceps, and triceps were interpreted to indicate involvement of upper and middle trunks; however, lateral and posterior cord involvement could alternatively explain these changes and are consistent with injury from the infraclavicular block. The supraspinatus innervation runs through the upper trunk but not the posterior or lateral cord; therefore, the normal supraspinatus electromyography was suggestive of lateral and posterior cord pathology. However, nerve injury is often partial, involving fascicles to certain muscles while sparing others. Therefore, the normal supraspinatus electromyography does not absolutely exclude upper trunk-level pathology, although it is less likely.

Localizing the PNI was confounded by electromyographic changes in the first dorsal interosseous muscle and nerve conduction studies that suggested a severe ulnar neuropathy. This was likely preexisting because of the patient history and lack of cervical spine changes to suggest an alternative C8 radiculopathy. The remaining electromyographic changes suggested a primarily posterior/lateral cord or less likely upper/middle trunk plexopathy with the former potentially implicating the nerve block and/or infusion

as the cause of the PNI. If the ulnar neuropathy was not old and part of the perioperative injury, it suggested a more diffuse and multifocal process. A careful clinical review of preexisting neurologic disorders is critical in interpreting postoperative neurologic deficits and electrophysiologic findings because old neurogenic injuries remain evident on electrodiagnostic testing and make new injuries look artificially more diffuse or multifocal. A preblock, preoperative examination, or electrodiagnostic evaluation would have likely clarified the previous history of ulnar neuropathy *versus* C8 radiculopathy and simplified interpretation of the postoperative electromyogram.

Electrodiagnostics are useful in localizing PNI but need to be interpreted within the context of the patient's clinical history, recognizing that selective fascicular injury and preexisting nerve injury may confound the results. Electrodiagnostic studies were useful in this case, confirming a neurogenic process and provided evidence that functional limitations could not be attributed to musculoskeletal disease alone. Importantly, electrodiagnostics localized the problem to the brachial plexus and not to the cervical nerve roots. Electromyography provides information on the severity of the nerve injury (extent of axonal loss), and in cases of severe nerve injury, serial evaluations can be used to assess for early stages of reinnervation and recovery.

When evaluating a patient with PNI, it is important for the anesthesiologist to consider the appropriate time for electrodiagnostic testing. It takes up to 3 weeks from the time of nerve injury for sufficient Wallerian degeneration to cause denervation of a target muscle and therefore electromyography is most definitive in localizing and defining the severity of nerve injury at least 3 weeks after injury.<sup>9</sup> Electromyographic findings in the acute phase (first 3 weeks) are subtle and may be overlooked; however, if performed in this phase, they may be useful in defining preexisting disease so that it may be distinguished from an acute process on subsequent studies. This can be important for determining etiology. For example, in this current case, an acute study done less than 3 weeks from injury or electromyography performed preoperatively may have clarified that the ulnar neuropathy was old and helped with the certainty of localizing the injury on subsequent studies by separating new from old injury.

#### ***What Is the Role of MRI in Determining the Etiology of PNI?***

Magnetic resonance imaging is considered a standard investigation for PNI; however, it may be infrequently used.<sup>10–12</sup> This is in contrast to MRI being increasingly used to diagnose peripheral neuropathies. This is related to improvements in MRI hardware and development of new techniques to improve peripheral nerve visualization.<sup>1</sup> MRI is ideally suited to assess the brachial plexus with the plexus seen as isointense structures on non-fat-suppressed T1 acquisitions.<sup>13,14</sup> Multiplanar acquisitions allow exclusion of extrinsic compressive pathologies. Fat-suppressed fluid-sensitive sequences such as

Short Tau Inversion Recovery determine the signal intensity of neural structures. Using these sequences, abnormal nerves are hyperintense on T2-weighted images and may demonstrate enhancement. MRI findings did not accurately localize site of injury but indicated a diffuse injury process. However, MRI confirmed involvement in the region the block was performed (although more widespread than expected from infraclavicular plexus injury), whereas electromyography was not able to discern that definitively.

### Knowledge Gap and Recommendations

Anesthesiologists need to be aware of limitations of electrodiagnostic studies and MRI in localizing PNI. This is not to say these ancillary tests are not important. In this case scenario, the investigations definitively confirmed a process distal to the dorsal root ganglion in the peripheral nerve and that this PNI was not a nerve root disorder or a musculoskeletal process. These findings were important because they directed treatment options for this patient.

When electromyographic changes become diffuse, sorting out multiple trunks from multiple cords or multifocal peripheral nerves becomes challenging and imperfect. Furthermore, the presence of residual electrodiagnostic changes from old, unrelated neurogenic processes confounds the ability to localize the injury. An abnormal neurologic examination and electromyography performed preoperatively would have confirmed an existing neurogenic process and made the postoperative electromyographic changes easier to interpret. If the ulnar neuropathy was known to be old, the remaining electromyographic findings would have implicated a perioperative etiology (brachial plexus block or upper extremity positioning). If a preoperative evaluation was normal and the postoperative ulnar nerve findings were found to be new, then the electromyographic changes would have implicated a multifocal perioperative etiology, which are often inflammatory immune mediated in nature. One important limitation of this patient's management was that electrodiagnostic studies and MRI were not repeated. Three weeks is the earliest point that axonal loss changes are evident on electromyography. However, any acute or subacute process that is challenging to localize may declare itself with repeat electromyography later in time. Serial studies are useful in looking for the evidence of recovery (subclinical reinnervation preceding clinical improvement).

Magnetic resonance imaging diagnostic capacity is limited because a range of pathological mechanisms may lead to similar MRI changes (increased signal intensity), so imaging abnormalities are nonspecific. In this case, the increased signal intensity was present diffusely throughout the brachial plexus and these features are similar to cases of infective or inflammatory brachial plexopathies<sup>15</sup> and after neural stretch injuries. MRI can provide direct evidence of infiltrating or extrinsic compressive neural pathology; however, its current role in determining the etiology of PNI is uncertain. The limitations of MRI of peripheral nerves after PNI include the unknown

extent of signal intensity changes and variables affecting it. For example, if the mechanism of this plexopathy was stretch or inflammation primarily affecting the upper trunks, the extent and time course over which MRI signal intensity changes would extend distally with Wallerian degeneration are unknown. Theoretically, these changes may falsely localize the PNI to a distal section of the plexus whereas had the increased signal intensity been confined to the lateral and posterior cords, then a diagnosis of block-related injury would be more likely and had the changes been limited to the upper trunk then a positioning injury would have been more plausible. If signal intensity increase is a function of Wallerian degeneration, axonal loss, and secondary inflammation, one may speculate as to whether MRI performed more acutely would be better at localizing the site of injury. Currently this is unknown. Images acquired on 1.5-Tesla scanners are limited by poor spatial resolution, susceptibility to artifacts, long acquisition times, and varied interpretation. However, 3-Tesla scanners may acquire high-resolution, high-contrast images in shorter imaging times and may potentially improve the overall usage of MRI in determining the etiology of PNIs. Currently for PNI, MRI has a postoperative role identifying (1) peripheral or neuraxial extrinsic compression; (2) loss of nerve continuity; (3) objective evidence of peripheral nerve involvement; and (4) nonneurologic causes (primary musculoskeletal etiology).

There has been increasing recognition that some PNIs are inflammatory in etiology.<sup>16–18</sup> This is important medicolegally as the pathogenesis is not anesthesia or surgical related, but instead secondary to a nonspecific inflammatory response targeting the peripheral nerve in the context of surgery. Postoperative inflammatory neuropathies or plexopathies have often been recognized in anatomically distinct locations from the surgery (*i.e.*, another limb) but can occur within the operative limb where they can be difficult to discern from typical causes of PNI. Key features to suggest an inflammatory etiology include multifocal or difficult to localize postoperative deficit, severe pain disproportionate to the expected perioperative course, progressive deficits, or deficits or pain developing after a period of documented return to neurologic baseline or lack of pain (not explained by postoperative regional anesthesia). In these scenarios, a postoperative inflammatory neuropathy should be considered. Corticosteroid therapy in these cases is unproven as the postoperative inflammatory neuropathy spectrum has yet to be fully elucidated but is rational and commonly practiced. In this case, pain was present from the time of discontinuation of the infraclavicular catheter, and objective findings on electromyography were localized when the ulnar nerve changes were recognized as preexisting. Idiopathic brachial plexopathy (Parsonage Turner Syndrome) is one form of an inflammatory brachial plexopathy seen in the postoperative setting, and in 70% of cases, there is clinical or electrophysiologic evidence of dysfunction of the suprascapular, long thoracic, or anterior interosseous nerves. Only the suprascapular nerve was assessed electrophysiologically in



this case, but the other nerves were not involved clinically. Finally, the patient had no response to corticosteroids, which may have an effect on inflammatory neuropathies. Overall, it is unlikely that this case represented a postoperative inflammatory plexopathy or that fascicular nerve biopsy or further steroid treatment would be of high yield.

In this case scenario, the challenges in precisely localizing the site of injury to determine the etiology of PNI are illustrated by electromyographic abnormalities and MRI imaging characteristics that were not definitive in localizing the nerve injury. In particular, the presence of a proximal brachial plexopathy superimposed on an old neurogenic process made interpretation challenging. However, electromyography and MRI are important investigations in cases of PNI to confirm a nerve injury and define its extent and severity. The timing of electromyography is important, and sequential studies may be required for diagnosis. The patient's preoperative neural compromise potentially contributed to the outcome and confounded the ability to definitively localize the postoperative nerve injury on electromyography. The postoperative brachial plexopathy likely resulted from the brachial plexus block, the intraoperative upper extremity positioning, or both.

### Acknowledgments

Support was provided solely from institutional and/or departmental sources.

### Competing Interests

The authors declare no competing interests.

### Correspondence

Address correspondence to Dr. Barrington: Department of Anaesthesia, St. Vincent's Hospital, Melbourne, PO Box 2900, Fitzroy, Victoria 3065, Australia. michaelbarrington84@gmail.com. Information on purchasing reprints may be found at [www.anesthesiology.org](http://www.anesthesiology.org) or on the masthead page at the beginning of this issue. *ANESTHESIOLOGY*'s articles are made freely accessible to all readers, for personal use only, 6 months from the cover date of the issue.

### References

1. Chhabra A, Andreisek G, Soldatos T, Wang KC, Flammang AJ, Belzberg AJ, Carrino JA: MR neurography: Past, present, and future. *AJR Am J Roentgenol* 2011; 197:583–91
2. Upton AR, McComas AJ: The double crush in nerve entrapment syndromes. *Lancet* 1973; 2:359–62
3. Benzon HT, Toleikis JR, Meagher LL, Shapiro BA, Ts'ao CH, Avram MJ: Changes in venous blood lactate, venous blood gases, and somatosensory evoked potentials after tourniquet application. *ANESTHESIOLOGY* 1988; 69:677–82
4. Winfree CJ, Kline DG: Intraoperative positioning nerve injuries. *Surg Neurol* 2005; 63:5–18; discussion 18
5. Barner KC, Landau ME, Campbell WW: A review of perioperative nerve injury to the upper extremities. *J Clin Neuromuscul Dis* 2003; 4:117–23
6. Garrigues HJ: Anesthesia paralysis. *Am J Med Sci* 1897; 113:81–9
7. Coppieters MW, Van de Velde M, Stappaerts KH: Positioning in anesthesiology: Toward a better understanding of stretch-induced perioperative neuropathies. *ANESTHESIOLOGY* 2002; 97:75–81
8. Barrington MJ, Watts SA, Gledhill SR, Thomas RD, Said SA, Snyder GL, Tay VS, Jamrozik K: Preliminary results of the Australasian Regional Anaesthesia Collaboration: A prospective audit of more than 7000 peripheral nerve and plexus blocks for neurologic and other complications. *Reg Anesth Pain Med* 2009; 34:534–41
9. Aminoff MJ: Electrophysiologic testing for the diagnosis of peripheral nerve injuries. *ANESTHESIOLOGY* 2004; 100:1298–303
10. Koff MD, Cohen JA, McIntyre JJ, Carr CF, Sites BD: Severe brachial plexopathy after an ultrasound-guided single-injection nerve block for total shoulder arthroplasty in a patient with multiple sclerosis. *ANESTHESIOLOGY* 2008; 108:325–8
11. Reiss W, Kurapati S, Shariat A, Hadzic A: Nerve injury complicating ultrasound/electrostimulation-guided supraclavicular brachial plexus block. *Reg Anesth Pain Med* 2010; 35:400–1
12. Cohen JM, Gray AT: Functional deficits after intraneural injection during interscalene block. *Reg Anesth Pain Med* 2010; 35:397–9
13. van Es HW: MRI of the brachial plexus. *Eur Radiol* 2001; 11:325–36
14. Yoshikawa T, Hayashi N, Yamamoto S, Tajiri Y, Yoshioka N, Masumoto T, Mori H, Abe O, Aoki S, Ohtomo K: Brachial plexus injury: Clinical manifestations, conventional imaging findings, and the latest imaging techniques. *Radiographics* 2006; 26(suppl 1):S133–43
15. Sureka J, Cherian RA, Alexander M, Thomas BP: MRI of brachial plexopathies. *Clin Radiol* 2009; 64:208–18
16. van Alfen N, van Engelen BG: The clinical spectrum of neuralgic amyotrophy in 246 cases. *Brain* 2006; 129(Pt 2):438–50
17. Staff NP, Engelstad J, Klein CJ, Amrami KK, Spinner RJ, Dyck PJ, Warner MA, Warner ME, Dyck PJ: Post-surgical inflammatory neuropathy. *Brain* 2010; 133:2866–80
18. Ahn KS, Kopp SL, Watson JC, Scott KP, Trousdale RT, Hebl JR: Postsurgical inflammatory neuropathy. *Reg Anesth Pain Med* 2011; 36:403–5